

# ACUTE TRAUMATIC POSTERIOR SHOULDER INSTABILITY

**Bernhard Jost, MD**

**Department of Orthopedics, University of Zurich, Balgrist, Switzerland**

[bernhard.jost@balgrist.ch](mailto:bernhard.jost@balgrist.ch)



# POSTERIOR SHOULDER DISLOCATION

---

## POSTERIOR DISLOCATION OF THE SHOULDER

HARRISON L. MCLAUGHLIN  
*J Bone Joint Surg Am.* 1952;34:584-590.


---

### INCIDENCE

Posterior dislocations or subluxations of the shoulder are sufficiently uncommon so that their occasional occurrence creates a diagnostic trap for the unwary surgeon.

# ACUTE POSTERIOR DISLOCATION

missed in up to 79%

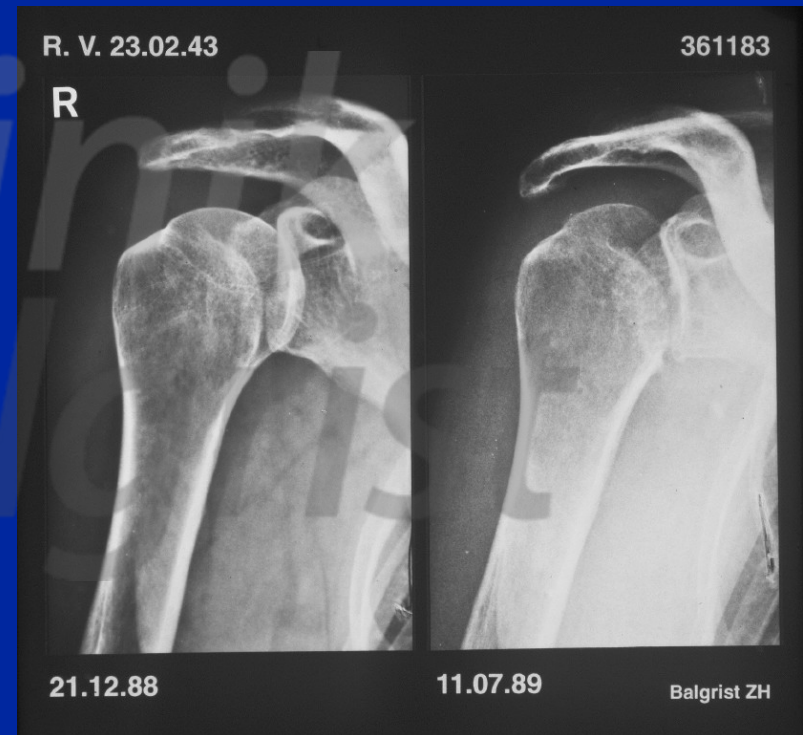

Rockwood & Matsen, The Shoulder, 2009

# ACUTE POSTERIOR DISLOCATION

## IT IS RARE

incidence 2%

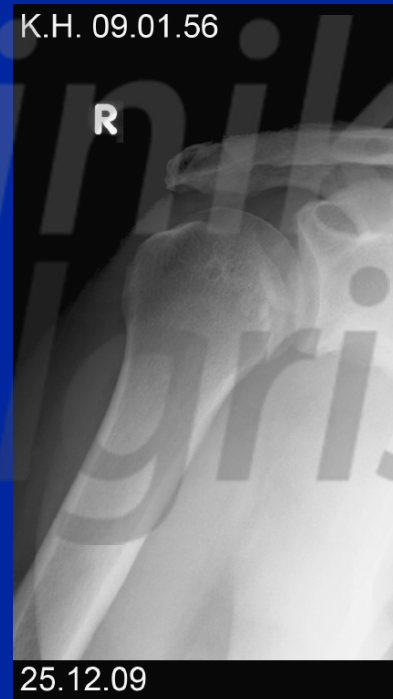

Rockwood & Matsen, The Shoulder, 2009



# ACUTE POSTERIOR DISLOCATION

## IT CAN BE DIFFICULT TO SEE

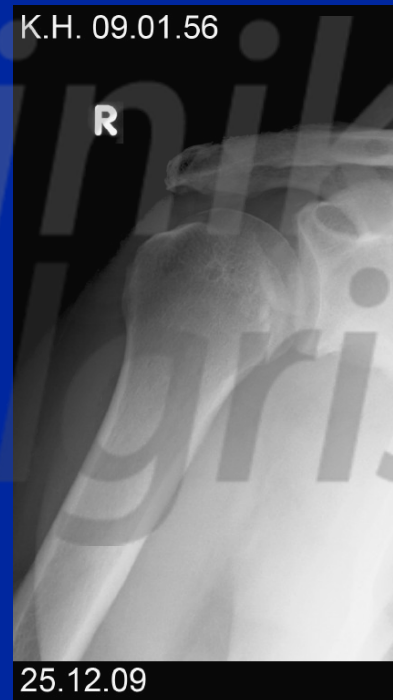

# ACUTE POSTERIOR DISLOCATION IT CAN BE DIFFICULT TO SEE

a shoulder joint is centered  
only

when centered on x-rays in  
at least two different plains

!

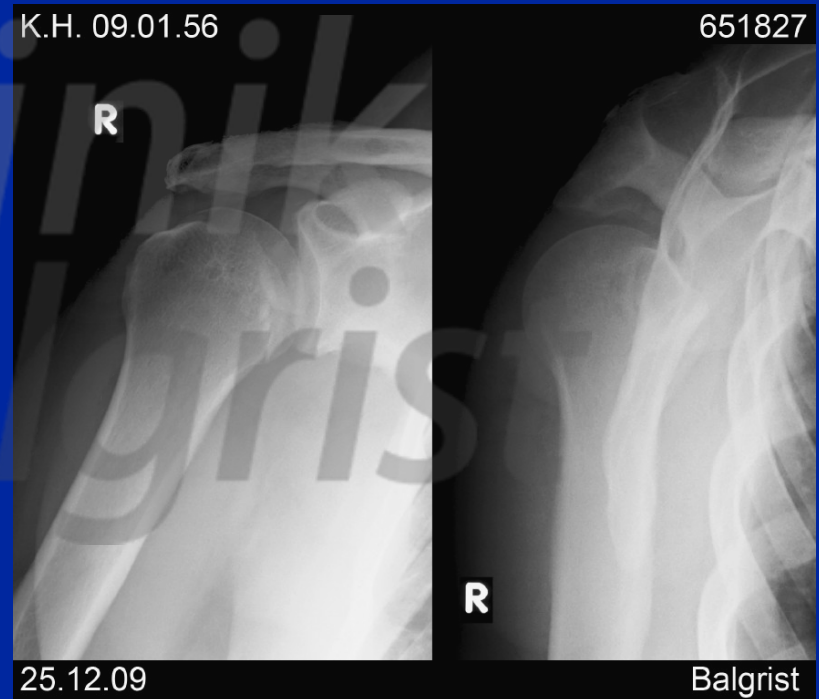


# ACUTE POSTERIOR DISLOCATION IT CAN BE DIFFICULT TO SEE

a shoulder joint is centered  
only

when centered on x-rays in  
at least two different plains

!



# ACUTE POSTERIOR DISLOCATION TRAUMA MECHANISM

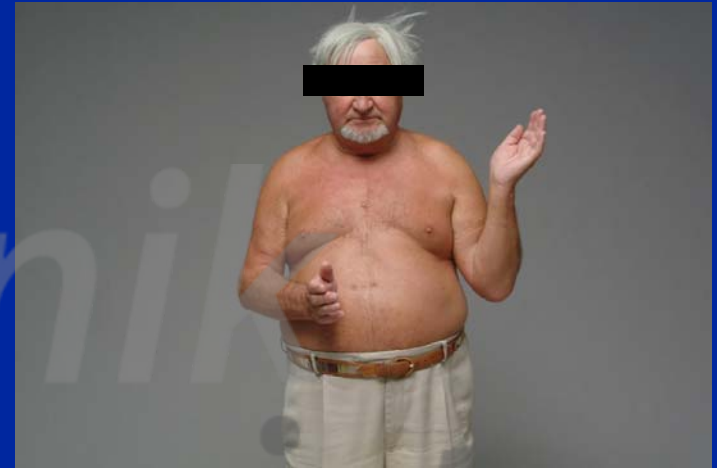- high energy trauma with axial load on flexed and internally rotated arm
  - car accident (steering-wheel)
  - ski accident
- violent muscle contraction
- electrical shock or convulsive seizures





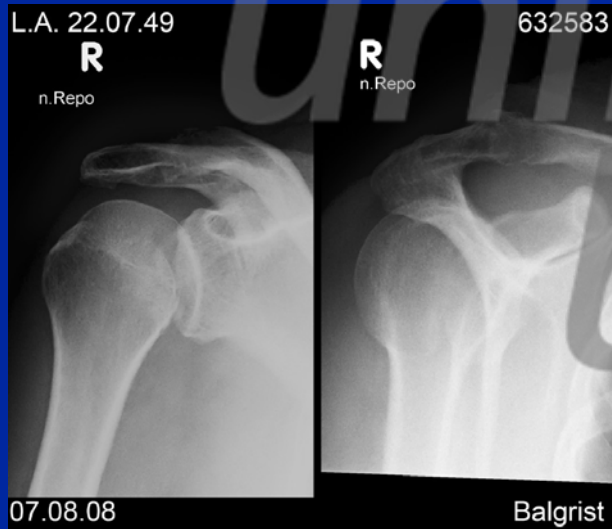
# POSTERIOR SHOULDER DISLOCATION CLINICAL FINDINGS

- limited external rotation  $< 0^\circ$
- limited elevation  $< 90^\circ$
- posterior prominence
- flattening of anterior aspect
- prominence of the coracoid

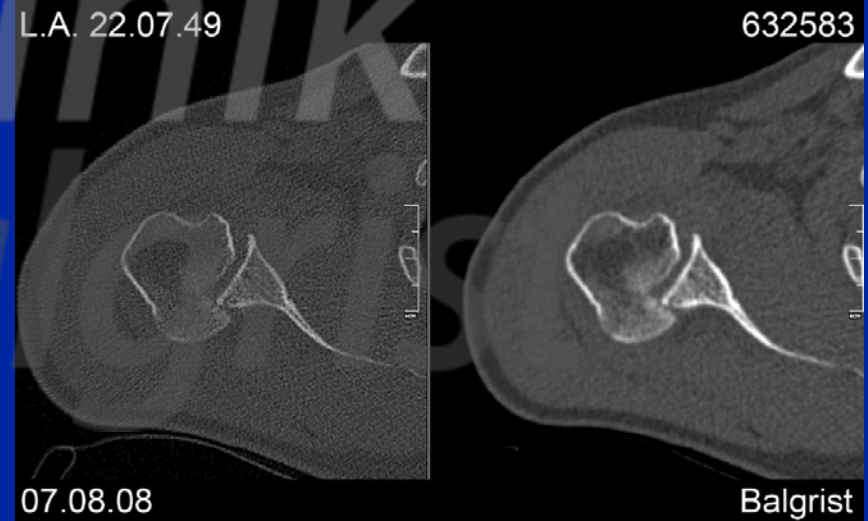


# POSTERIOR SHOULDER DISLOCATION IMAGING

## X-rays



## CT scan (MRI)



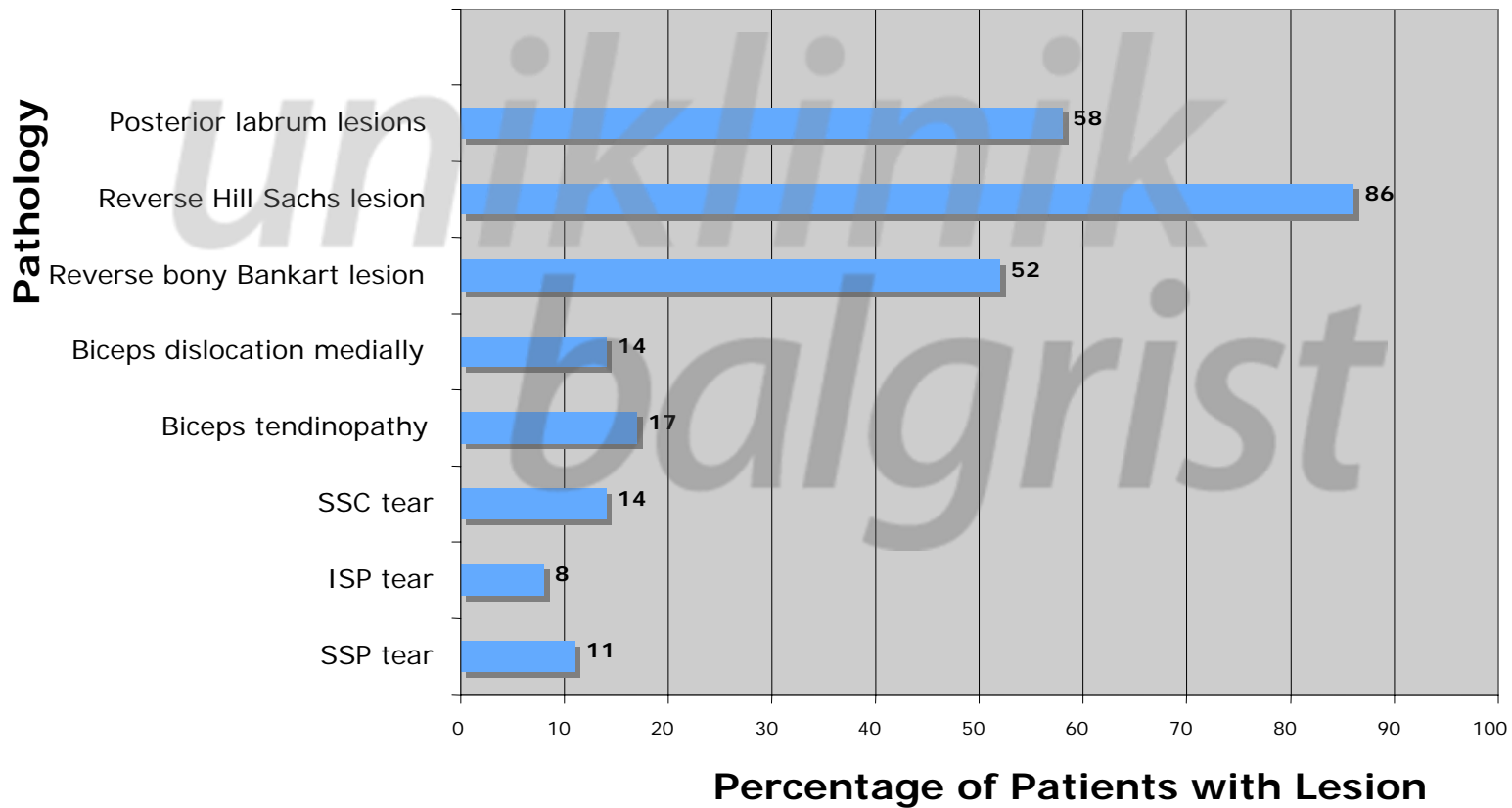
# POSTERIOR SHOULDER DISLOCATION ASSOCIATED LESIONS

- fractures:
  - head (reversed Hill Sachs/ McLaughlin)
  - lesser or / and greater tuberosity
  - (subcapital) humerus
  - glenoid
- soft tissue:
  - posterior labrum
  - biceps tendon
  - rotator cuff tendons



# AFTER FIRST POSTERIOR SHOULDER DISLOCATION

MR Imaging Findings in Acute Traumatic Posterior Shoulder Dislocation



# POSTERIOR SHOULDER DISLOCATION TREATMENT

**there is not so much in the literature**

**Rowe CR, J Bone Joint Surg 64A: 494, 1982**

**Hawkins RJ, J Bone Joint Surg 69A: 9, 1987**

**Blasier RB, Clin Orthop Relat Res 232: 197, 1988**

**Cicak N, J Bone Joint Surg 86B: 324, 2004**

**Kowalski MS, Orthop Clin North Am 39: 519, 2008**

**Rockwood & Matsen, The Shoulder, 2009**

**Diklic ID, J Bone Joint Surg 92B: 71, 2010**



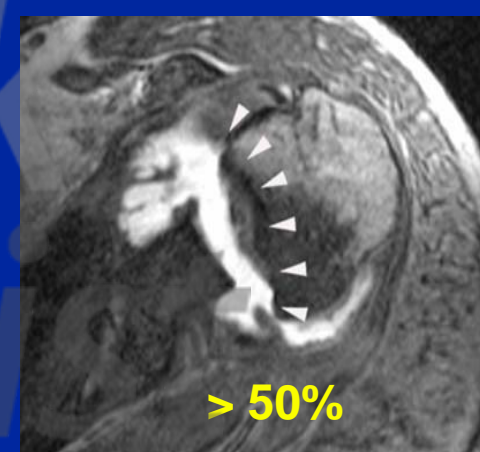
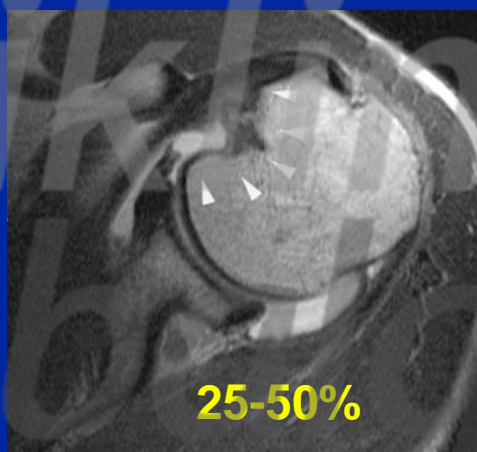
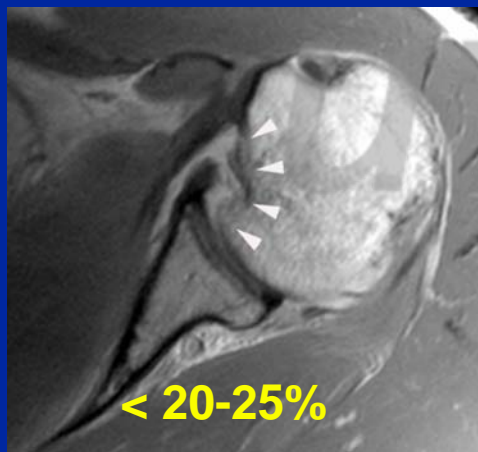
# POSTERIOR SHOULDER DISLOCATION TREATMENT

- self reduction:
  - conservative
  - reconstruction
- closed reduction:
  - conservative
  - open reconstruction
- open reduction and:
  - SSC transfer in defect
  - elevation defect  $\pm$  autograft
  - humeral head allograft
  - (hemi) prosthesis
  - inverse prosthesis
- leave displaced



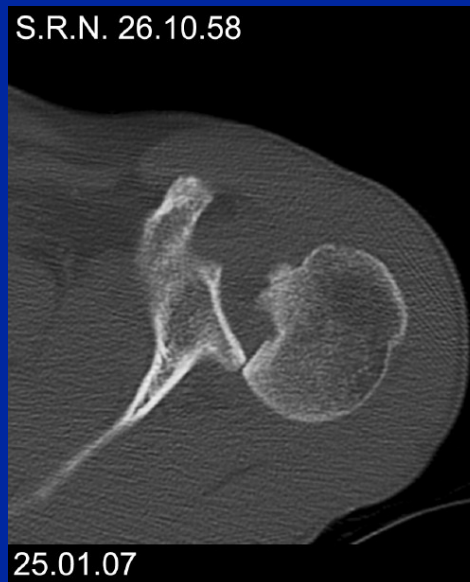
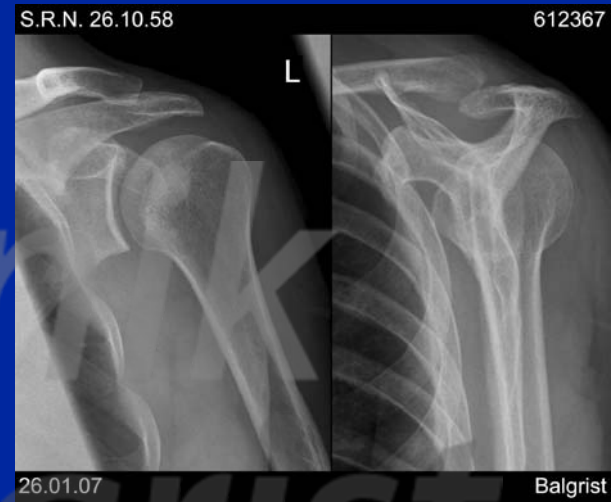
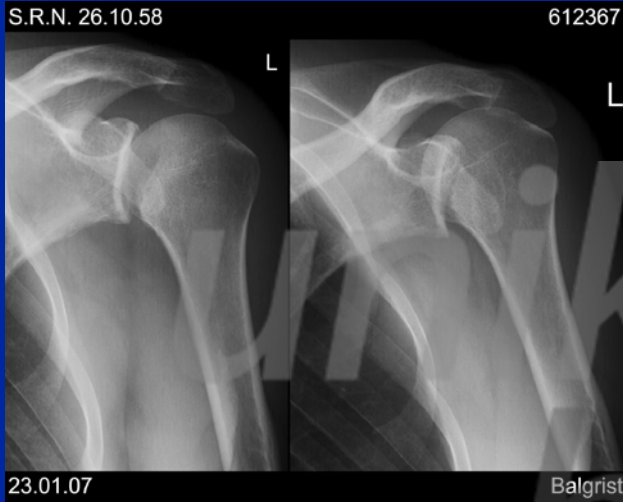# POSTERIOR SHOULDER DISLOCATION ADDITIONAL PARAMETERS

- acute, subacute, chronic
- locked
- associated bony and soft tissue lesions
- age of the patient
- size of head defect



Rockwood & Matsen, The Shoulder, 2009  
Diklic ID, J Bone Joint Surg 92B: 71, 2010

# POSTERIOR SHOULDER DISLOCATION CLOSED REDUCTION, CONSERVATIVE



uniklinik  
balgrist



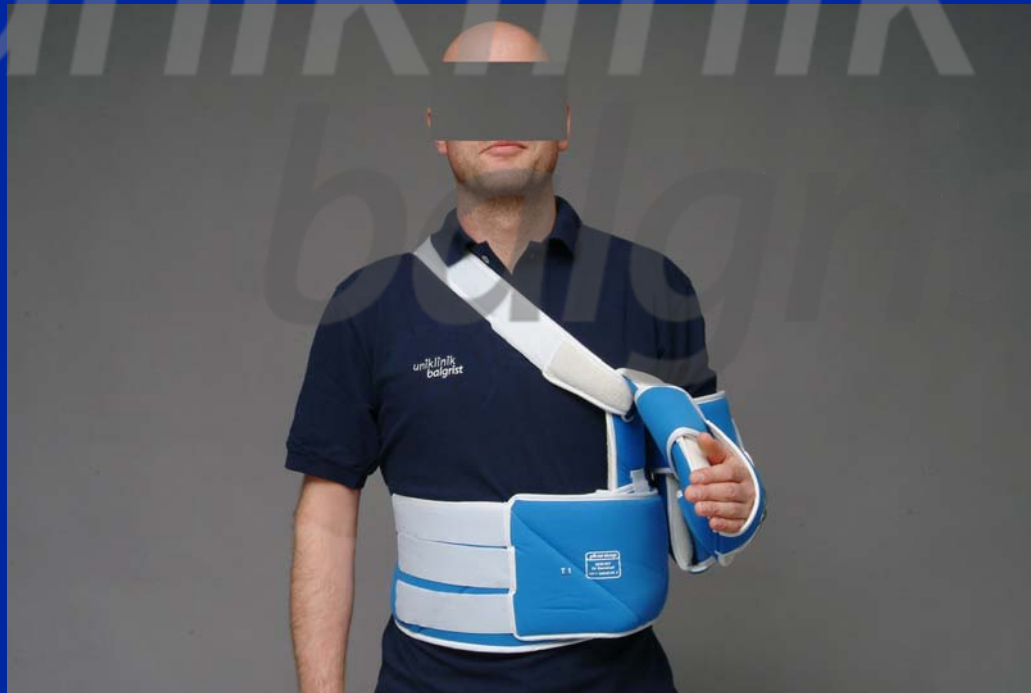# AFTER REDUCTION / POSTOPERATIVE

brace in ADD and NR

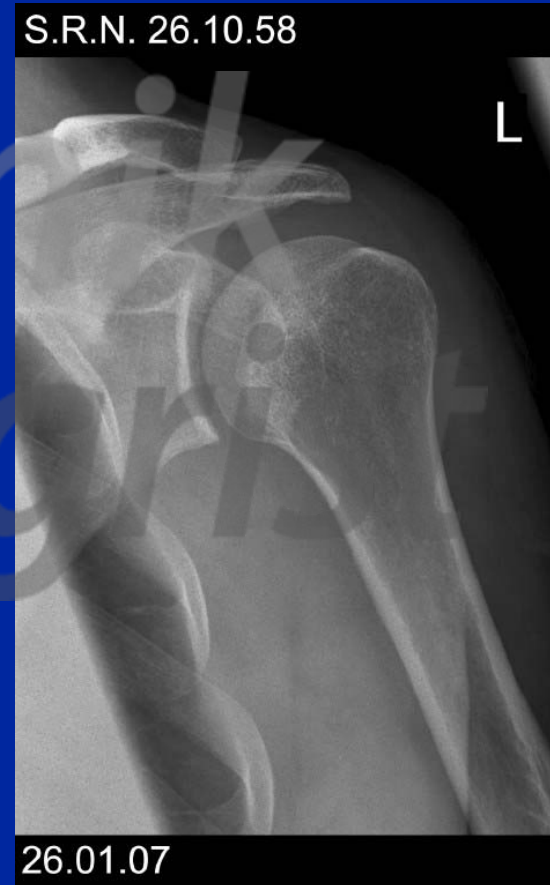
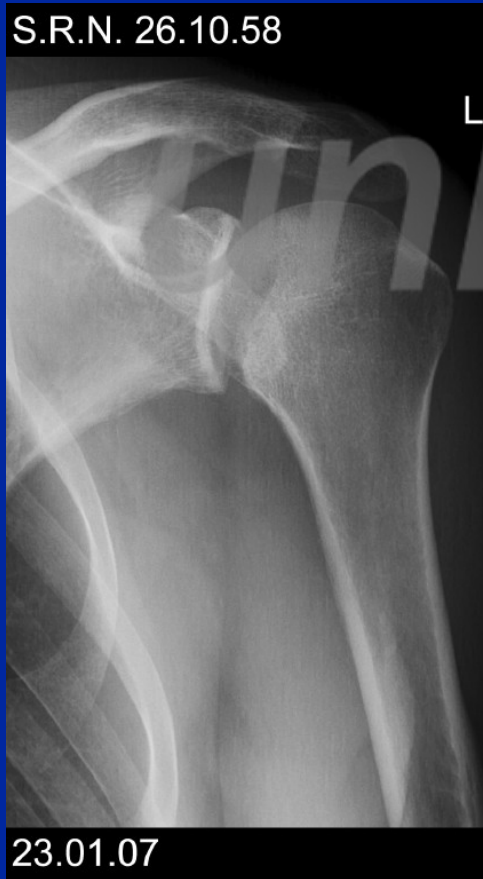
"Grüezi-Schiene"

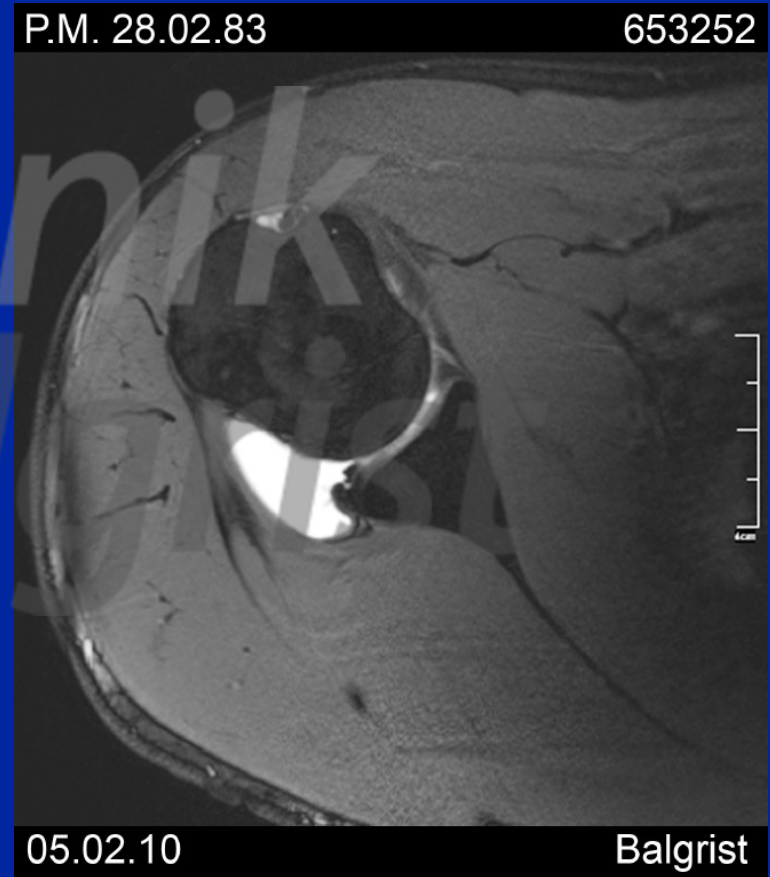
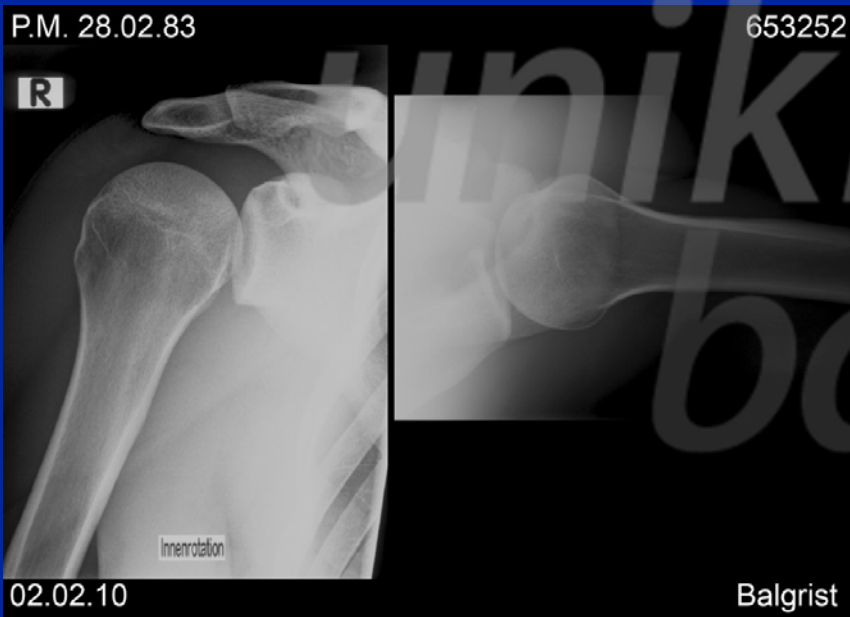(3 to) 6 weeks



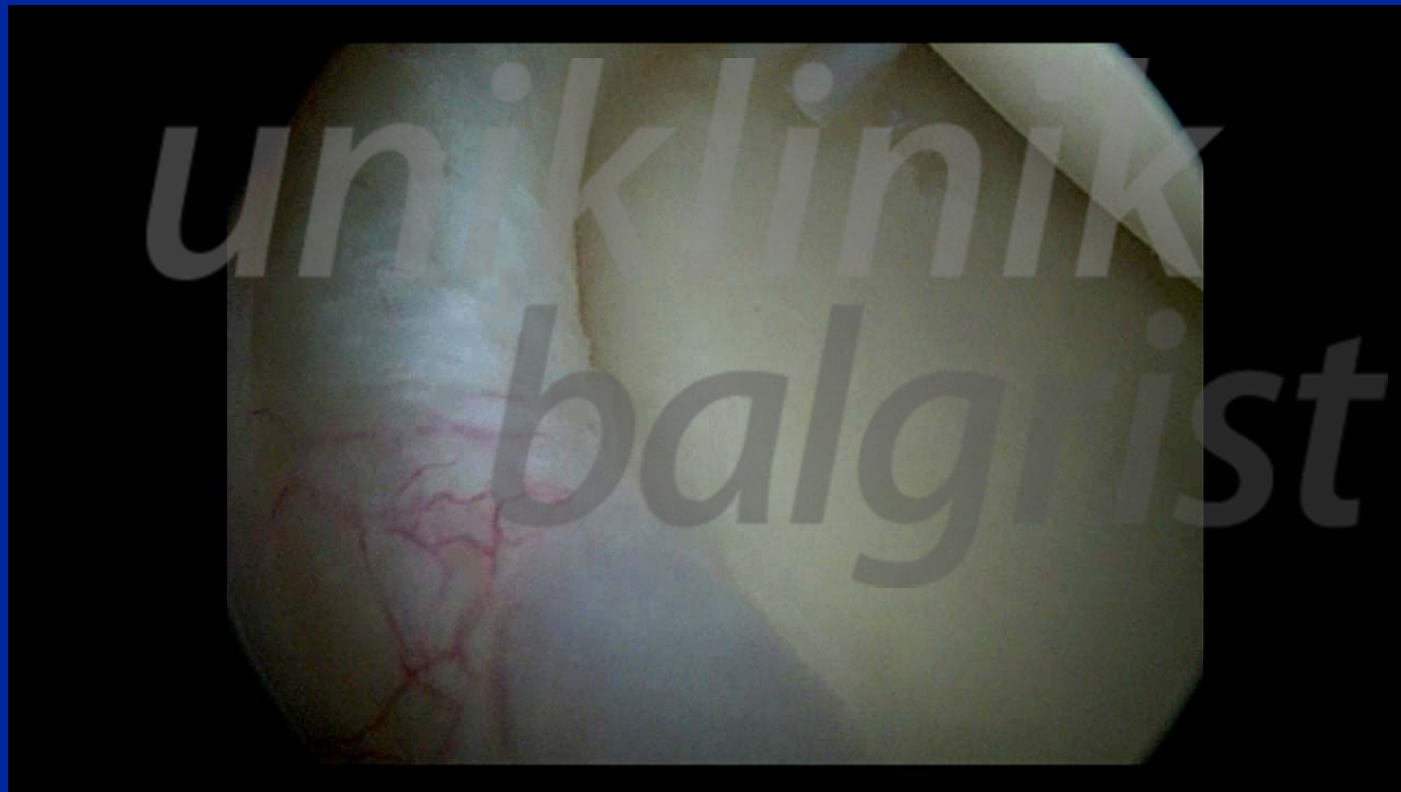
# AGAIN LOOK AT THE X-RAY !



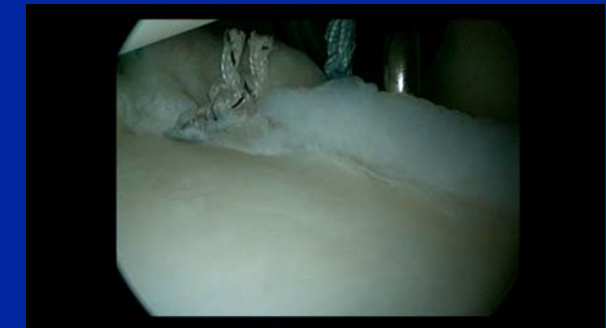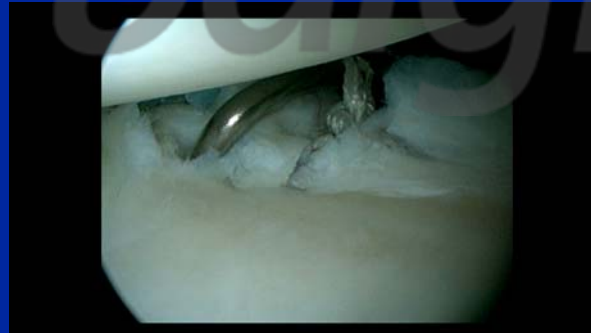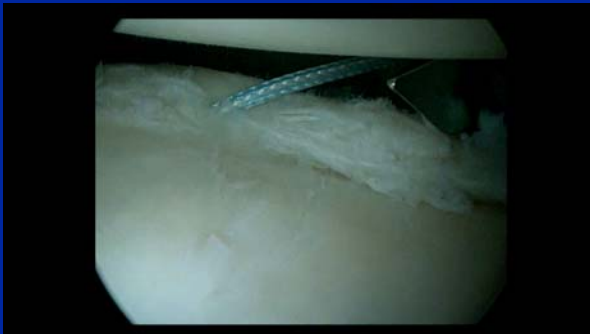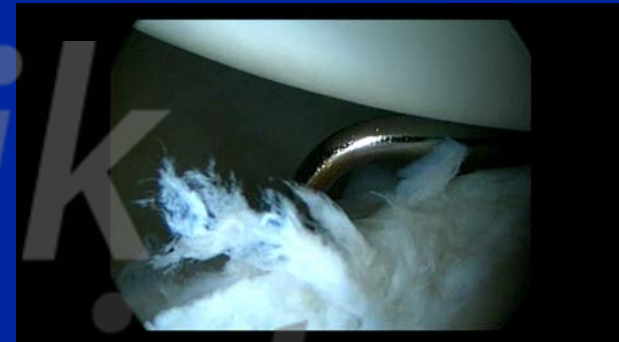# POSTERIOR SHOULDER DISLOCATION LABRUM TEAR, INSTABILITY



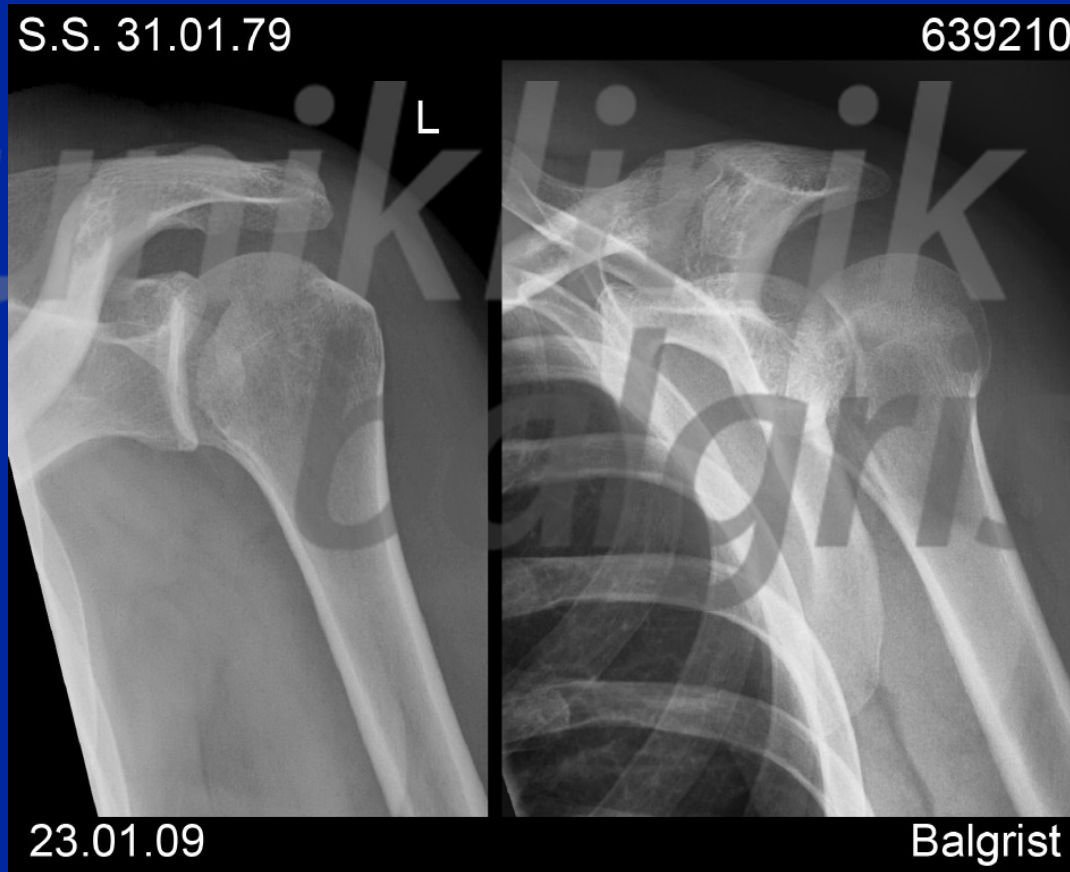# POSTERIOR SHOULDER DISLOCATION LABRUM TEAR



# POSTERIOR SHOULDER DISLOCATION ARTHROSCOPIC REPAIR

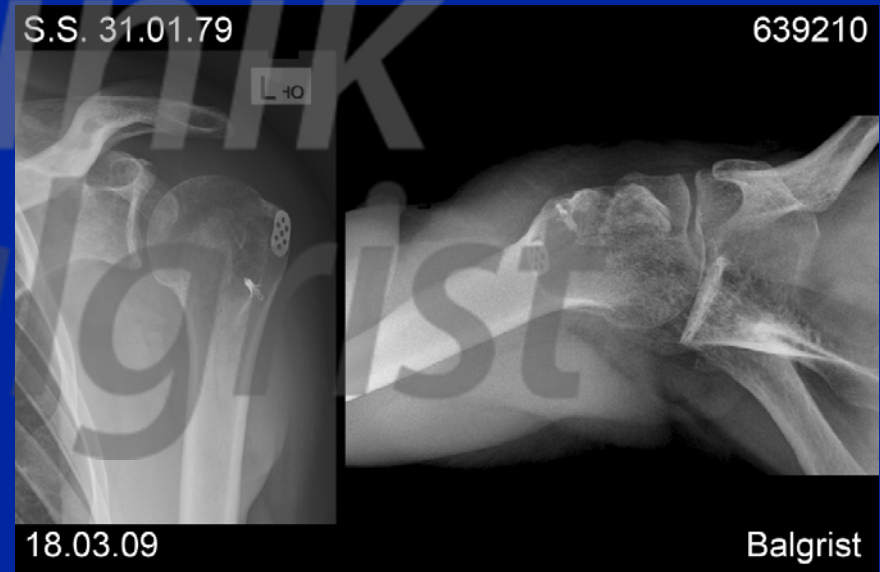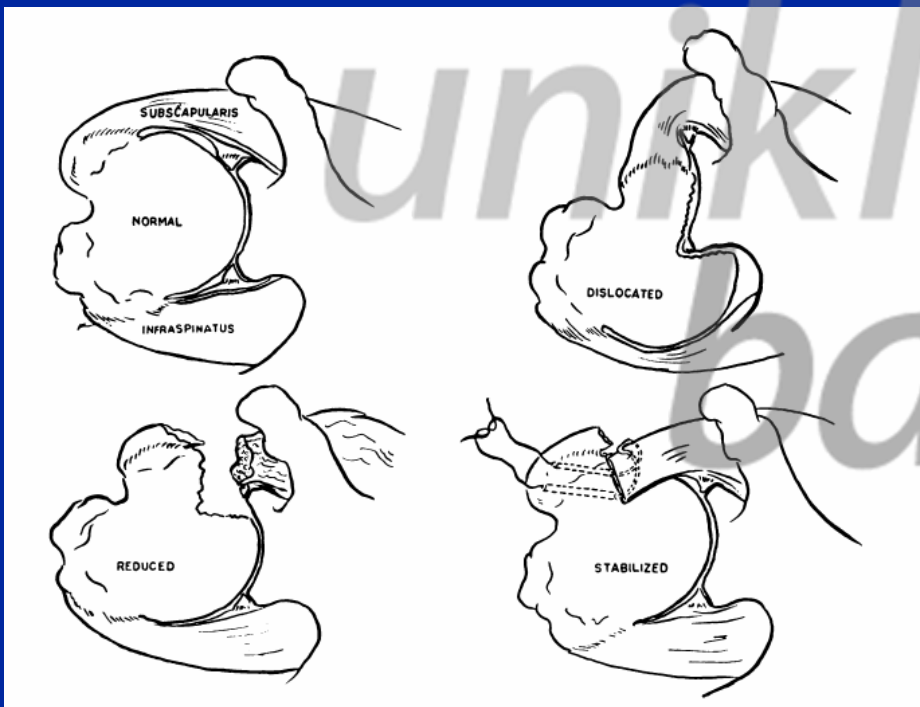


# POSTERIOR SHOULDER DISLOCATION MISSED, OPEN REDUCTION

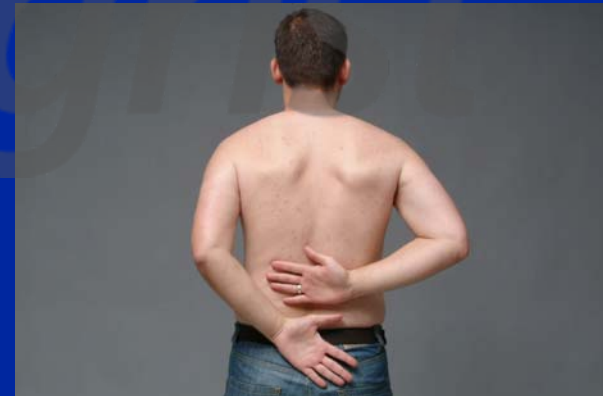
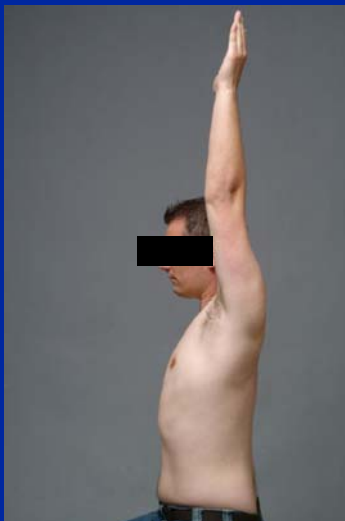
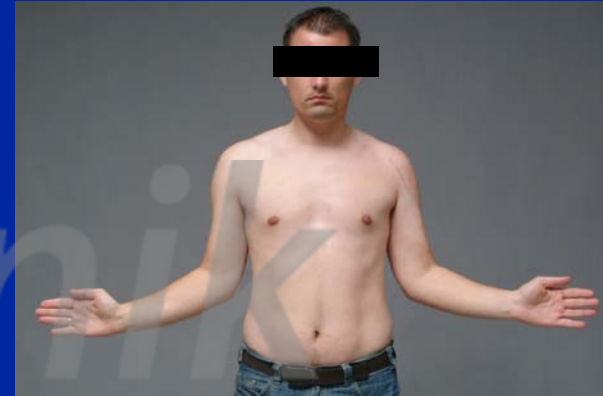
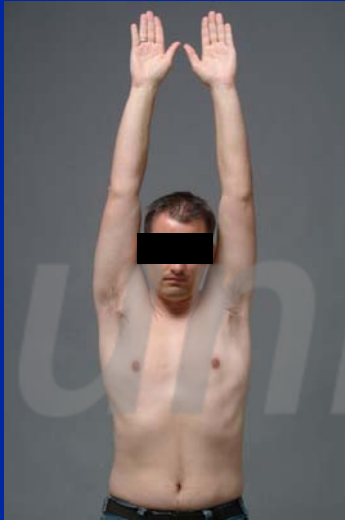
# POSTERIOR SHOULDER DISLOCATION "MCLAUGHLIN" TYPE

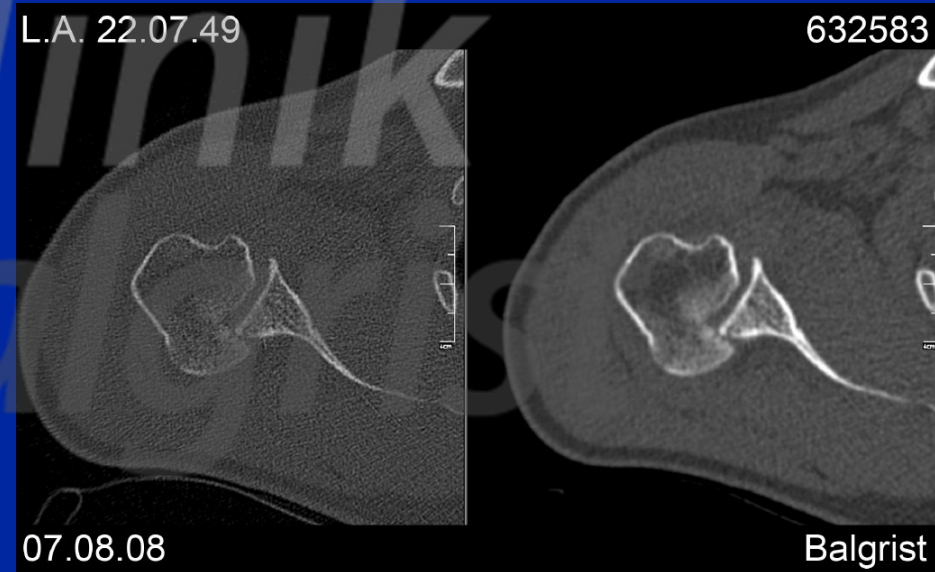
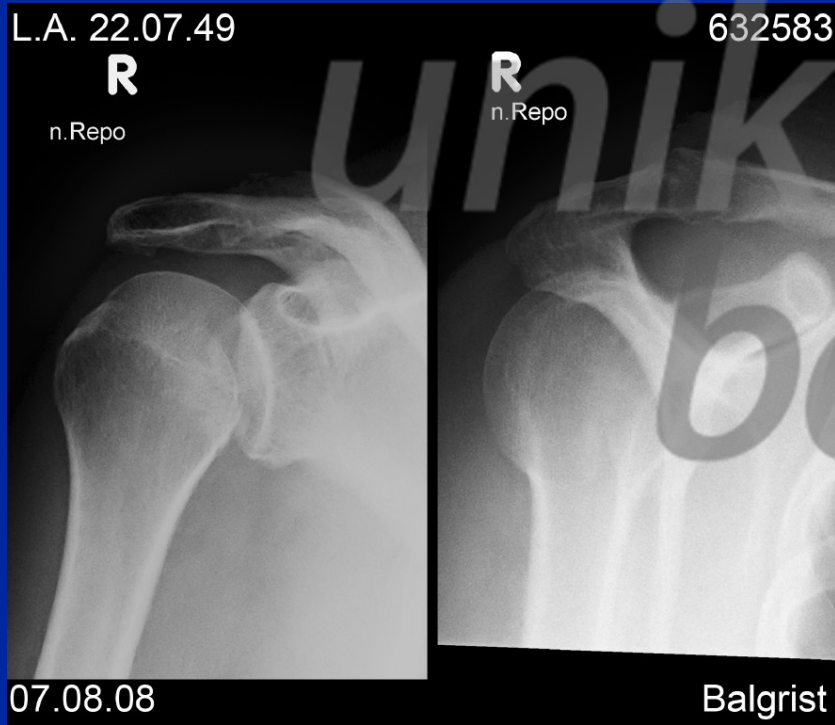

# POSTERIOR SHOULDER DISLOCATION 4 MONTHS POSTOP

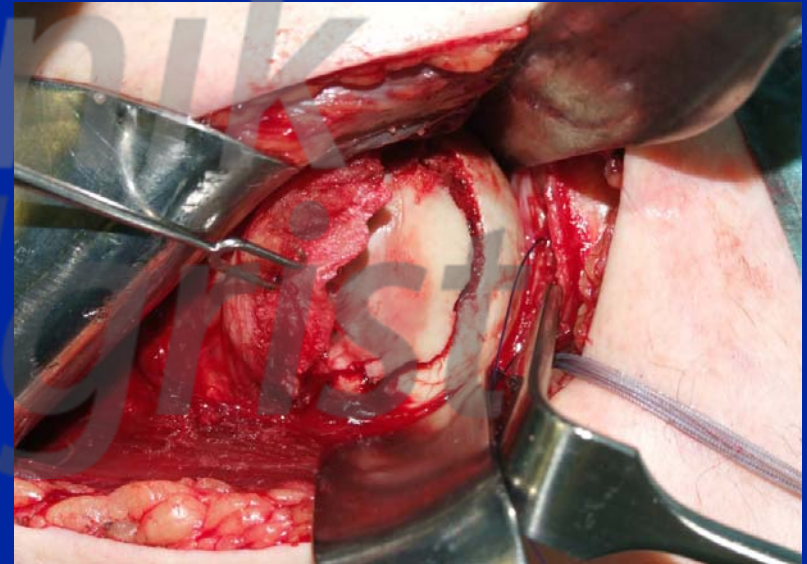
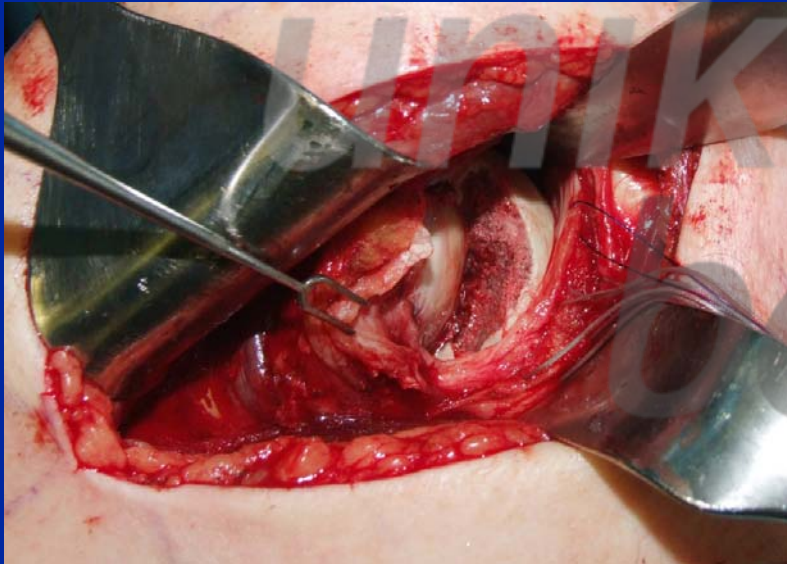




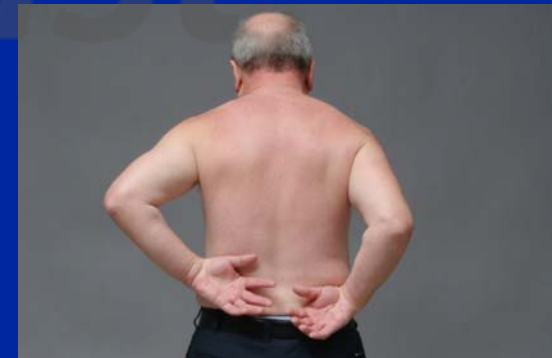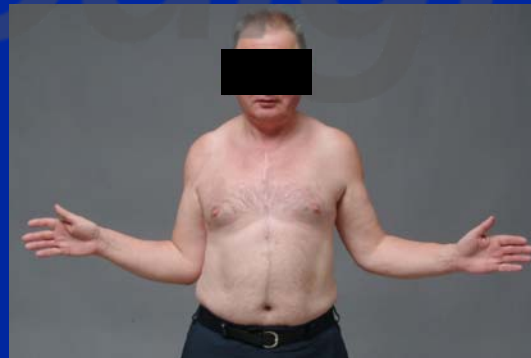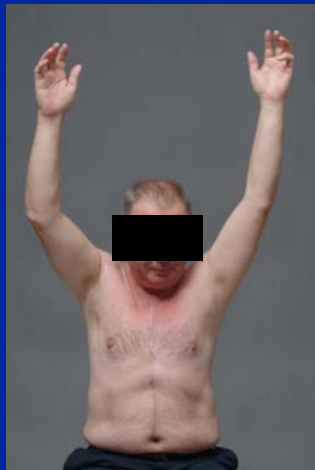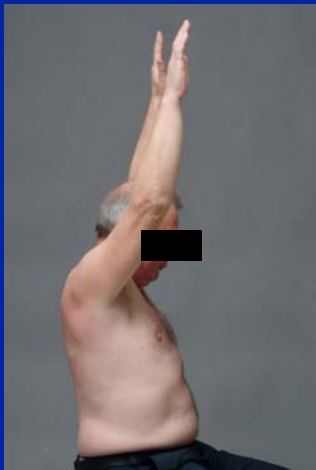
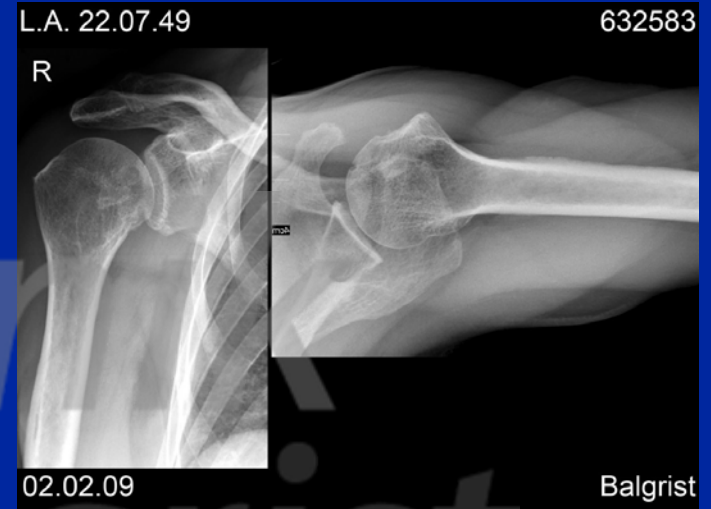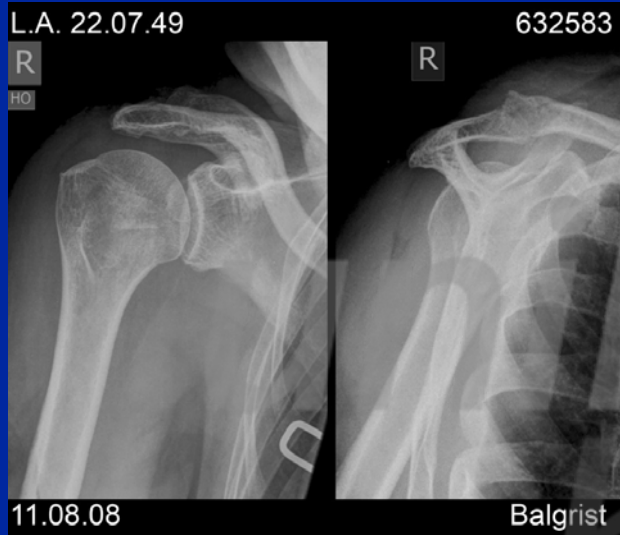
# POSTERIOR SHOULDER DISLOCATION FAILED CLOSED REDUCTION



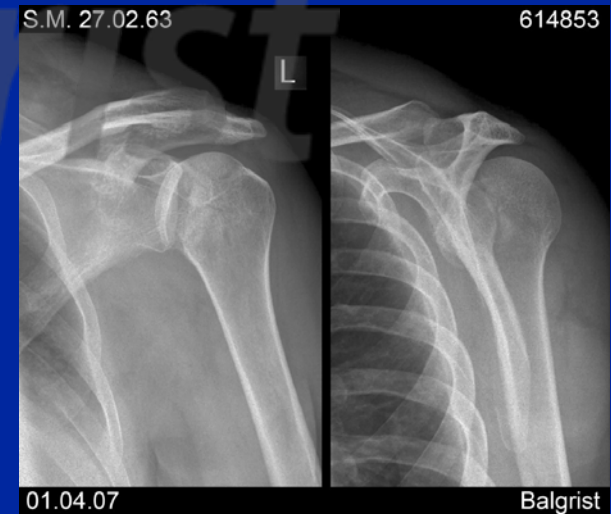
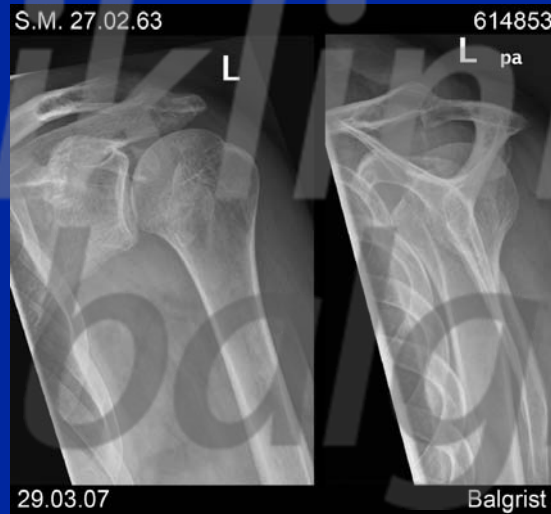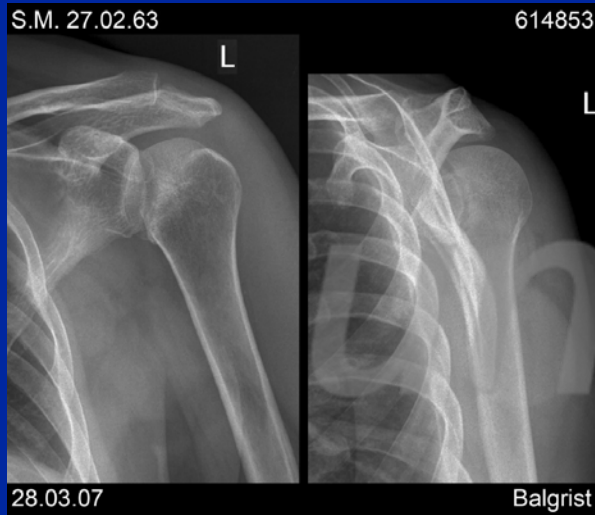# POSTERIOR SHOULDER DISLOCATION OPEN REDUCTION, NO GRAFT, NO SCREW



# POSTERIOR SHOULDER DISLOCATION OPEN REDUCTION, NO GRAFT, NO SCREW

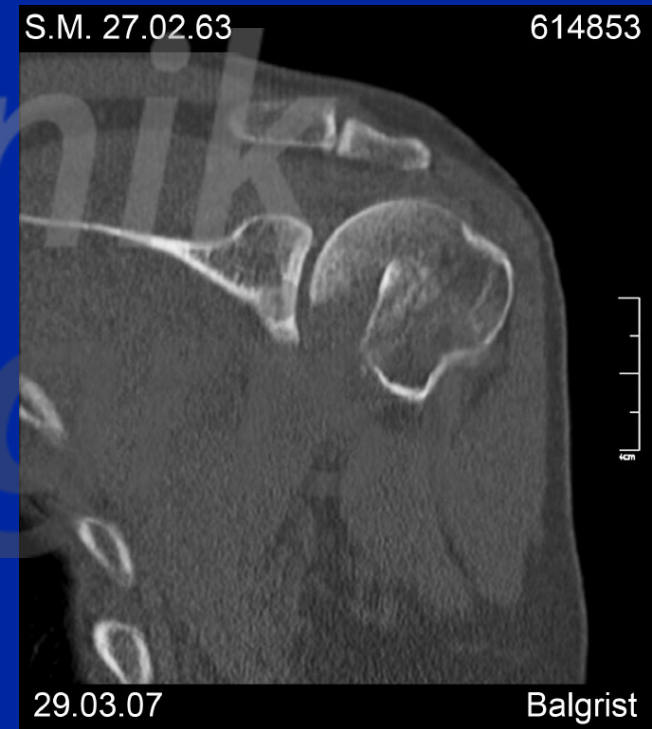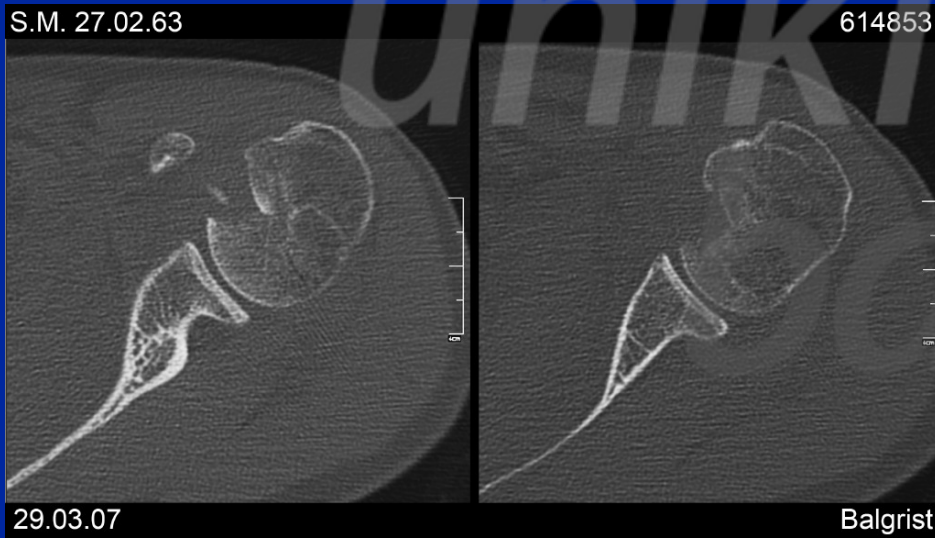


# POSTERIOR SHOULDER DISLOCATION CLOSED REDUCTION, REDISLOCATION

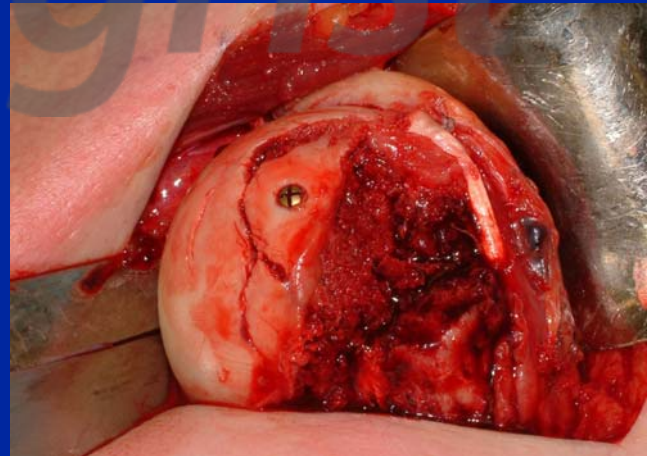
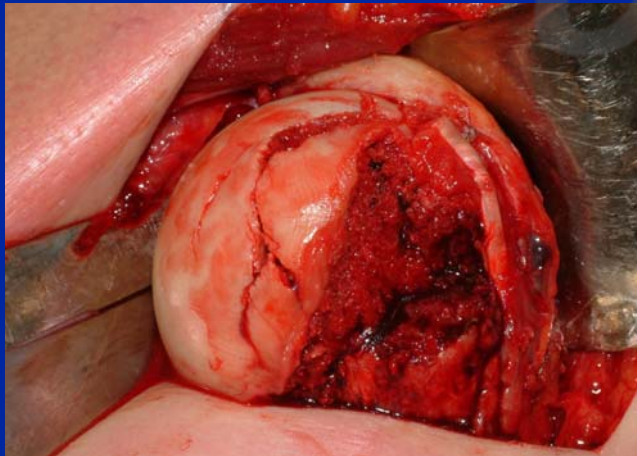
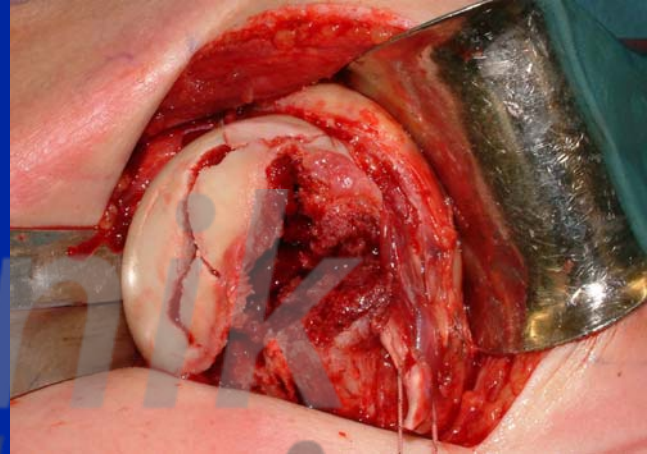
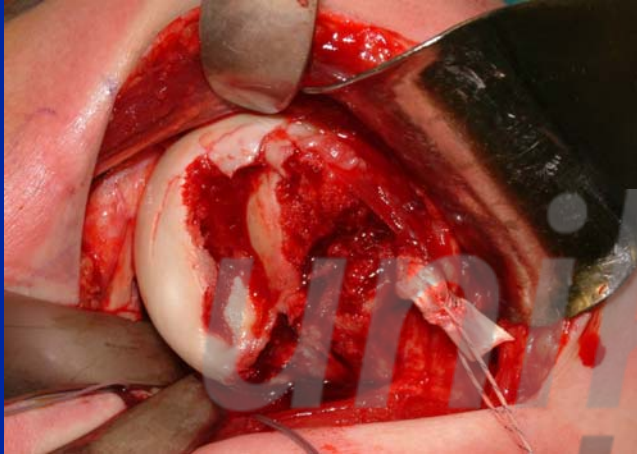




# POSTERIOR SHOULDER DISLOCATION HEAD DEFECT 25-50%

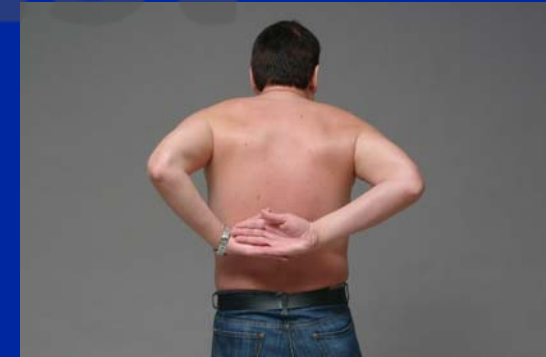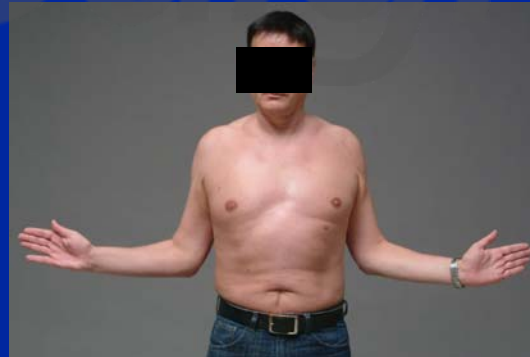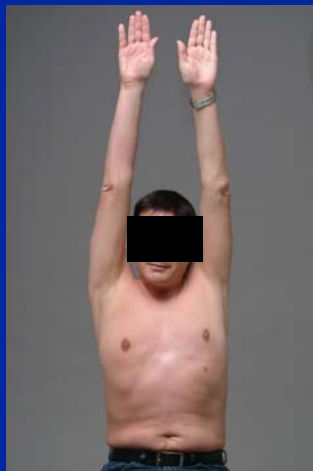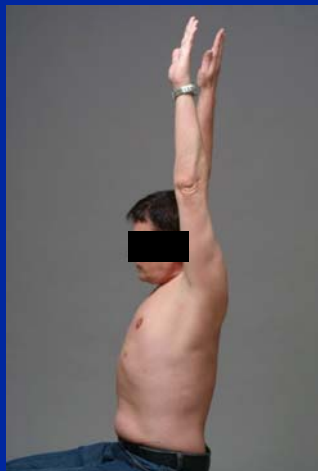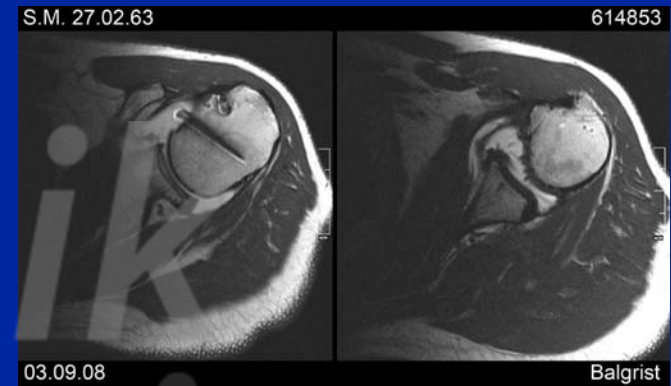


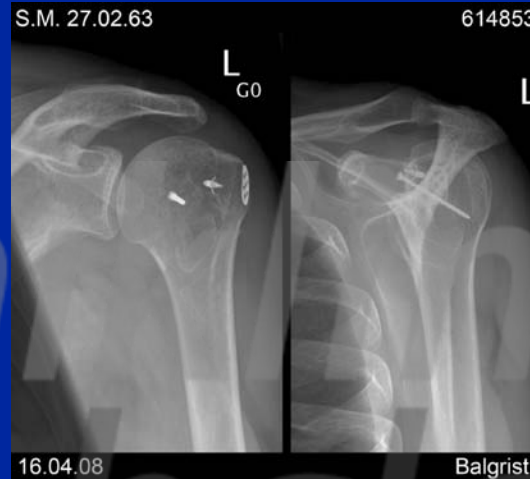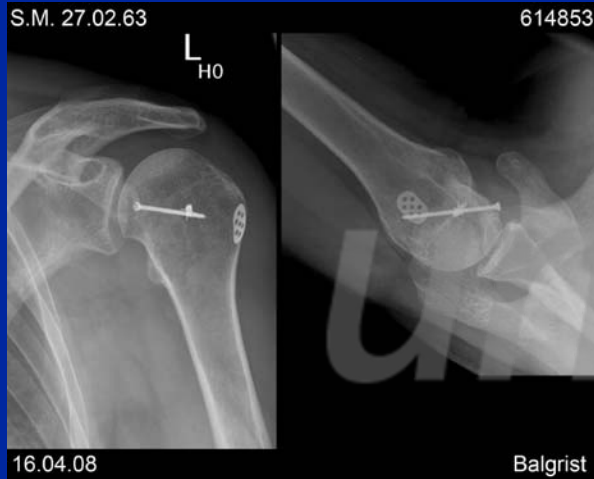# POSTERIOR SHOULDER DISLOCATION HEAD DEFECT 25-50%, AUTOGRAFT



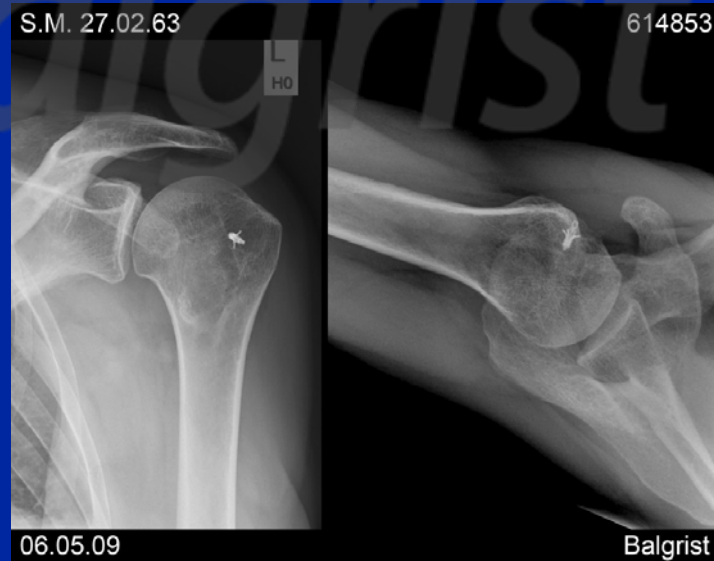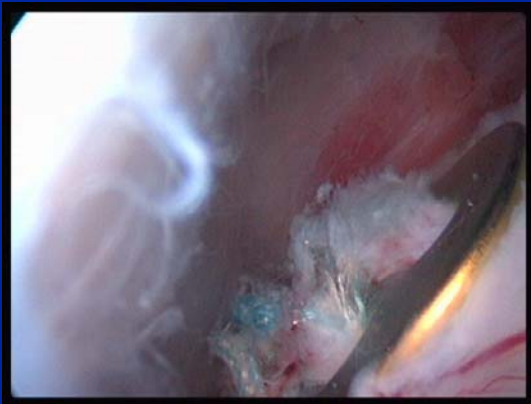
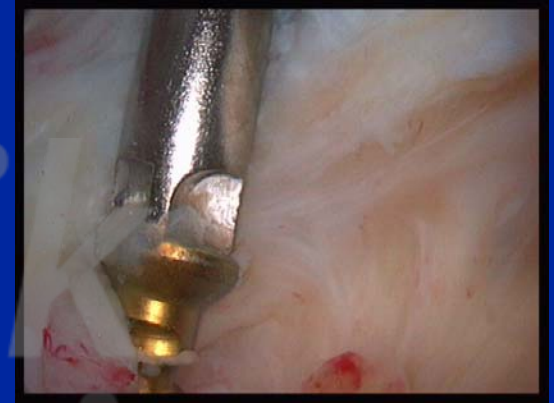
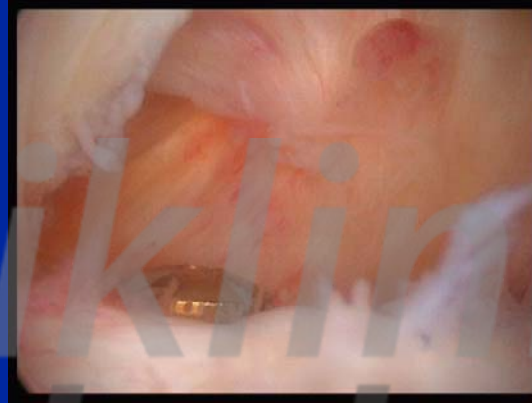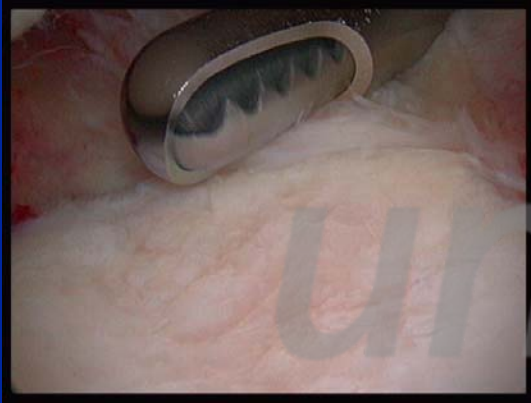
uniklinik  
balgrist

# POSTERIOR SHOULDER DISLOCATION SECONDARY IMPINGEMENT



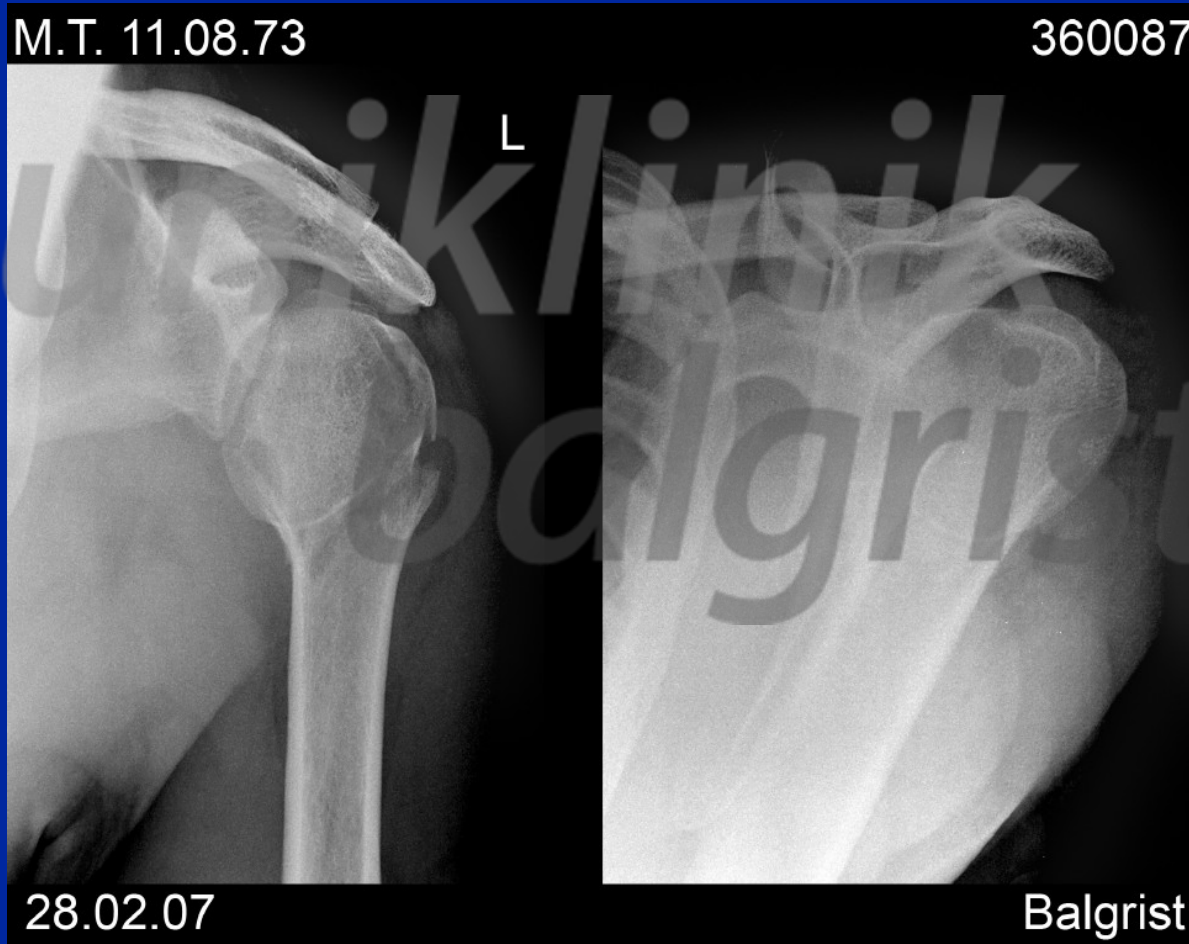

# POSTERIOR SHOULDER DISLOCATION ARTHROSCOPY

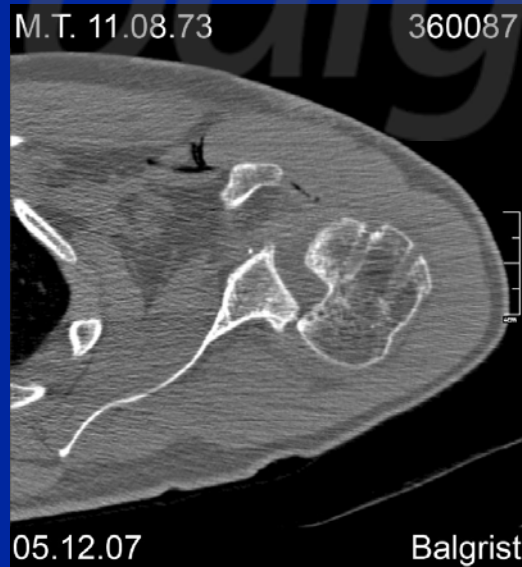
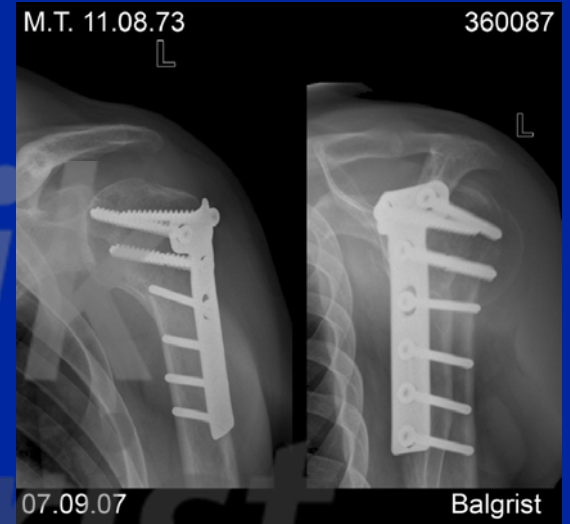
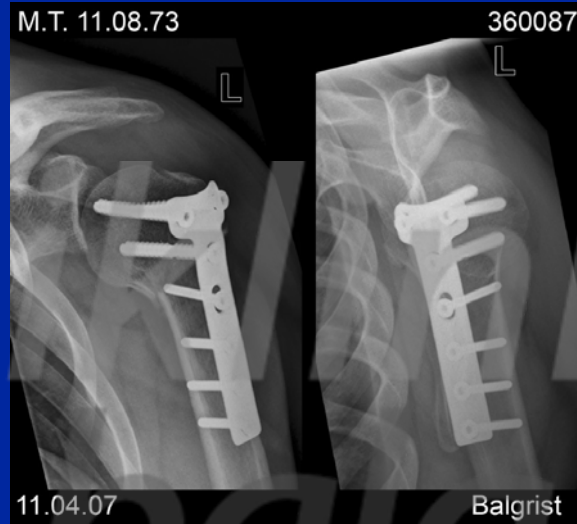
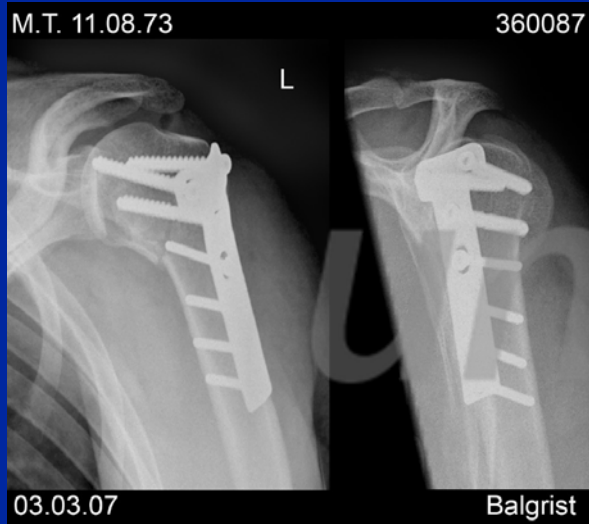
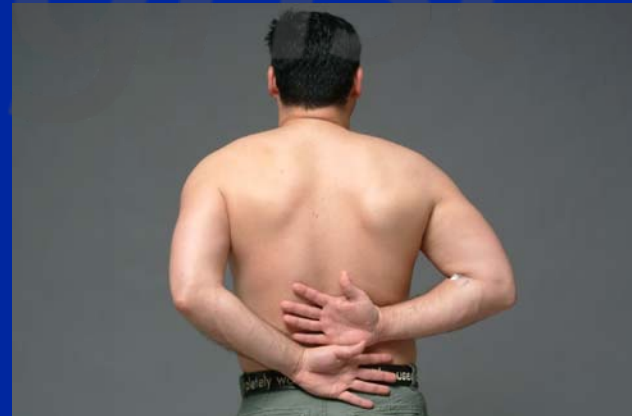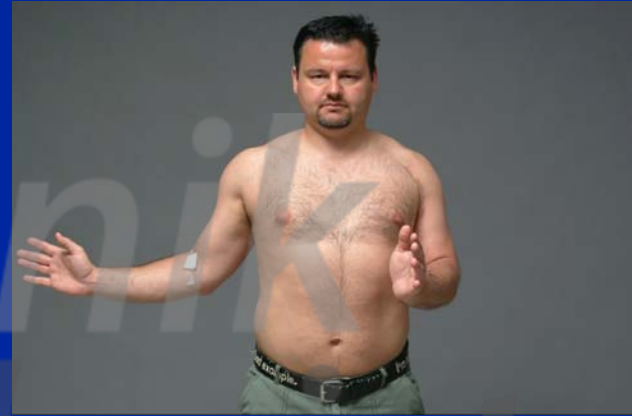# POSTERIOR SHOULDER DISLOCATION MISSED



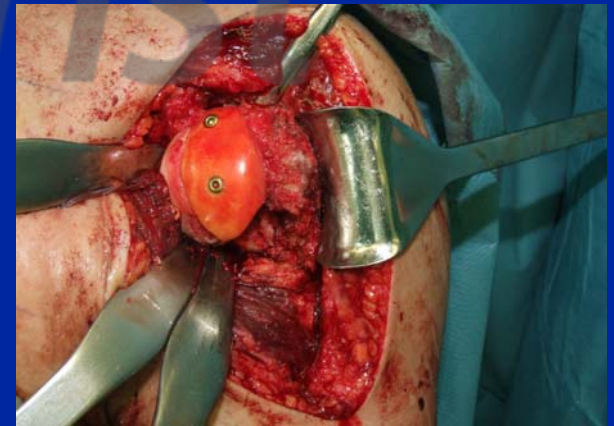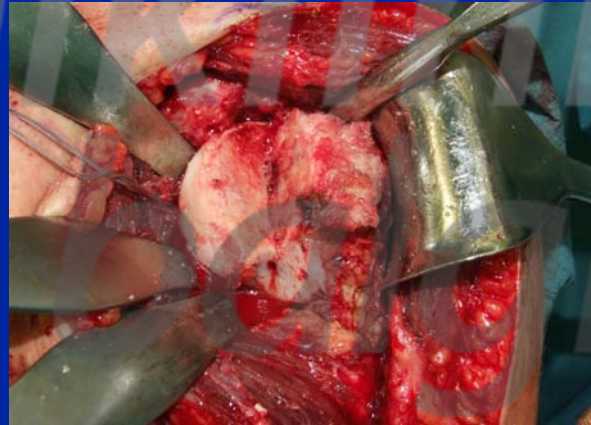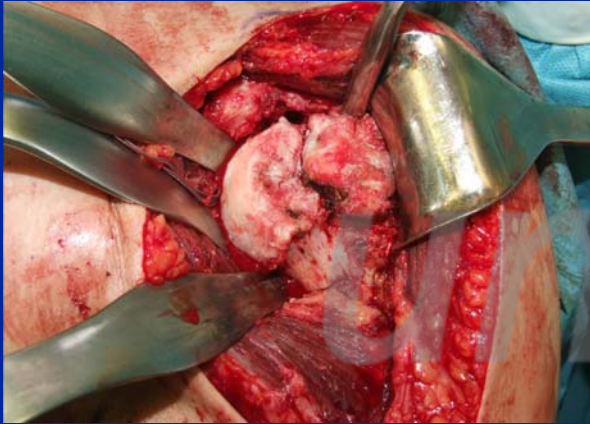
# POSTERIOR SHOULDER DISLOCATION MISSED, ORIF HUMERUS FX



# POSTERIOR SHOULDER DISLOCATION MISSED, ORIF HUMERUS FX

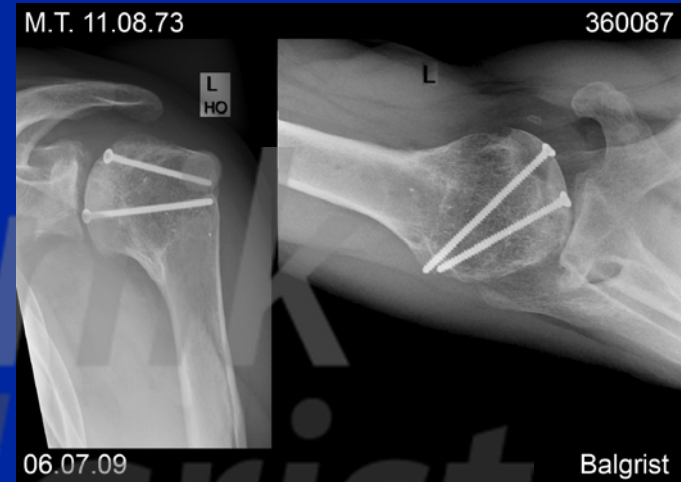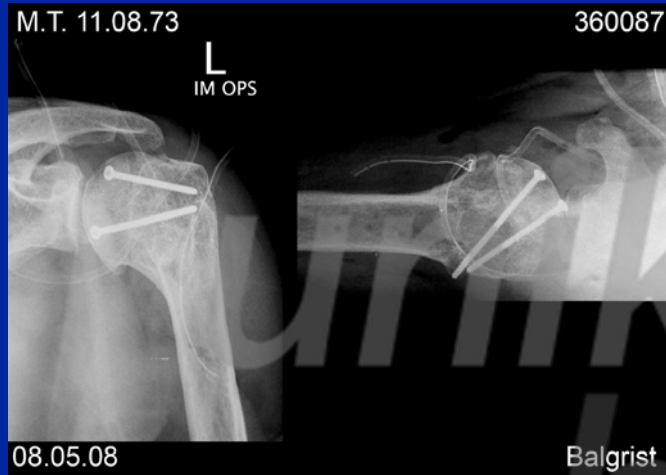


# POSTERIOR SHOULDER DISLOCATION OPEN REDUCTION, ALLOGRAFT

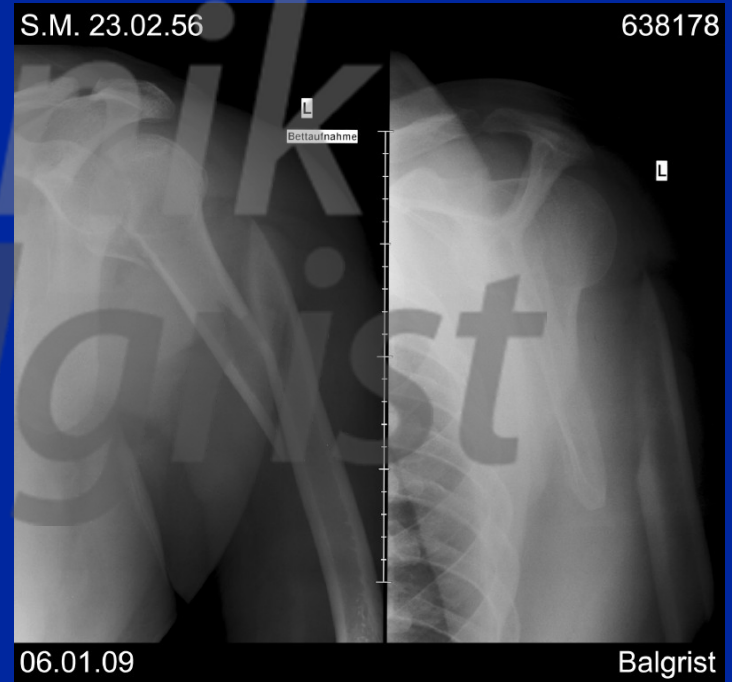
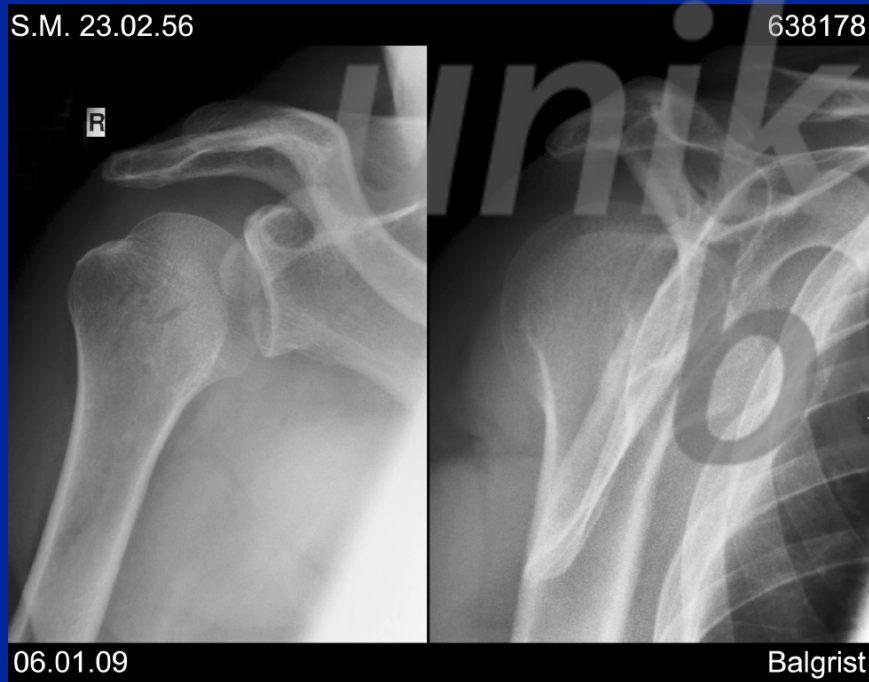




# POSTERIOR SHOULDER DISLOCATION OPEN REDUCTION, ALLOGRAFT

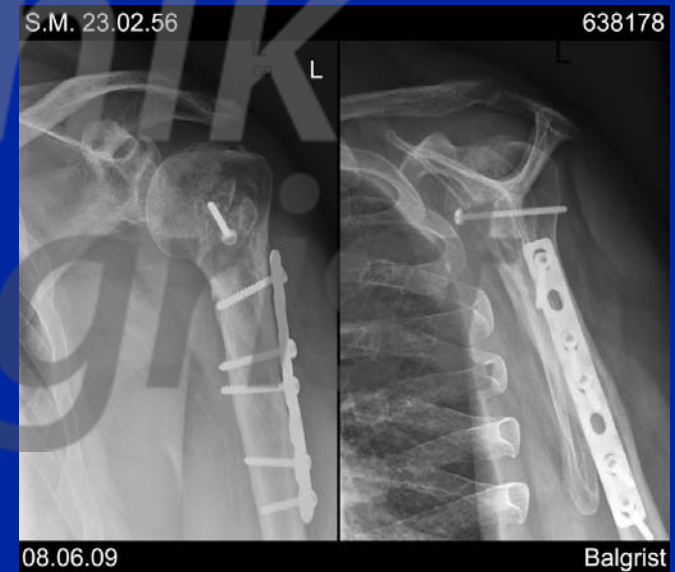
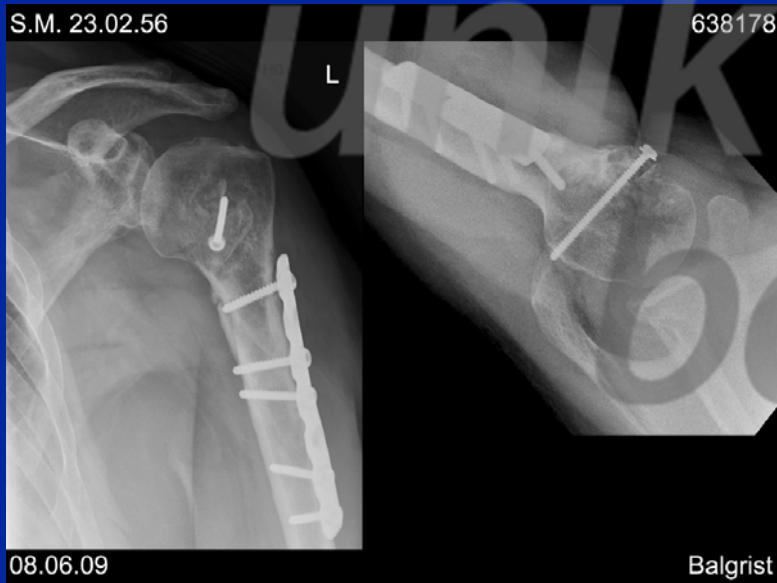
# POSTERIOR SHOULDER DISLOCATION + HUMERUS FRACTURE

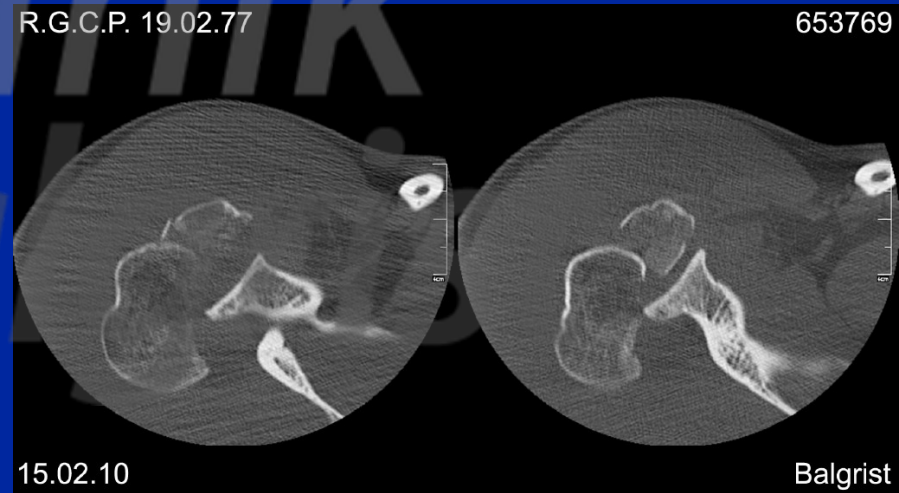
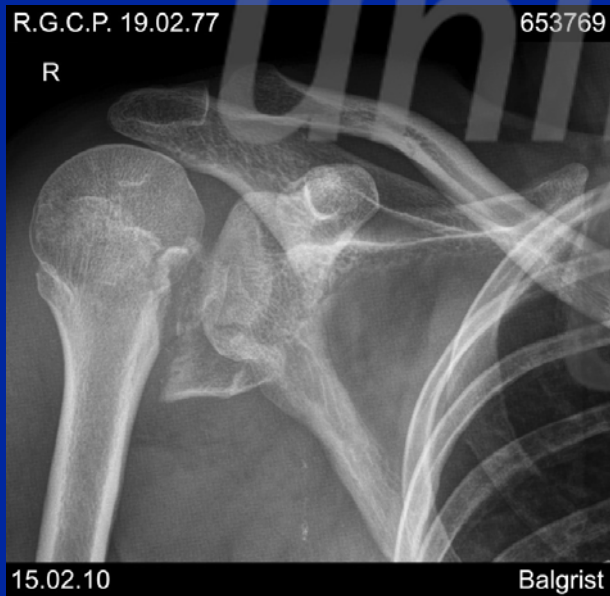

# POSTERIOR SHOULDER DISLOCATION

## OPEN: 1. ORIF 2. REDUCTION !

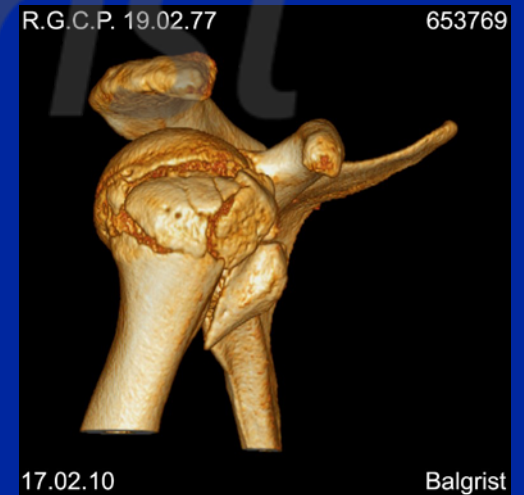
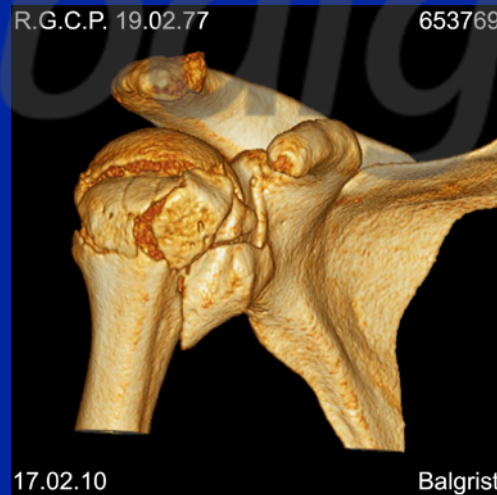
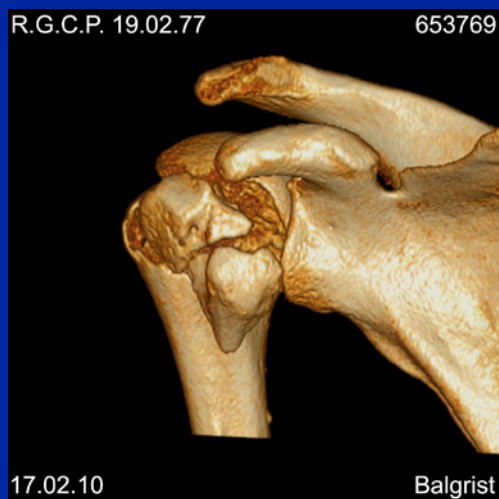
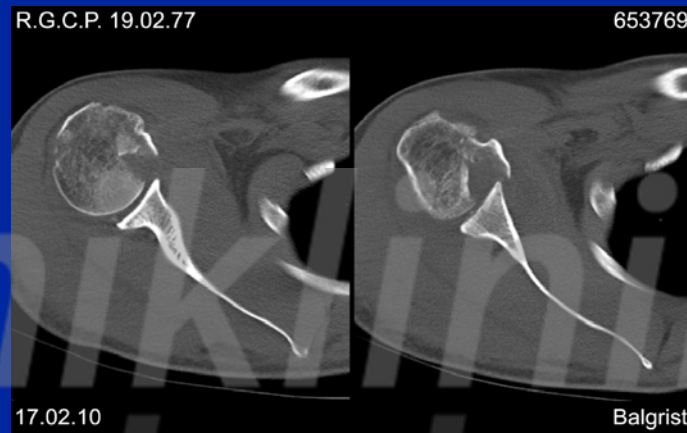
# POSTERIOR SHOULDER DISLOCATION + TUBEROSITY FRACTURES

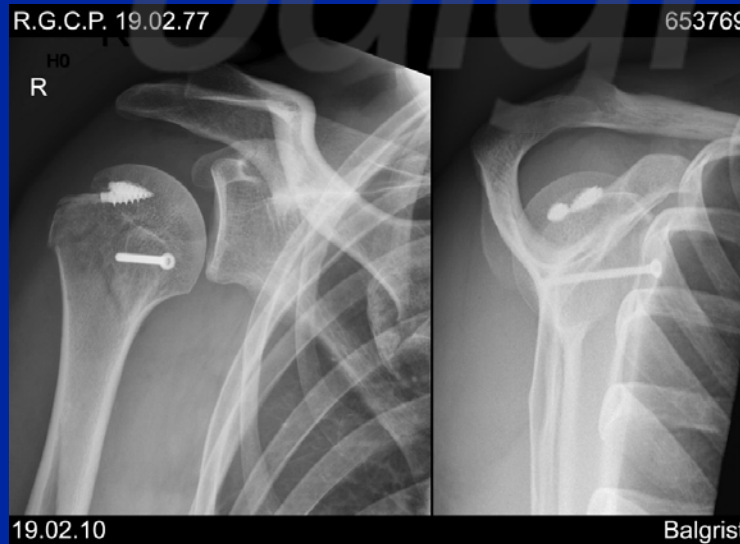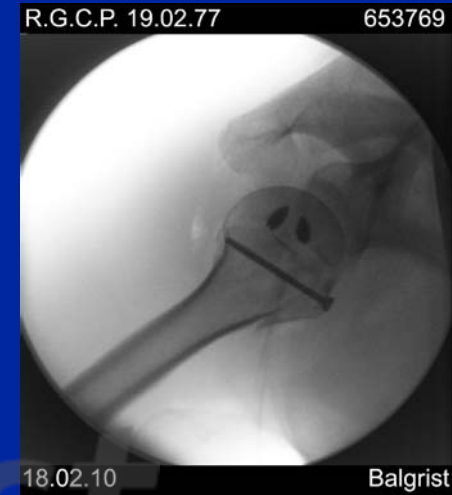

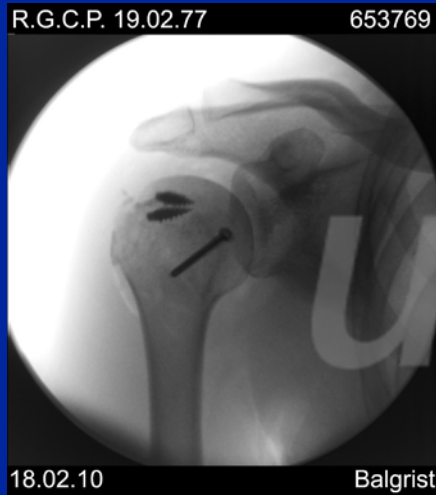




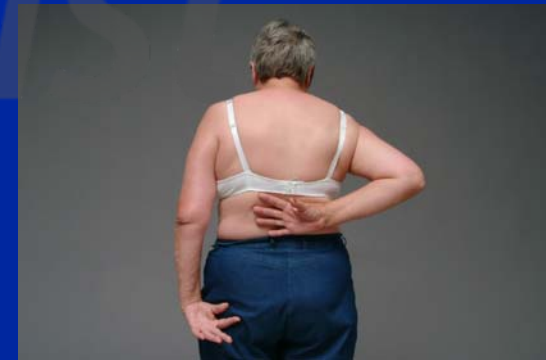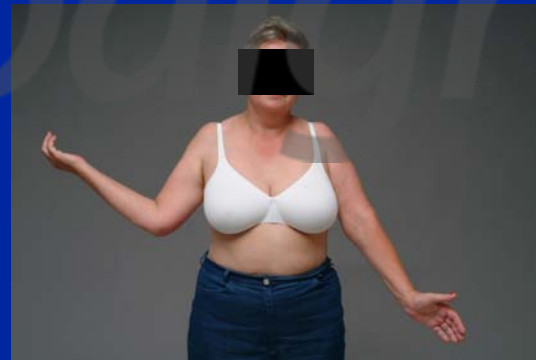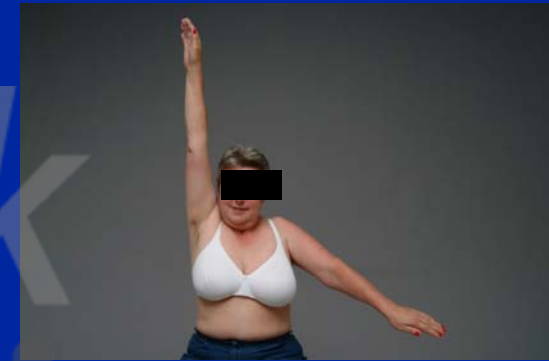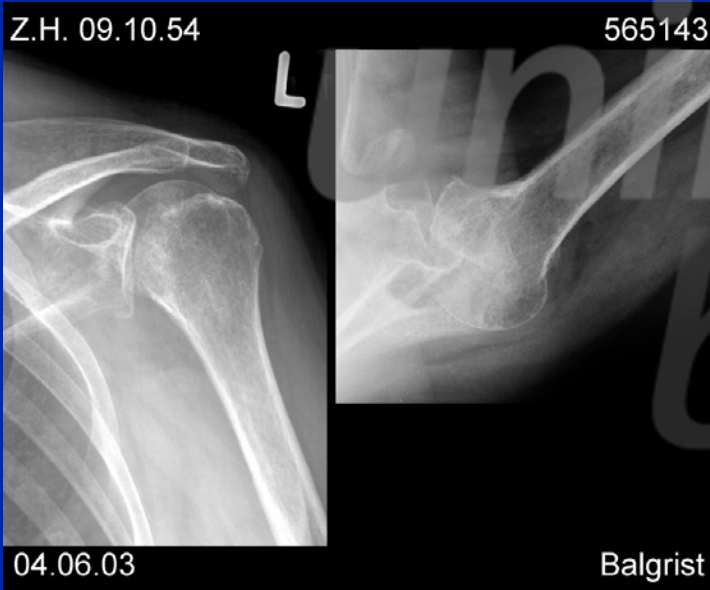# POSTERIOR SHOULDER DISLOCATION CLOSED REDUCTION



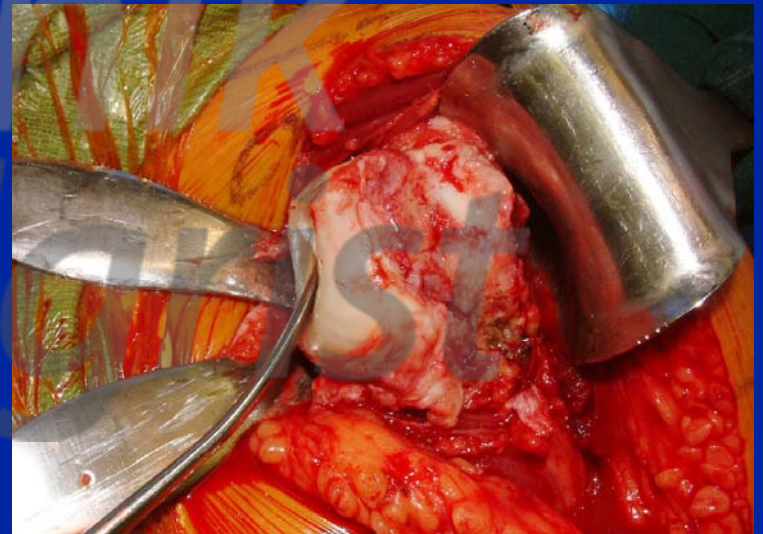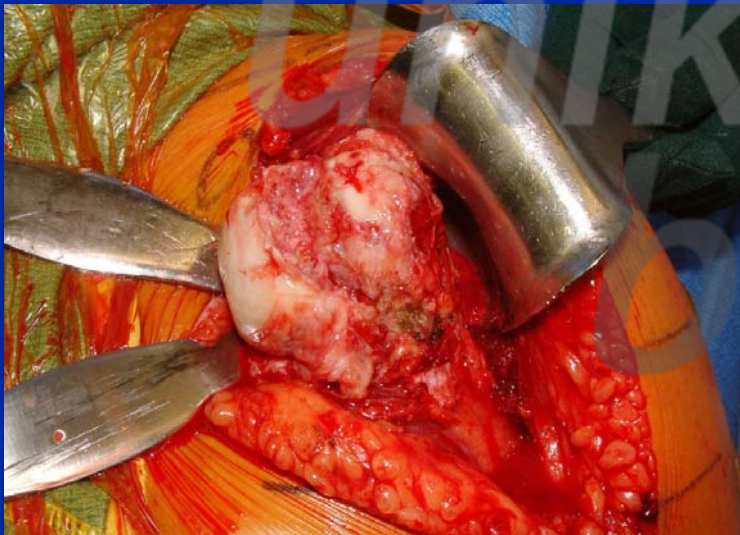
# POSTERIOR SHOULDER DISLOCATION OPEN TUBEROSITY REFIXATION



# POSTERIOR SHOULDER DISLOCATION LOCKED AND MISSED UNTIL CHRONIC

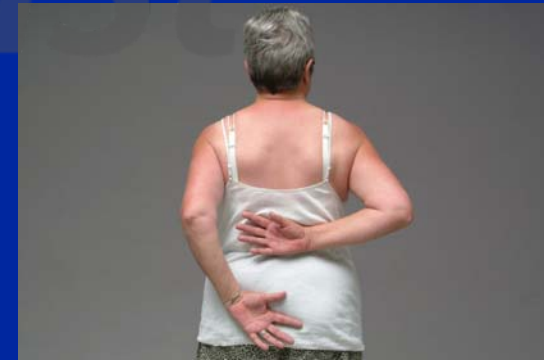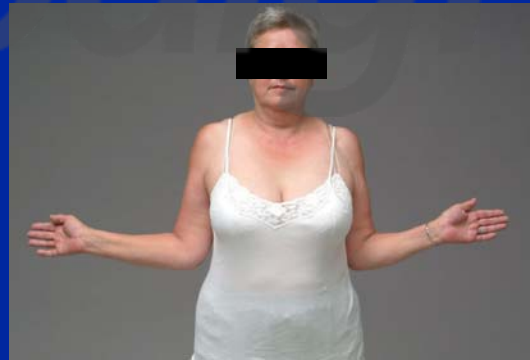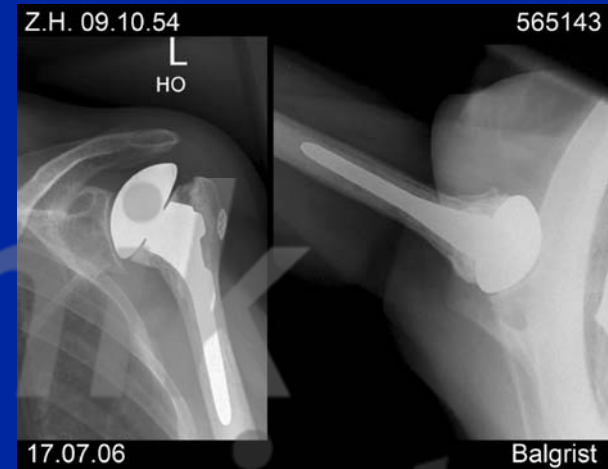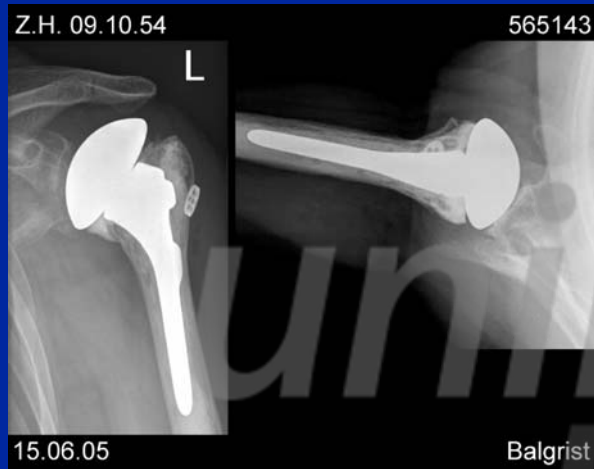


# POSTERIOR SHOULDER DISLOCATION LOCKED AND MISSED UNTIL CHRONIC

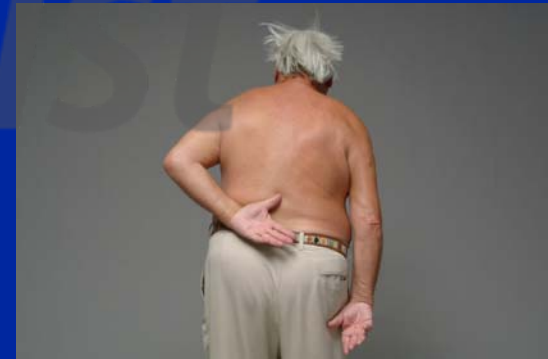
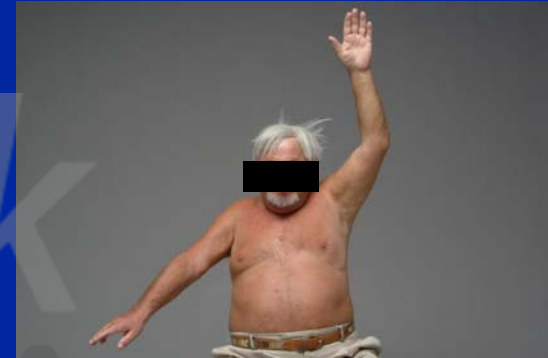
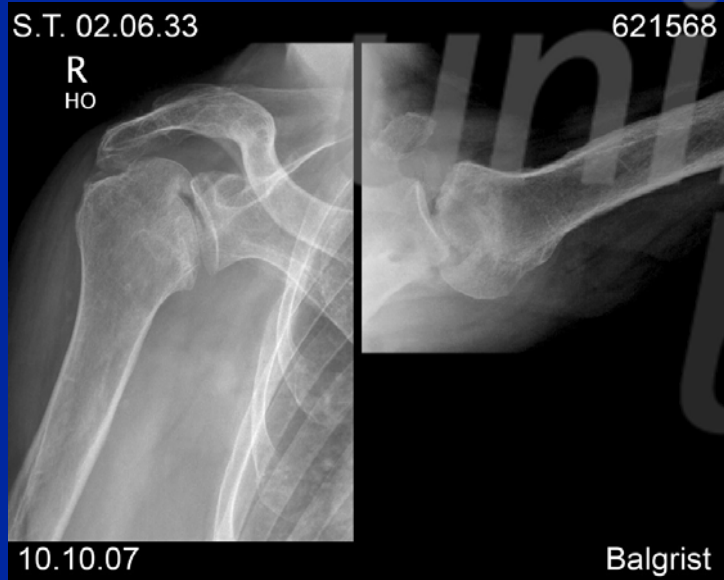

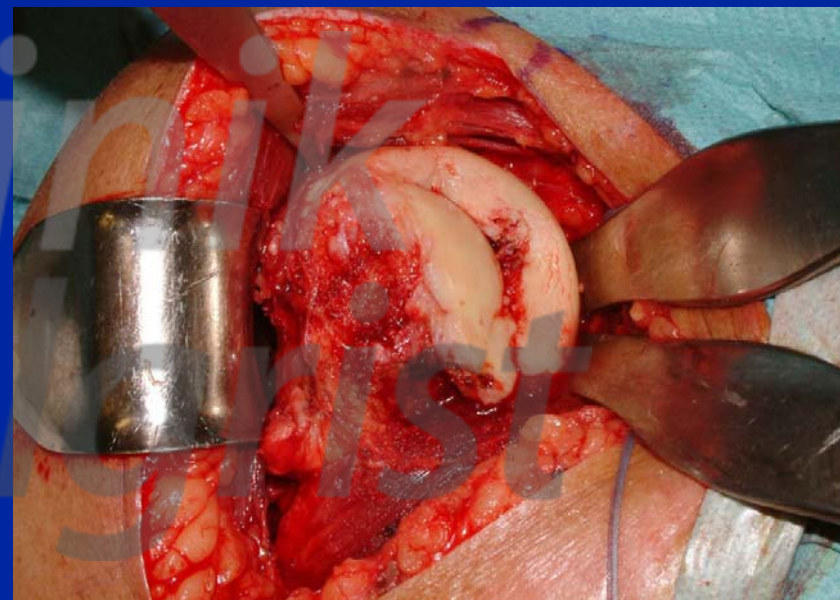
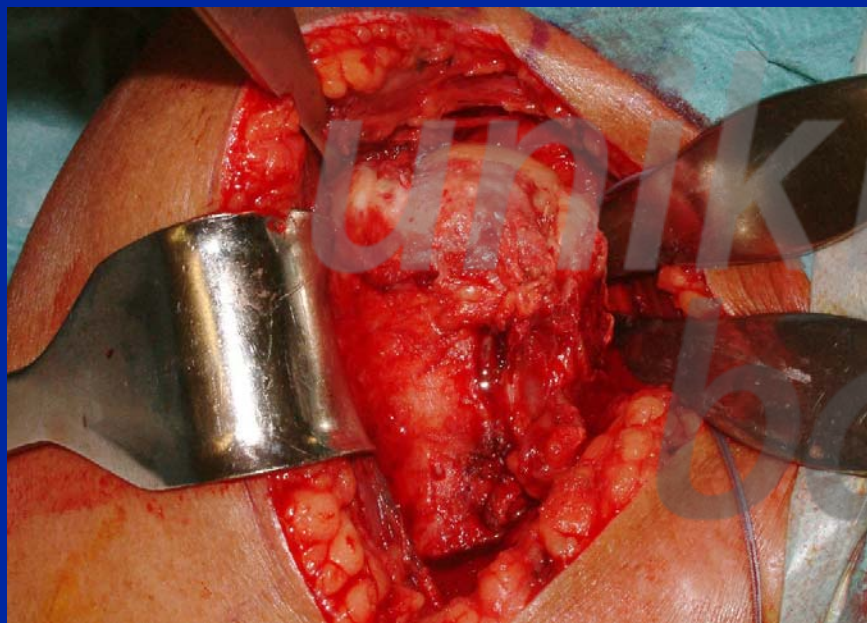# POSTERIOR SHOULDER DISLOCATION HEMI PROSTHESIS



# LOCKED POSTERIOR DISLOCATION LOCKED AND MISSED UNTIL CHRONIC

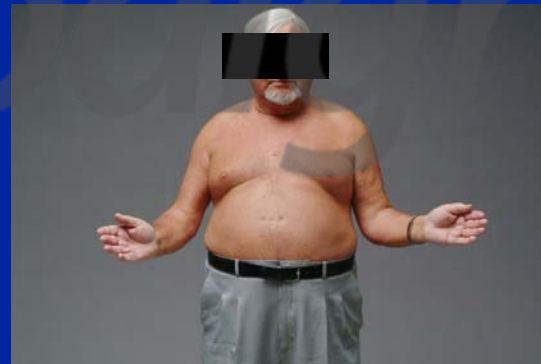
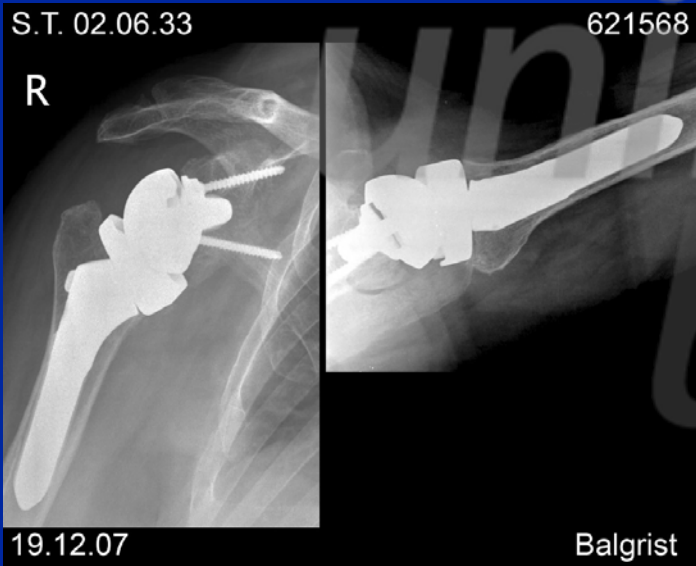

# LOCKED POSTERIOR DISLOCATION LOCKED AND MISSED UNTIL CHRONIC



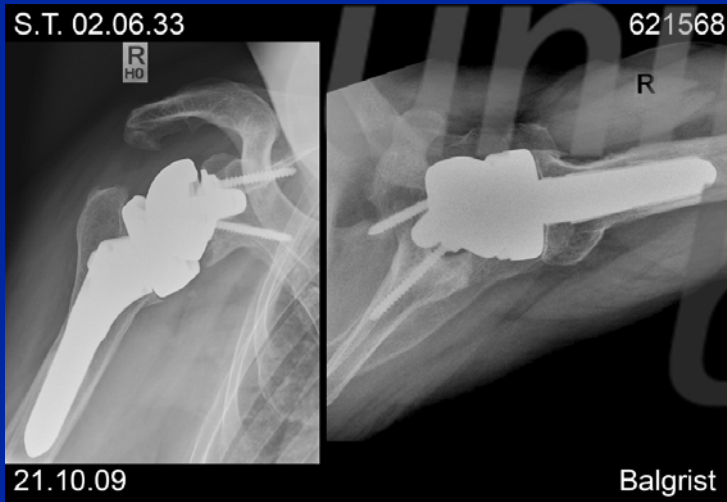
# LOCKED POSTERIOR DISLOCATION

## INVERSE TSA





# 1 YEAR POSTOP



# I HAVE NOTHING TO ADD

---

## POSTERIOR DISLOCATION OF THE SHOULDER

HARRISON L. MCLAUGHLIN  
*J Bone Joint Surg Am.* 1952;34:584-590.

---

### SUMMARY

Posterior dislocation of the humerus is a diagnostic trap. Clinical and roentgenographic evidence of this lesion is always present, but usually escapes notice unless educated. Recent lesions, recognized and treated at once, respond rapidly and well to simple measures. Recurrent or unreduced lesions require operative treatment.

# THANK YOU

