



Stage III Posterior Tibial Tendon Dysfunction

9/9/11

Anish R. Kadakia MD

Assistant Professor, University of Michigan
Chief – Division of Foot and Ankle Surgery
Department of Orthopedic Surgery

Disclosure

Synthes – Consultant

Ascension - Consultant

I have no potential conflicts
with this presentation.

Stage III

- **Definition**

- **Fixed hindfoot valgus with associated hindfoot abduction w/ or w/o forefoot supination secondary to chronic PTTD**

UNIKLINIK BALGRIST

September 9th, 2011

Stage III

■ Simplified definition

■ Rigid Flatfoot (Just won't move)

■ Long-standing PTTD

■ Coalition

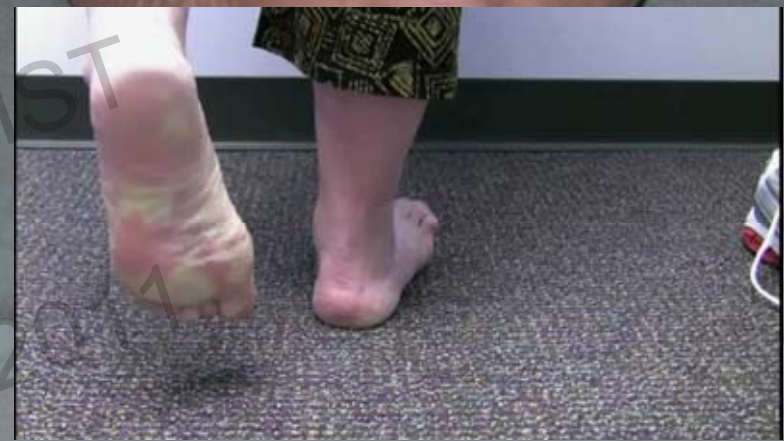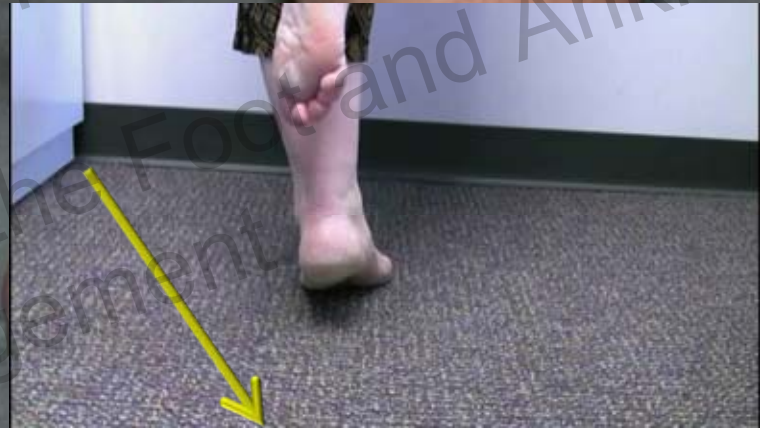■ Effectively functions as Stage III

■ Arthrosis

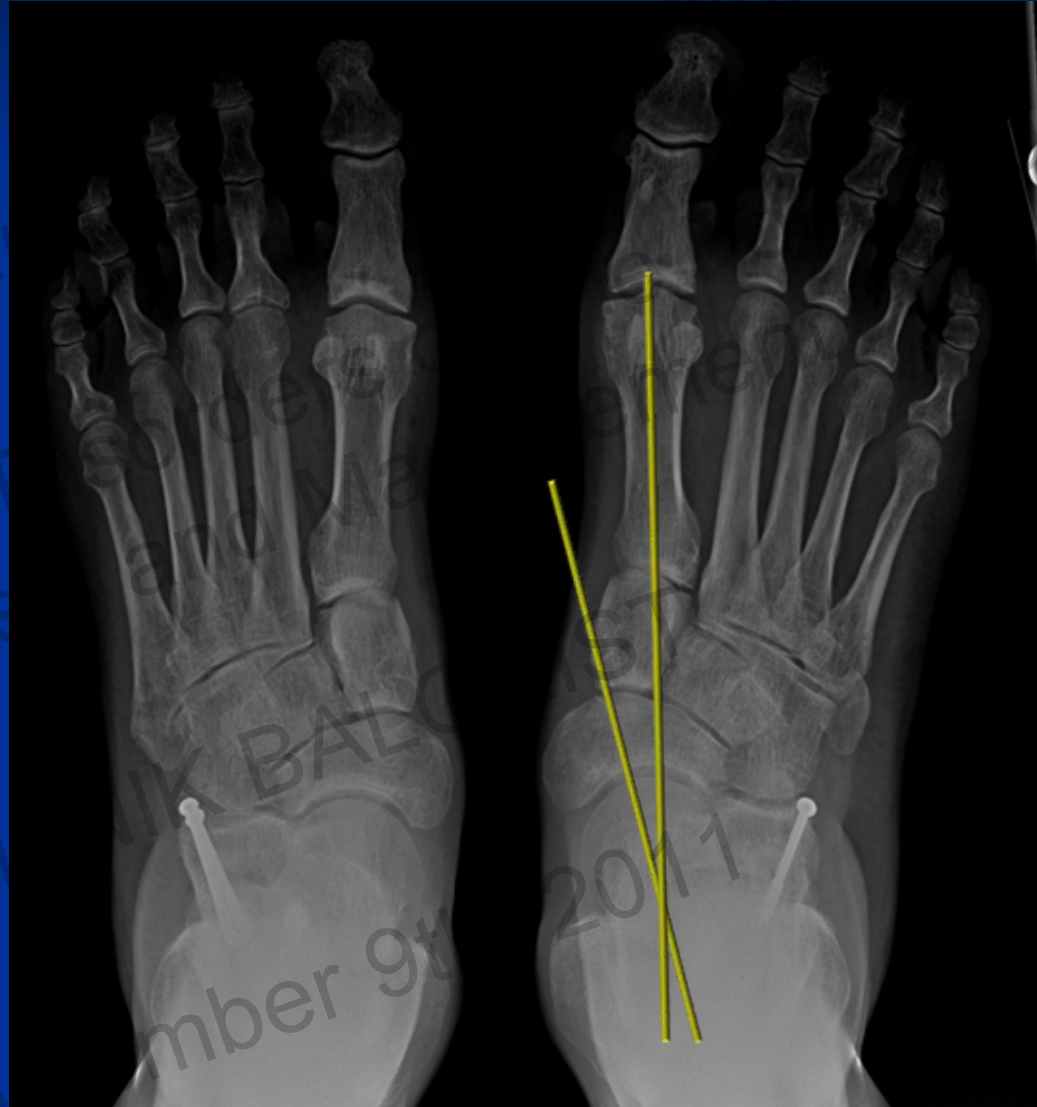■ Failed prior correction

Clinical Symptoms/Signs

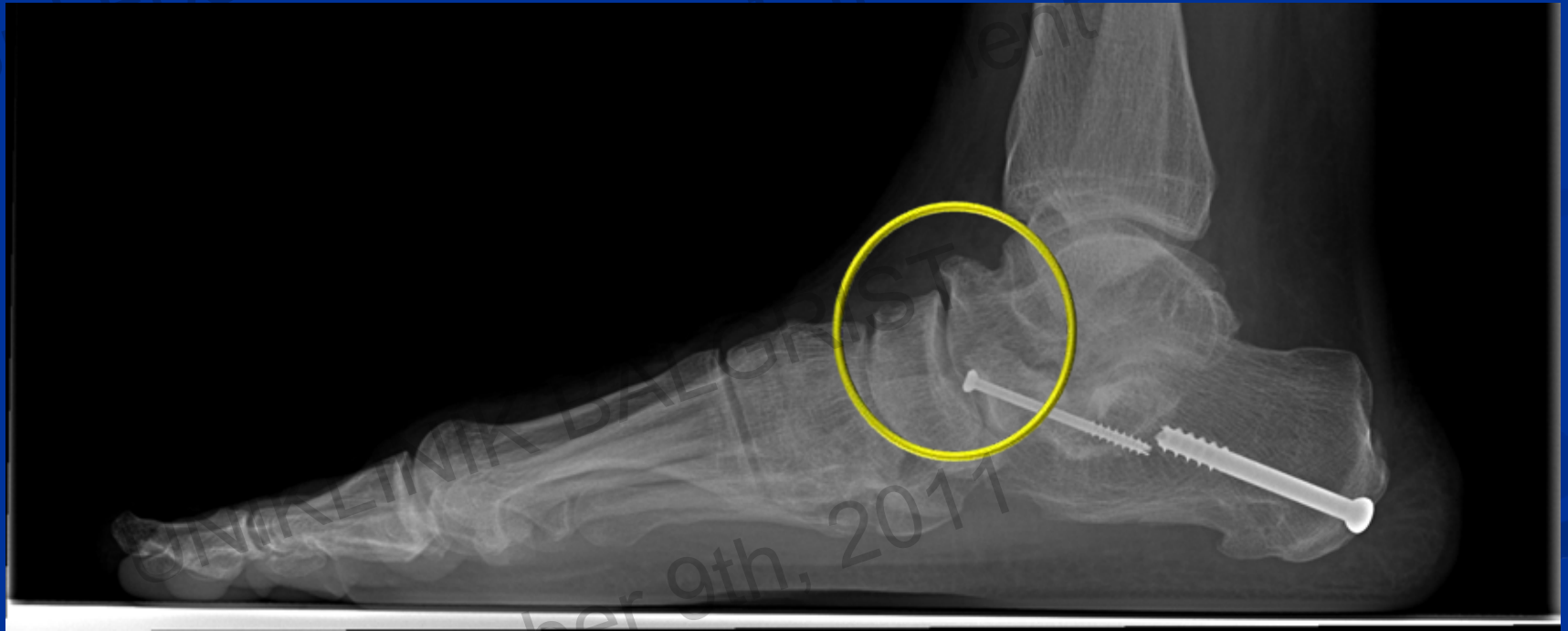- Pain
 - Posteromedial – over PTT
 - Sinus Tarsi
 - Subfibular impingement
- “Too many toes” sign
- Swelling
 - PM over PTT
- Limited Hindfoot ROM
- Weak plantarflexion-inversion
- **Inability to perform Single-limb heel rise**



Stage III

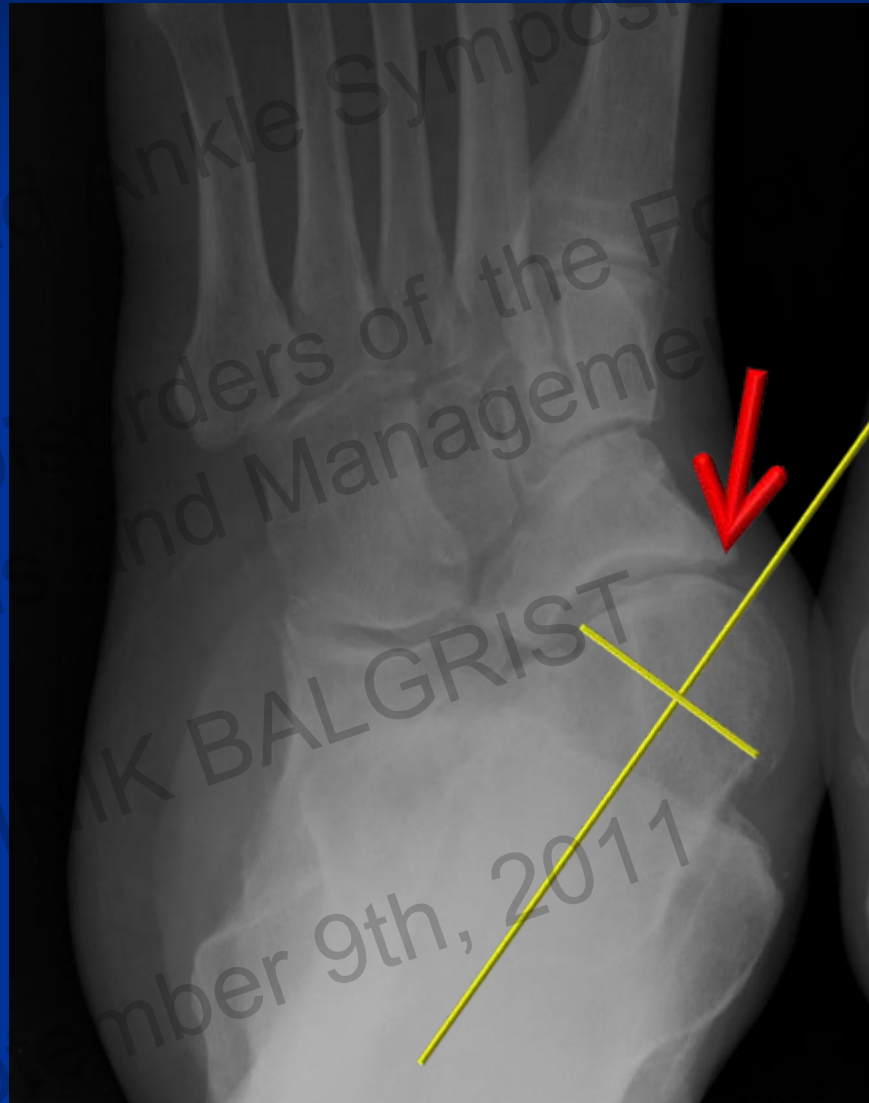

Stage III

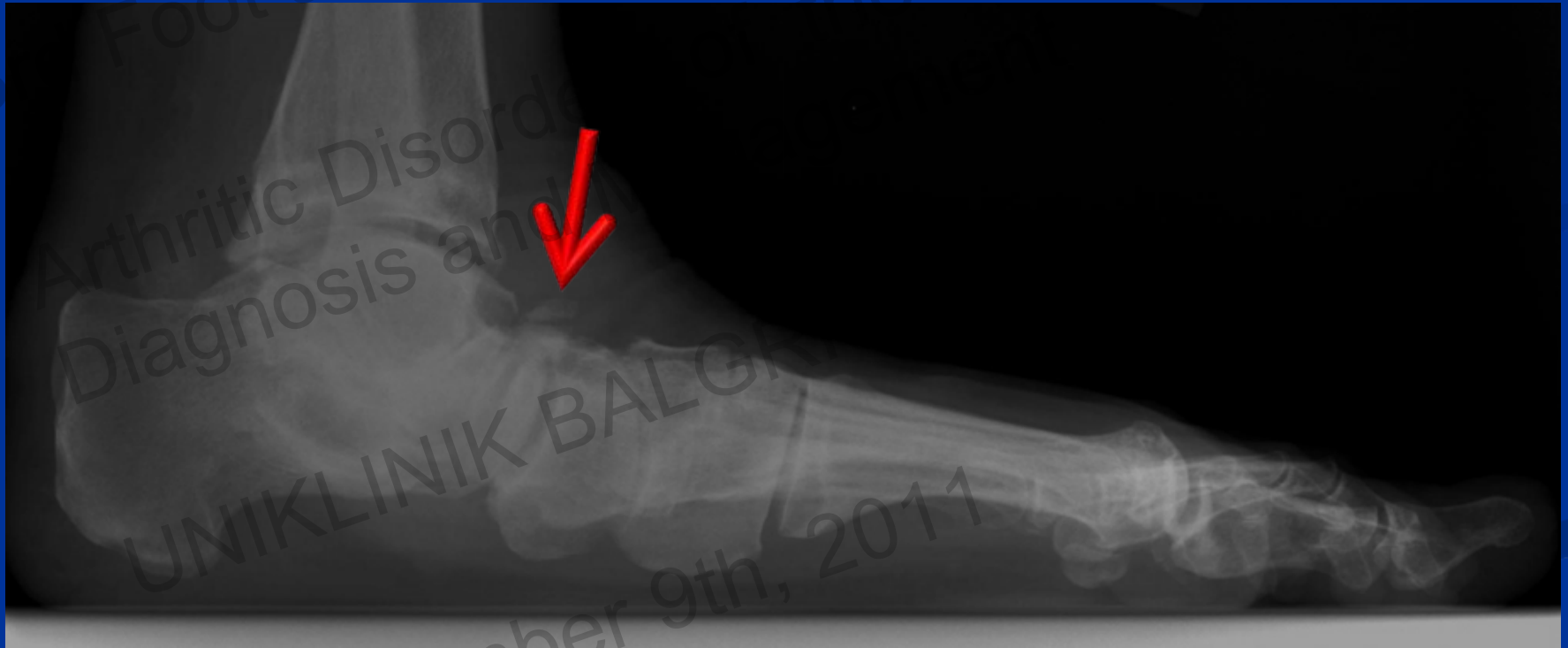

September 9th, 2011

Stage III

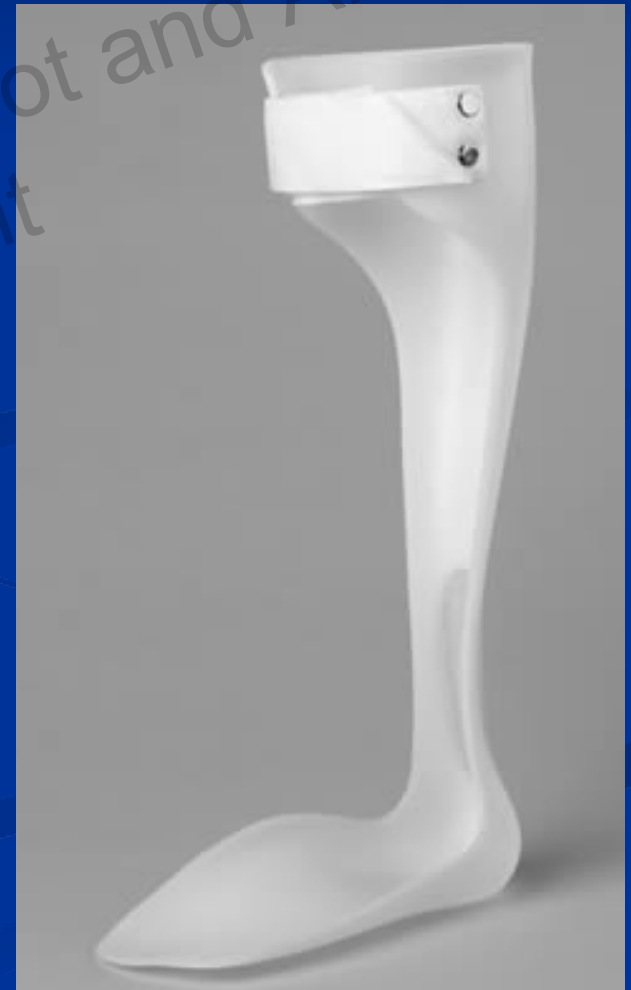

Stage III



Stage III

- Nonoperative Management
 - Accommodate Deformity
 - AFO/Arizona



Surgical Intervention

■ Arthrodesis

■ Talonavicular Joint

■ T-N fusion LOCKS hindfoot motion

■ Deland, 1997

■ Must Arthrodesis TN joint to correct the deformity

Surgical Intervention

■ Arthrodesis

- Subtalar joint

- Isolated subtalar fusion decreases T-N joint motion 26% and C-C motion 56%

 - **Deland**, 1997

- Arthrodesis of the ST required in the setting of hindfoot stiffness

 - Correct Hindfoot Valgus

 - Subtalar joint will not passively correct

Surgical Intervention

■ Arthrodesis

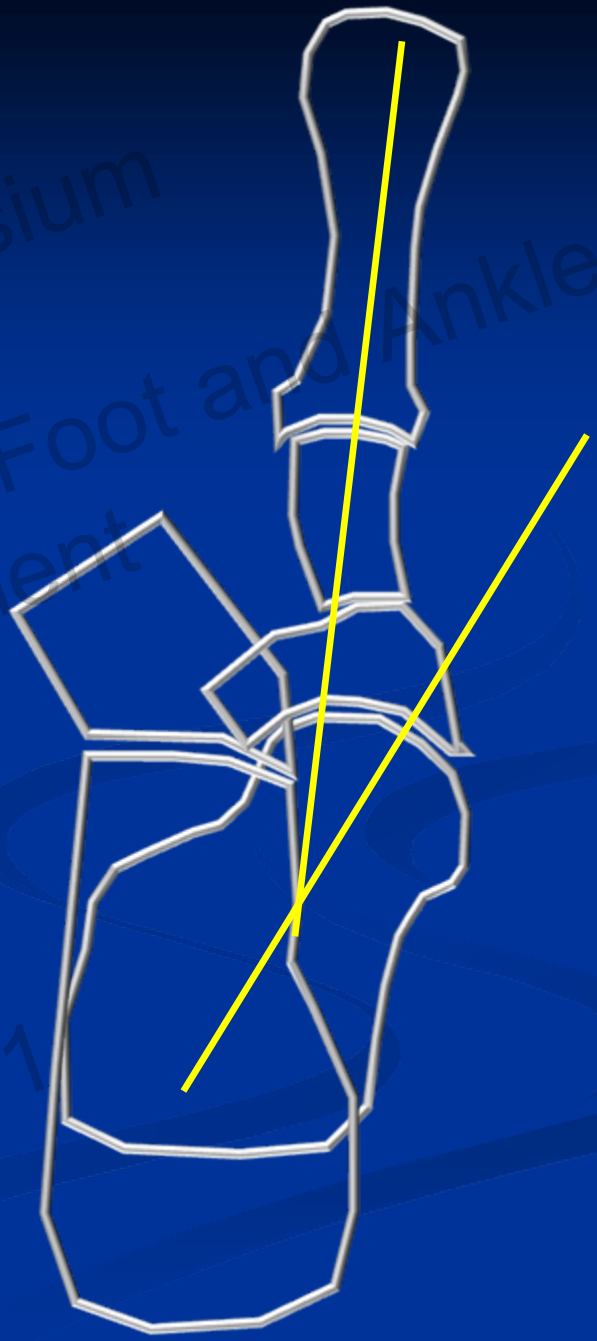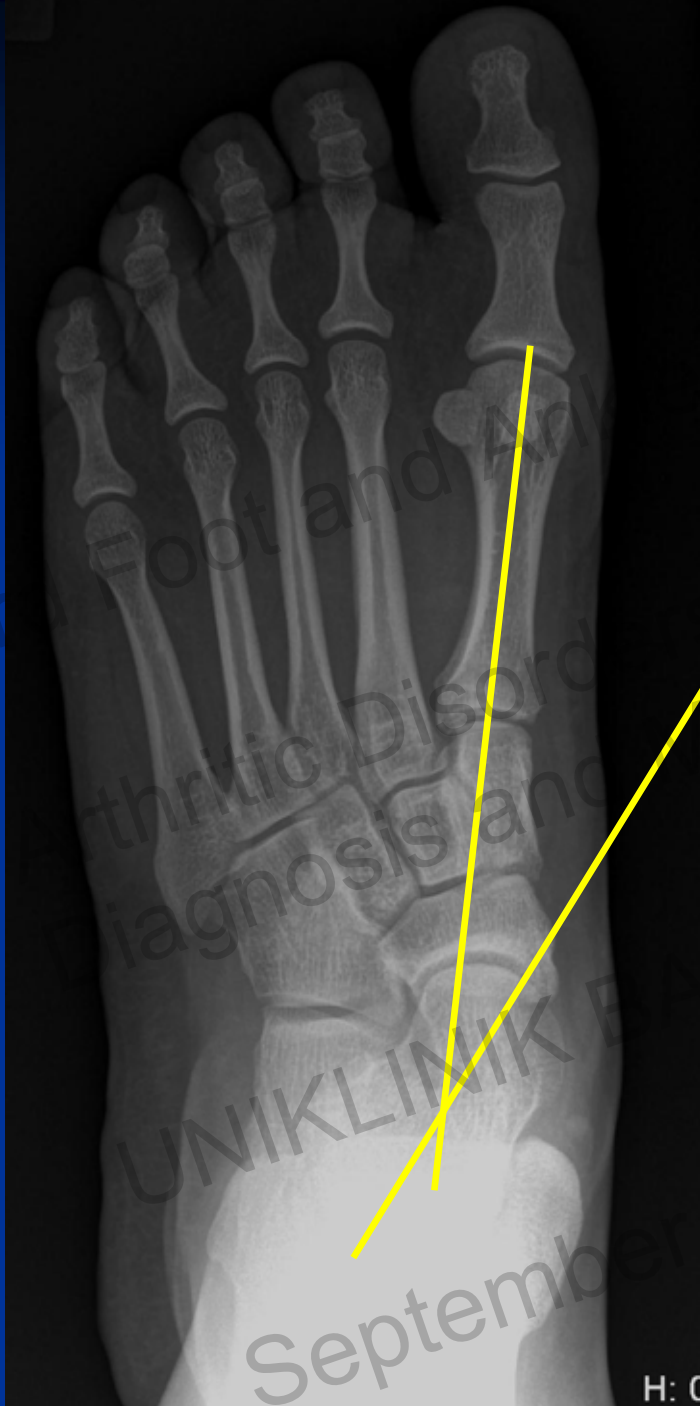
- Calcaneo-cuboid joint
- C-C fusion decreases 67% T-N motion but has little effect on subtalar joint
- Arthrodesis is not required to correct deformity
 - Exception
 - CC Arthritis
 - Coalition
 - Revision of Stiff / Failed Stage II correction
 - Inability to correct abduction

Symposium

3rd Symposium of the Foot and Ankle
Management

UNIKLINIK KLINIK FÜR ORTHOPÄDIE UND TRAUMATOLOGIE
ALGRIST

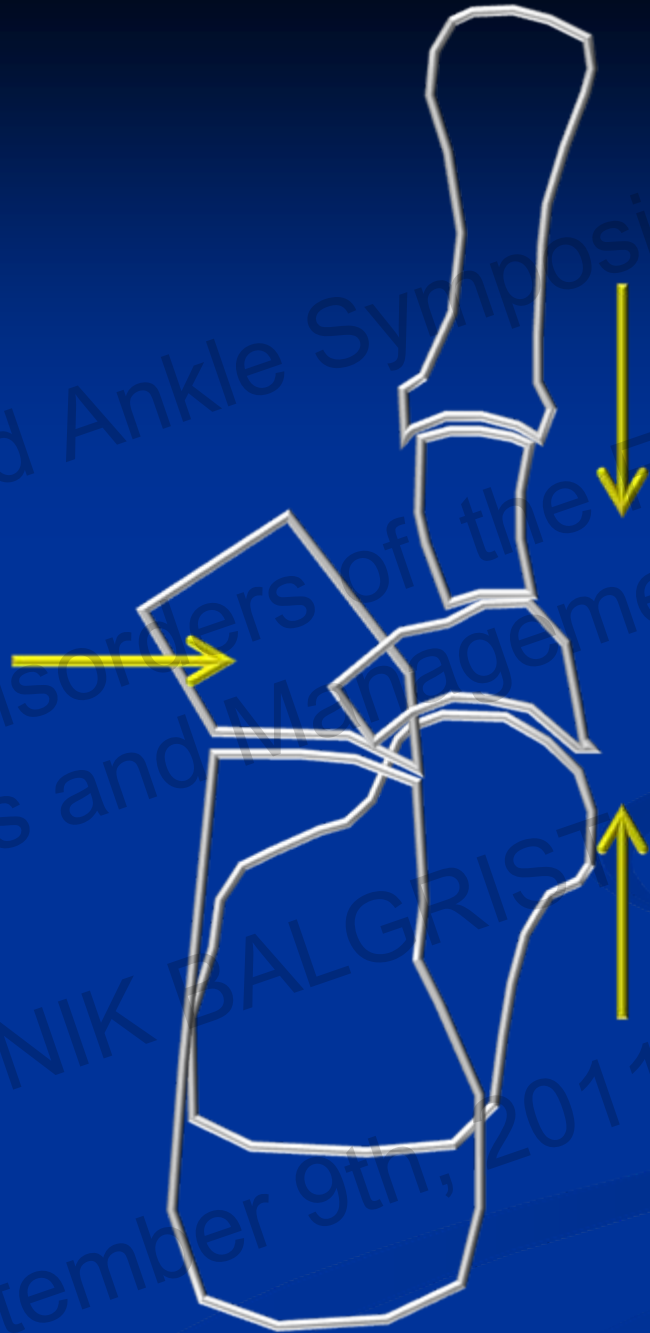
9th, 2011



September

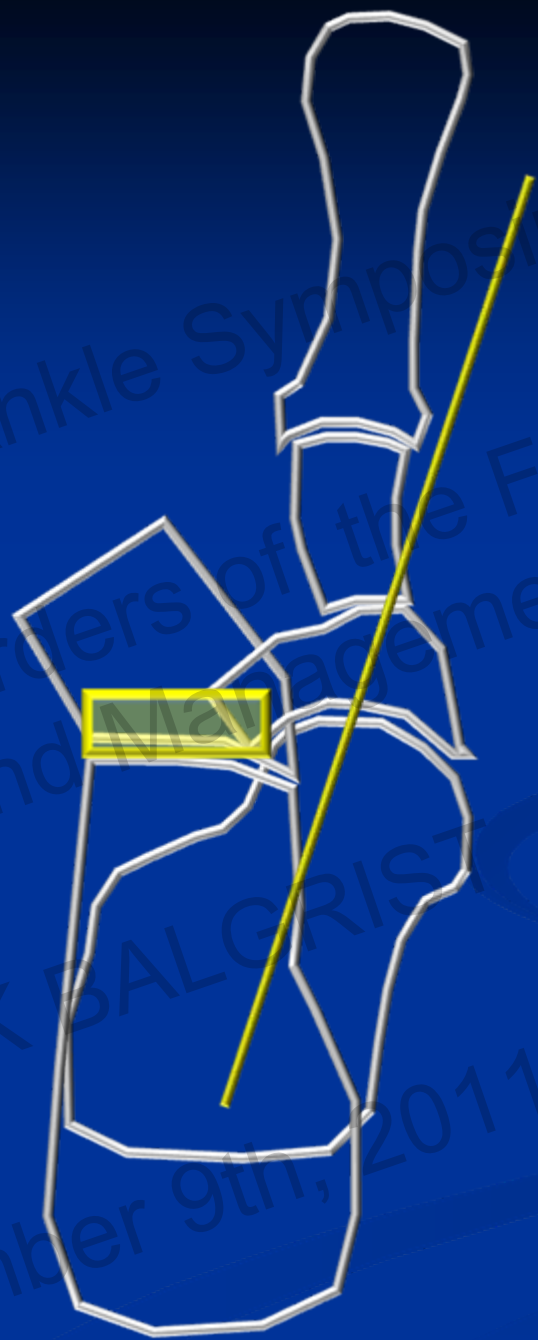H: C

3rd Foot and Ankle Symposium
Arthritic Disorders of the Foot and Ankle
Diagnosis and Management
UNIKLINIK BALGRIST
September 9th, 2011



3rd Foot and Ankle Symposium
Arthritic Disorders of the Foot and Ankle
Diagnosis and Management

UNIKLINIK BALGRIST
September 9th, 2011



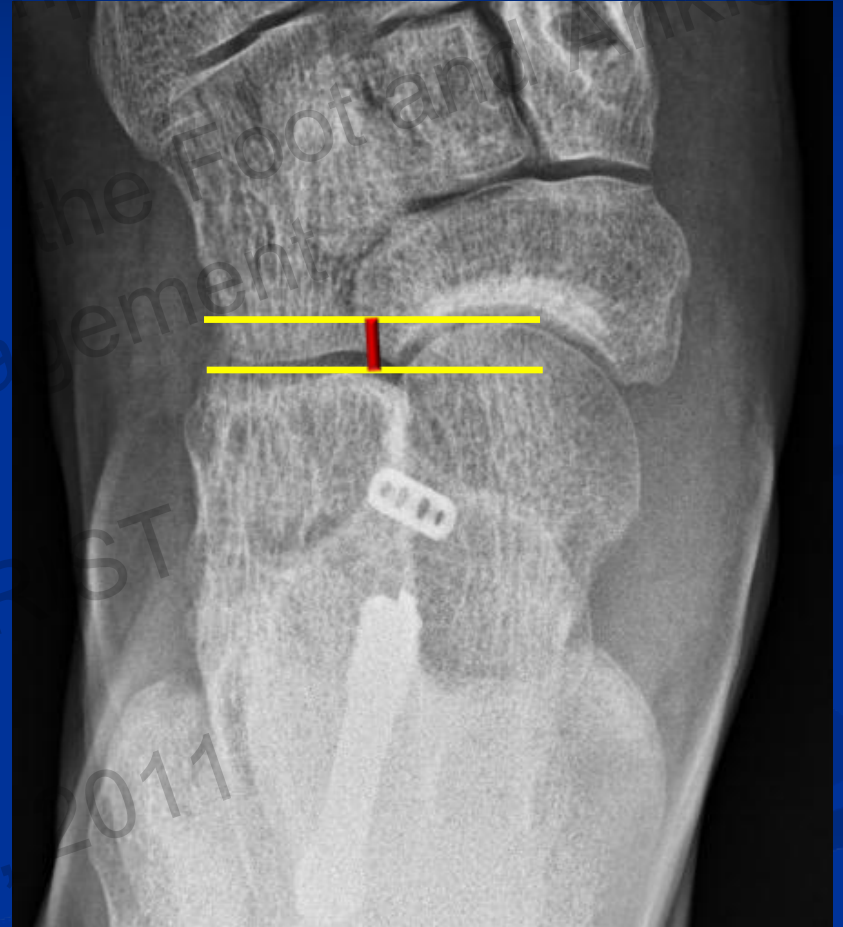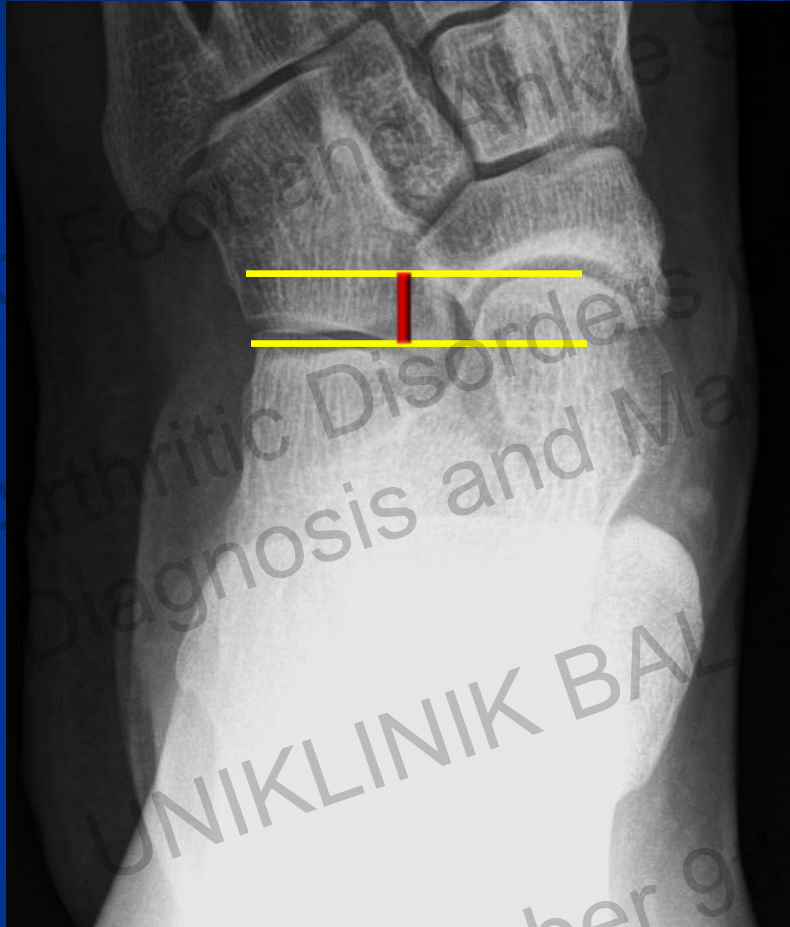3rd Foot and Ankle Symposium

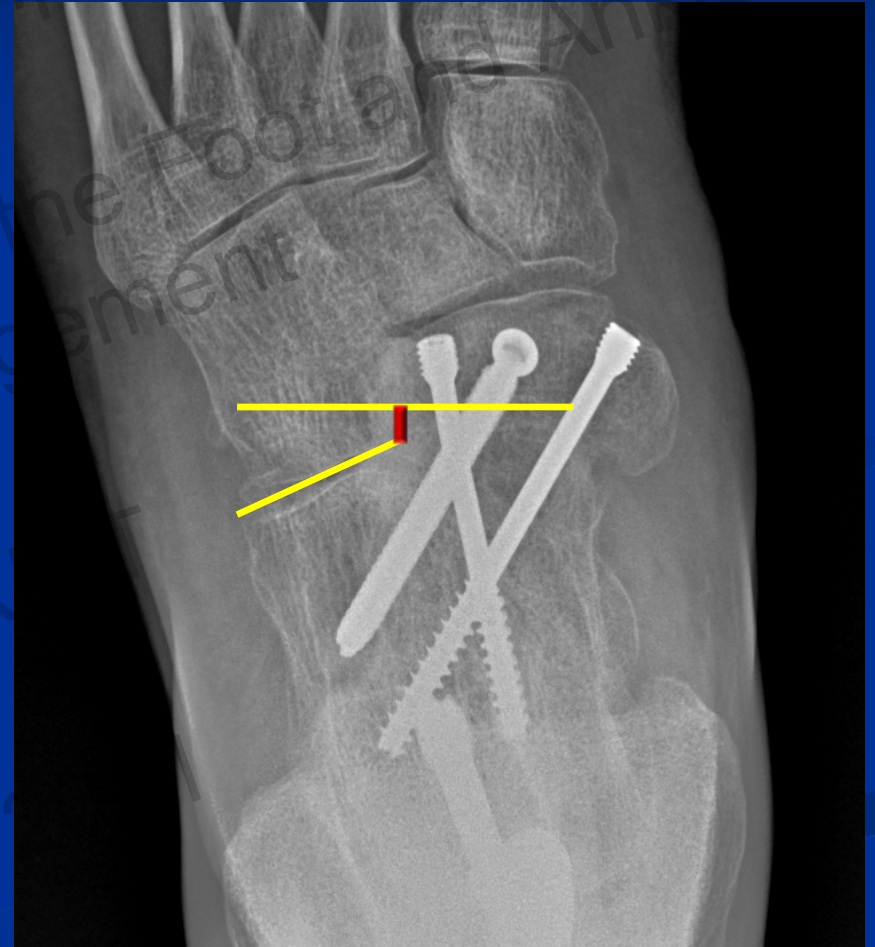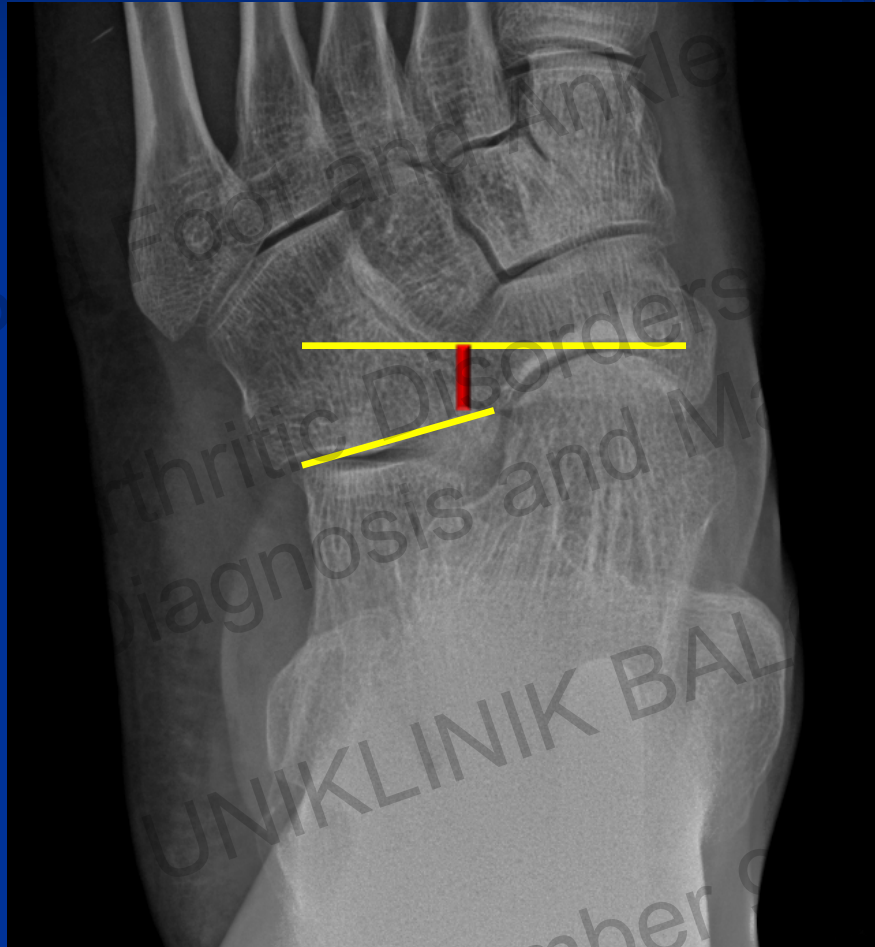Arthritic Disorders of the Foot and Ankle
Diagnosis and Management

UNIKLINIK BALGRIST

September 9th, 2011







September 6, 2014

T-N fixation

- **Dorsolateral screw**

(Campbell et. al. AOFAS Summer Meeting 2010)

- **Superior compression with 1 medial screw and 1 dorsolateral screw**

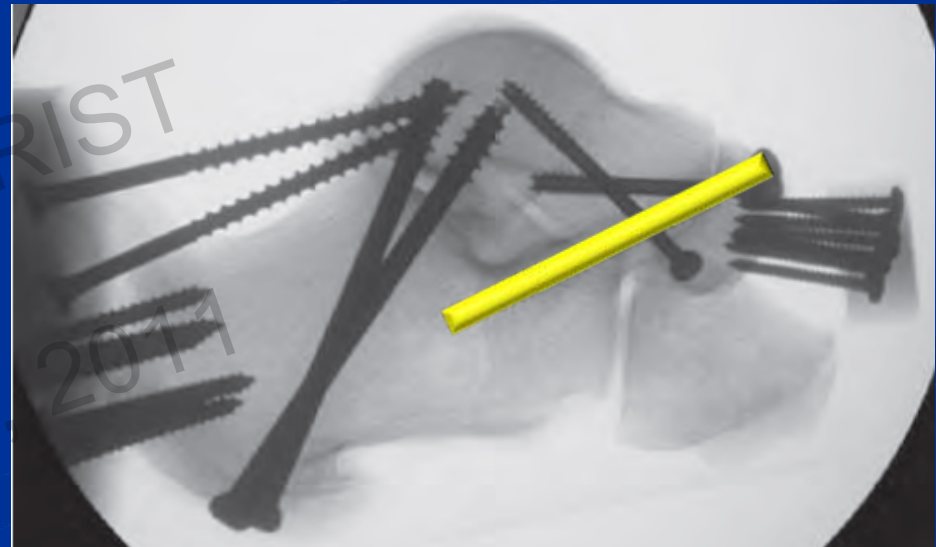
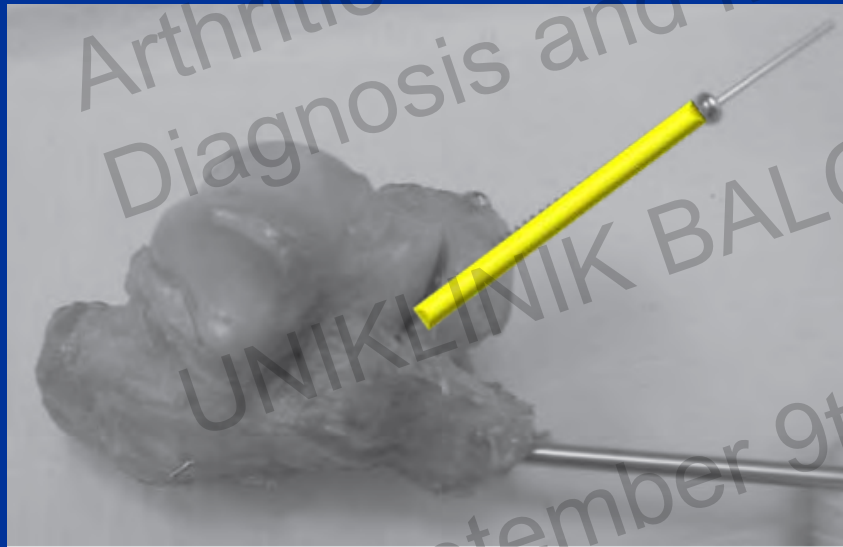
UNIKLINIK BALGRIST

September 9th, 2011

Talonavicular Joint Fixation Using Augmenting Naviculocalcaneal Screw in Modified Double Hindfoot Arthrodesis

Carter D. Kiesau, MD; Connor R. LaRose, MD; Richard R. Glisson, BS; Mark E. Easley, MD; James K. DeOrto, MD
Durham, NC

- **N-C screw increased rigidity to dorsal/plantar and medio-lateral stress**



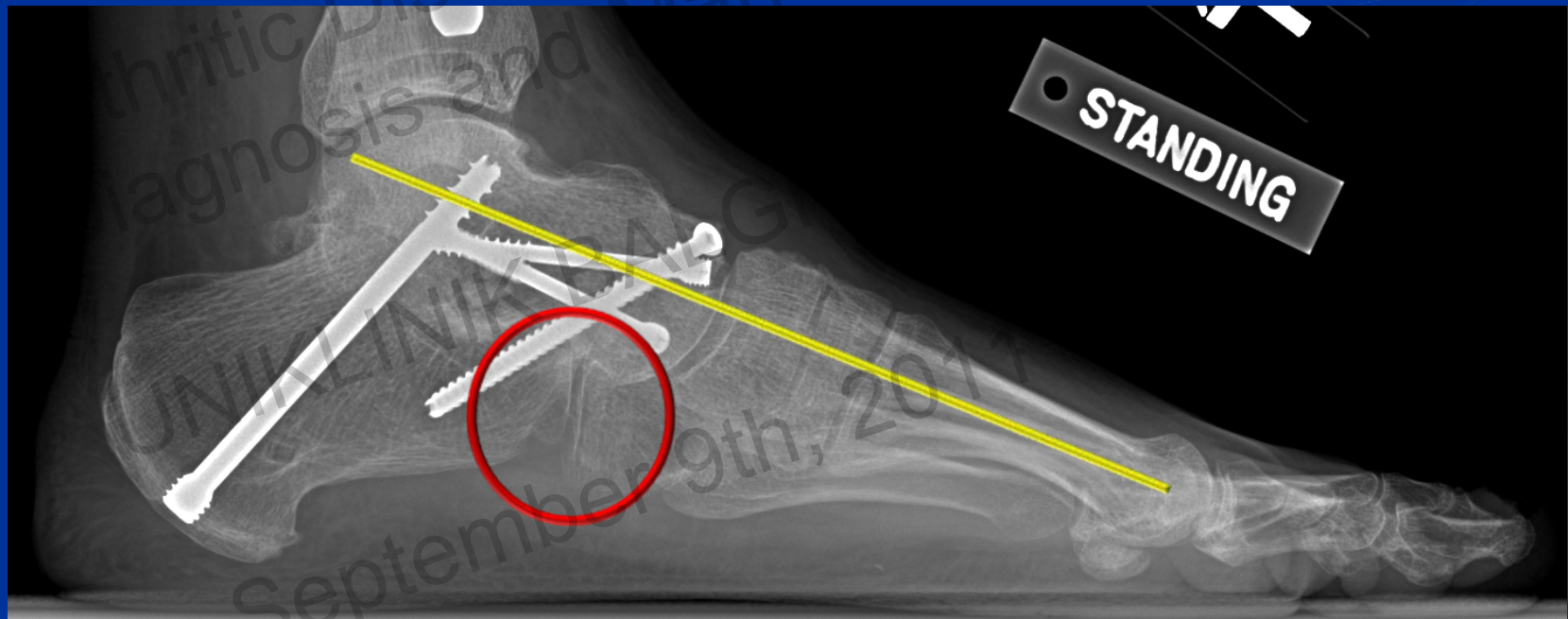
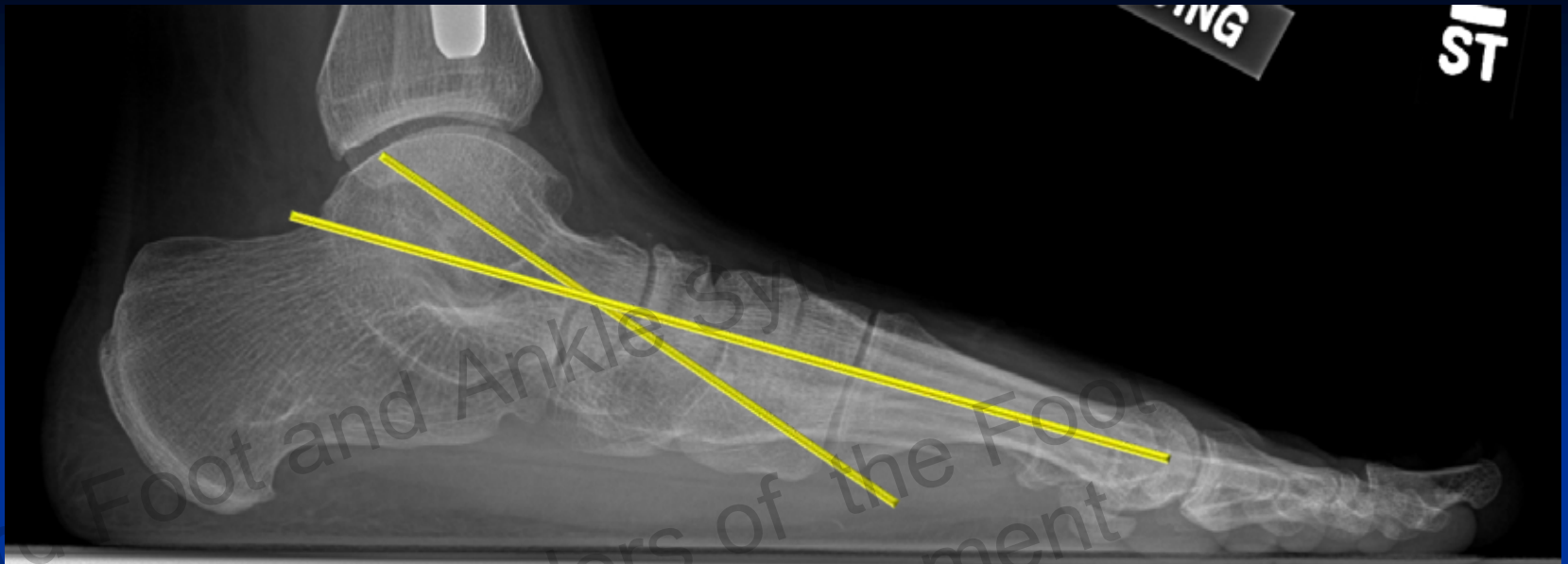
3rd Foot and Ankle Symposium

Arthritic Disorders of the Foot and Ankle
Diagnosis and Management

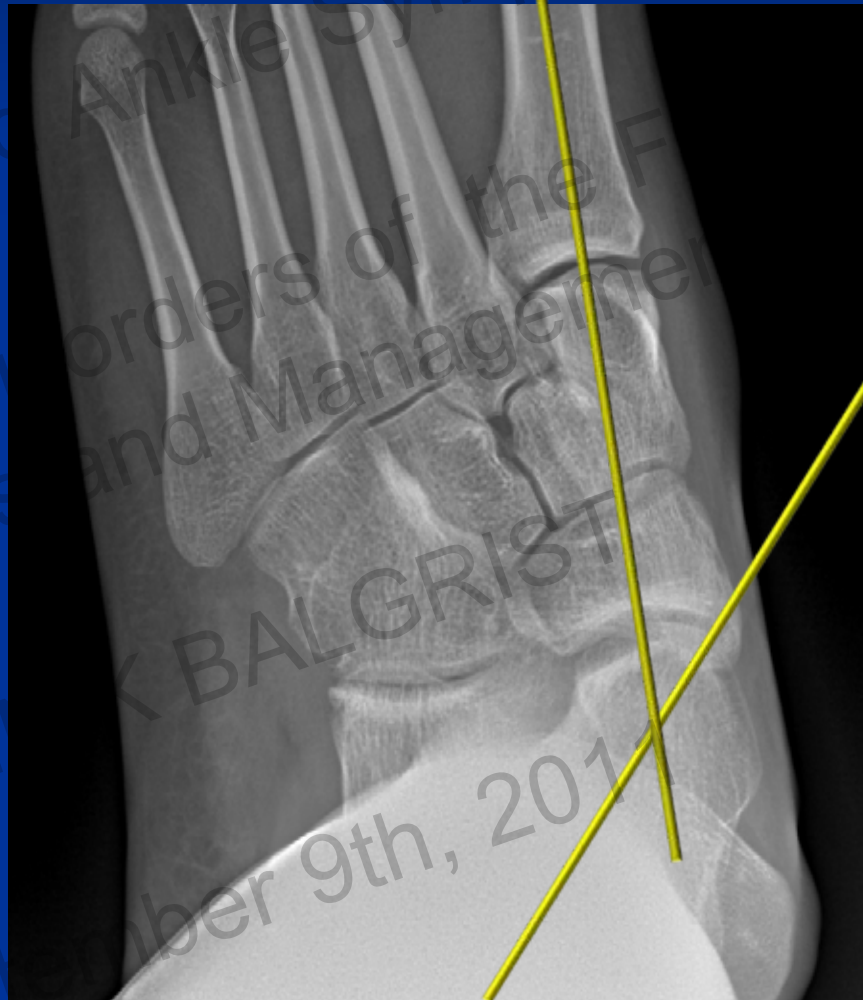UNIKLINIK BALGGRIST

September 9th, 2011



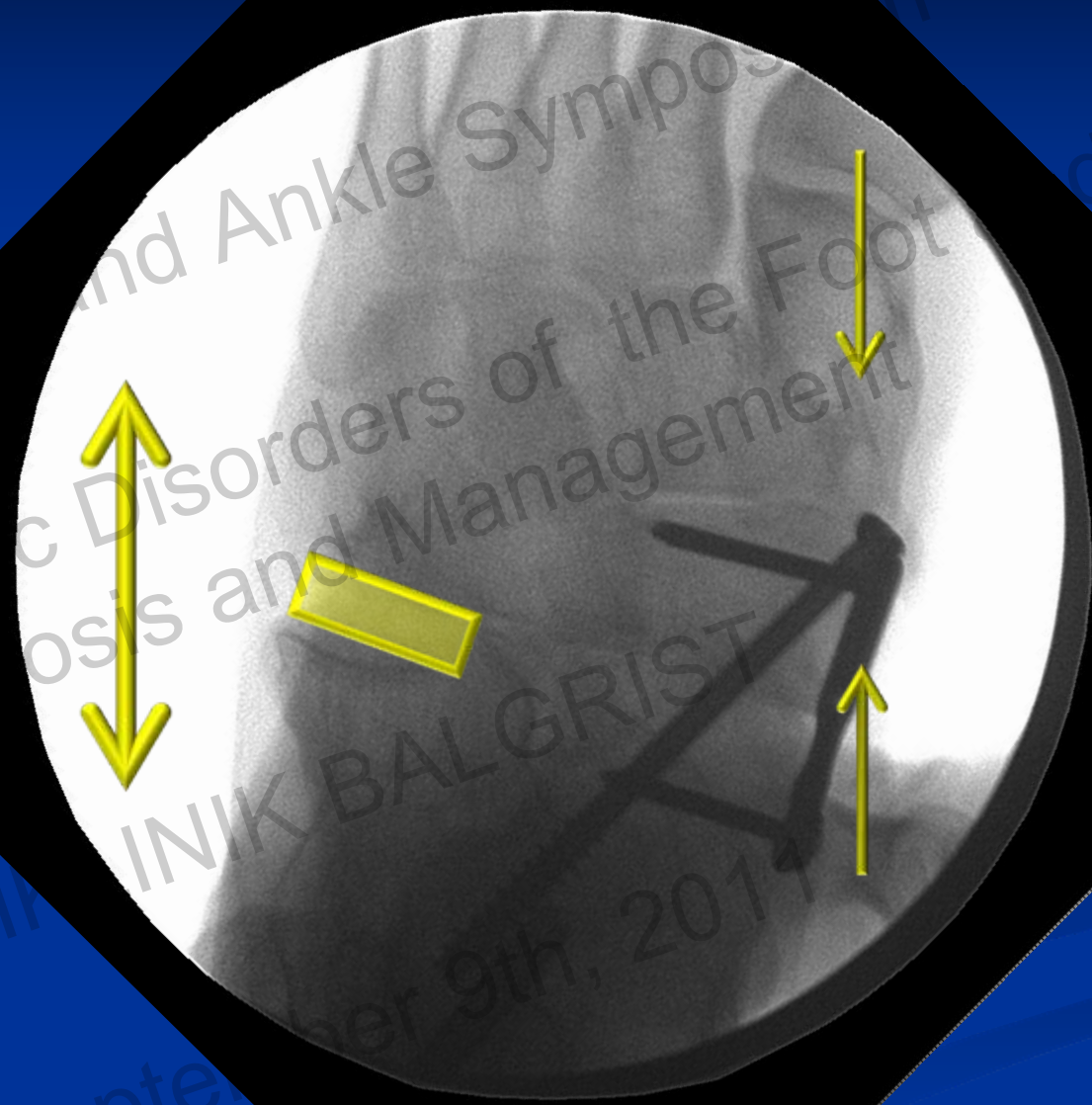


Stiff ST joint – Different approach



kade
1/20/2011
4:28:25 PM

Potts, Clarence
23800664
left foot



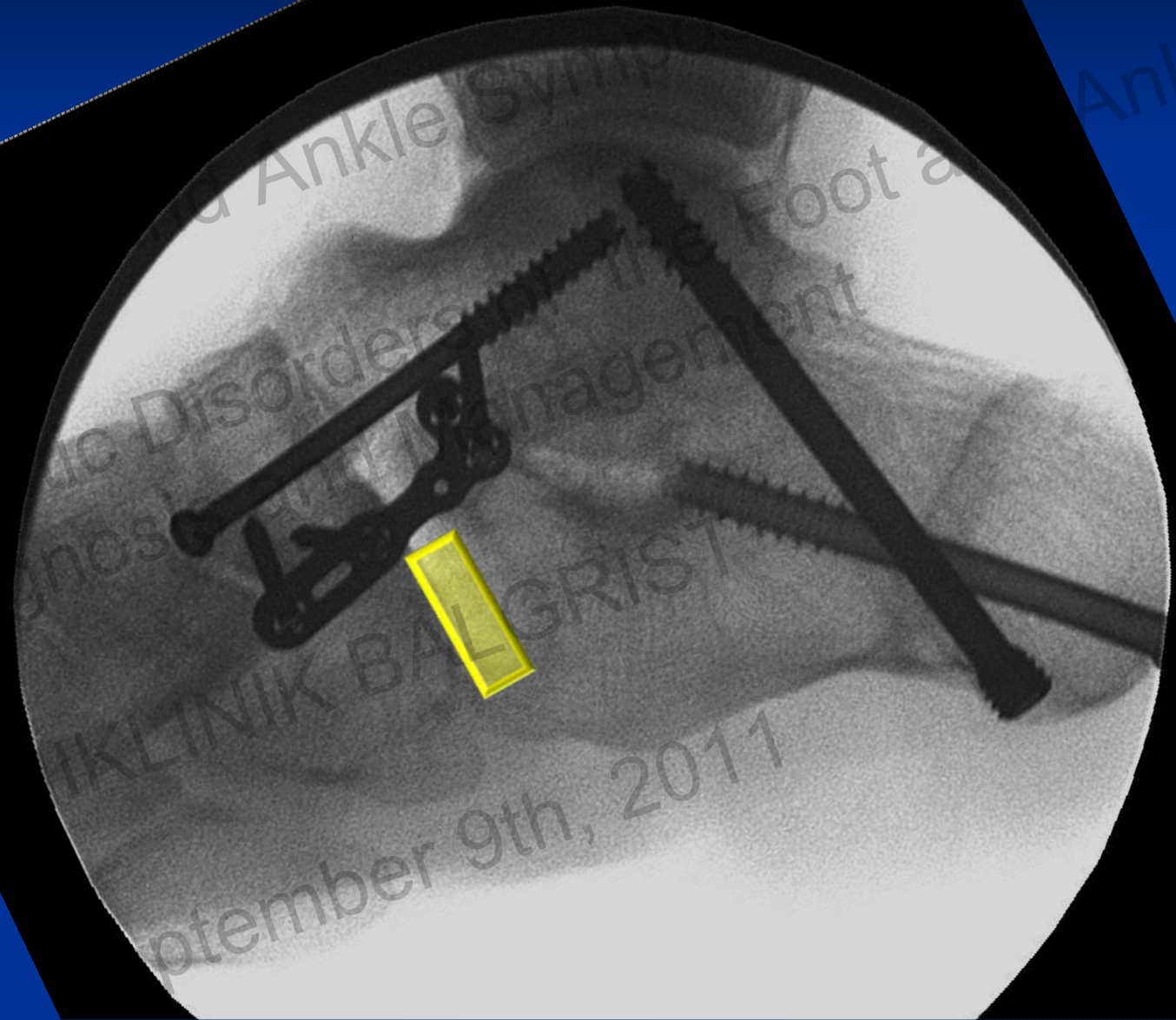
29
6" Mode
50 / 50

FLUOROSCAN
Insight

3rd Foot and Ankle Symposium
Disorders of the Foot
UNIK BALGRIST
September 9th, 2011
d Ankle

FLUOROSCANY
INS
6" Mode
56

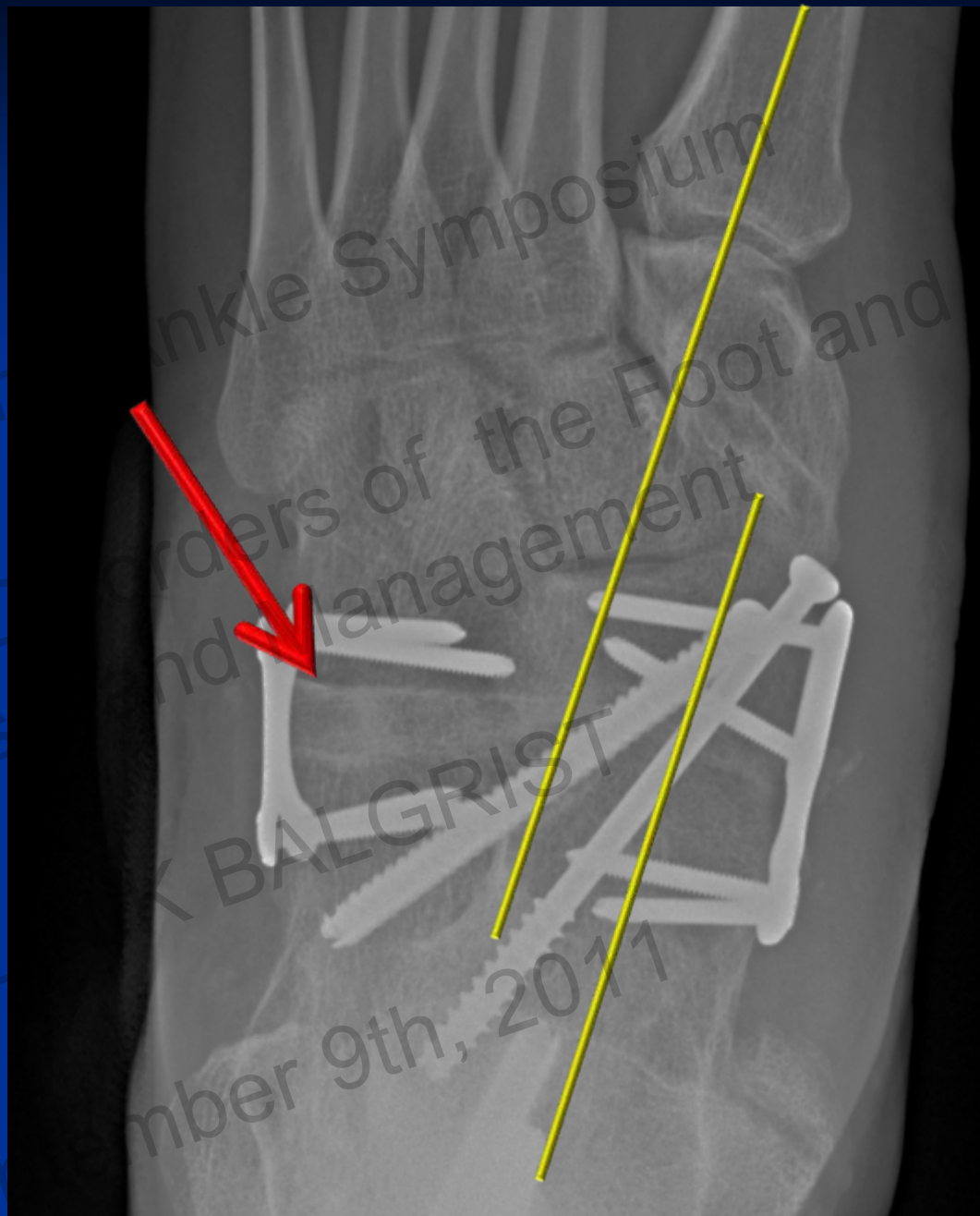
NS: Auto
KV: 61
mA: 0.078
dt: 0.03
0.9623 cGy cm²



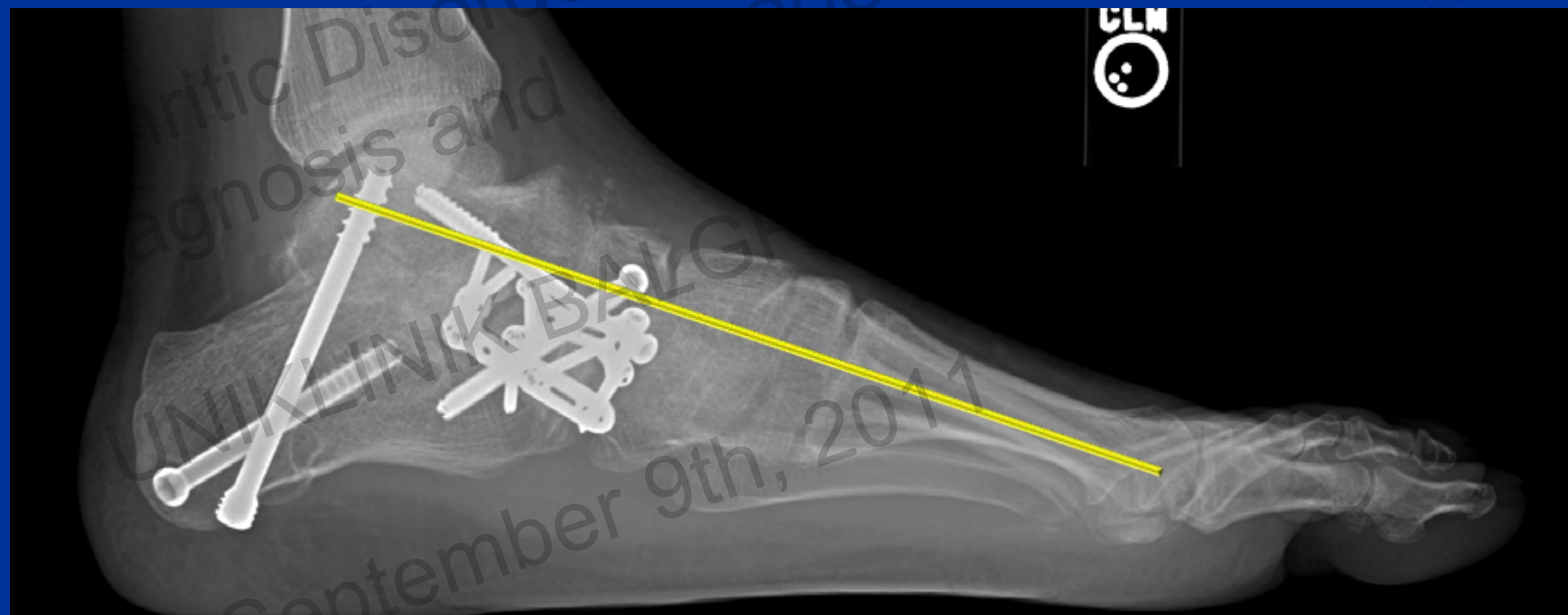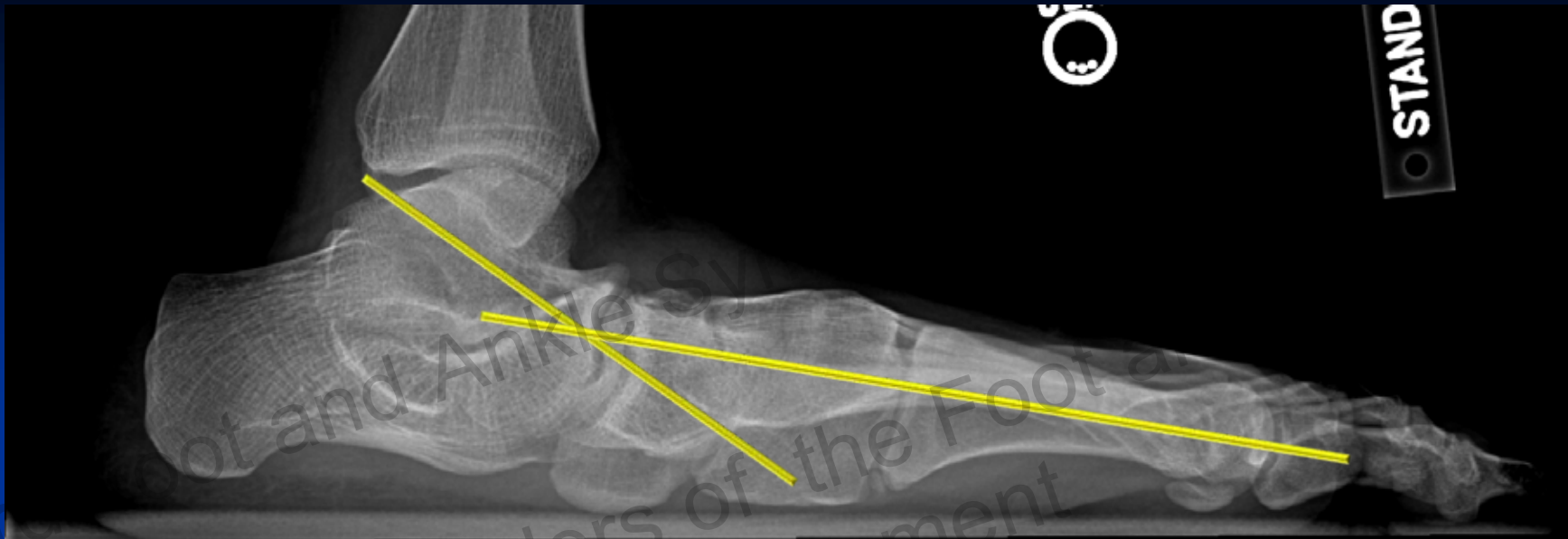September 9th, 2011

ot's, clarence
23800664
left foot

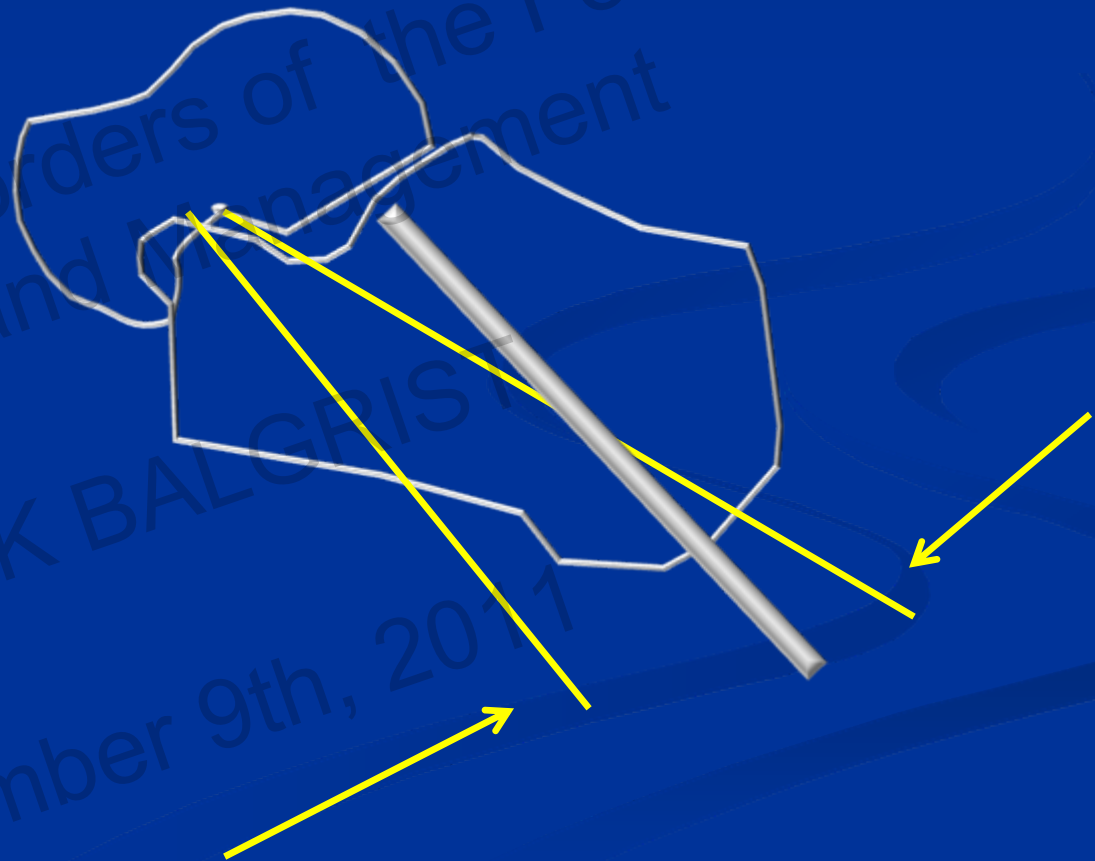
Ankle



3rd Foot and Ankle Symposium
Arthritic Disorders of the Foot and Ankle
Diagnosis and Management
UNIKLINIK BALGRIST
September 9th, 2011



Lamina spreader – Lateral process talus to anterior process calcaneus



3rd Foot and Ankle Symposium
Arthritic Disorders of the Foot and Ankle
Diagnosis and Management
UNIKLINIK BALGRIST
September 9th, 2017

TN reduction aid

- If TN is key to deformity – why not focus reduction there 1st?
- Less powerful tools to force reduction
 - Reliant on Strength of K-wires
 - Reliant on brute strength



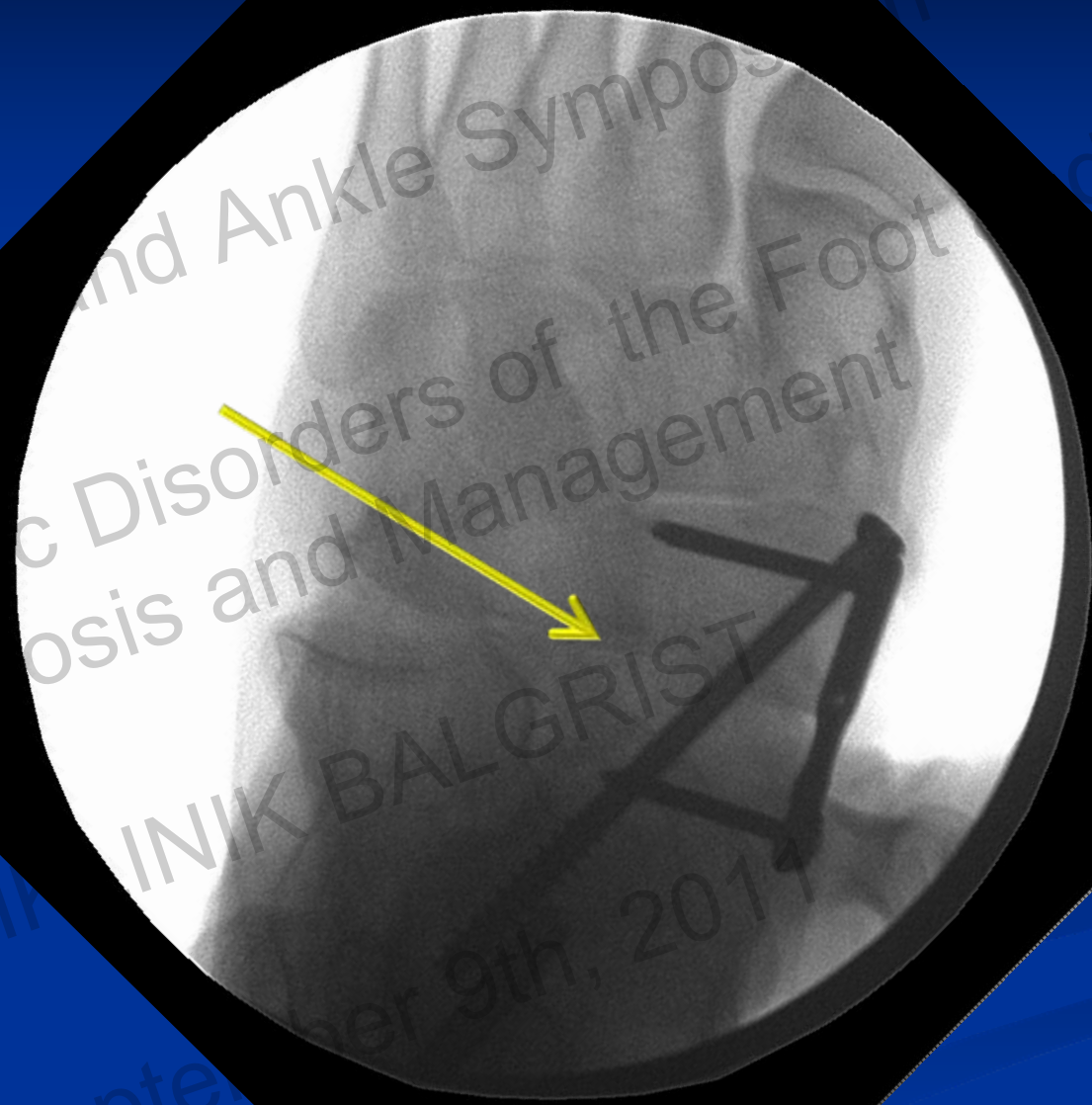Flat Cuts

- **Persistently rigid subtalar joint**
- **Tight lateral soft tissue (peroneals)**
- **Calcaneus does not have to translate distally**
- **Decreases lateral soft tissue tension**



kade
1/20/2011
4:28:25 PM

Potts, Clarence
23800664
left foot



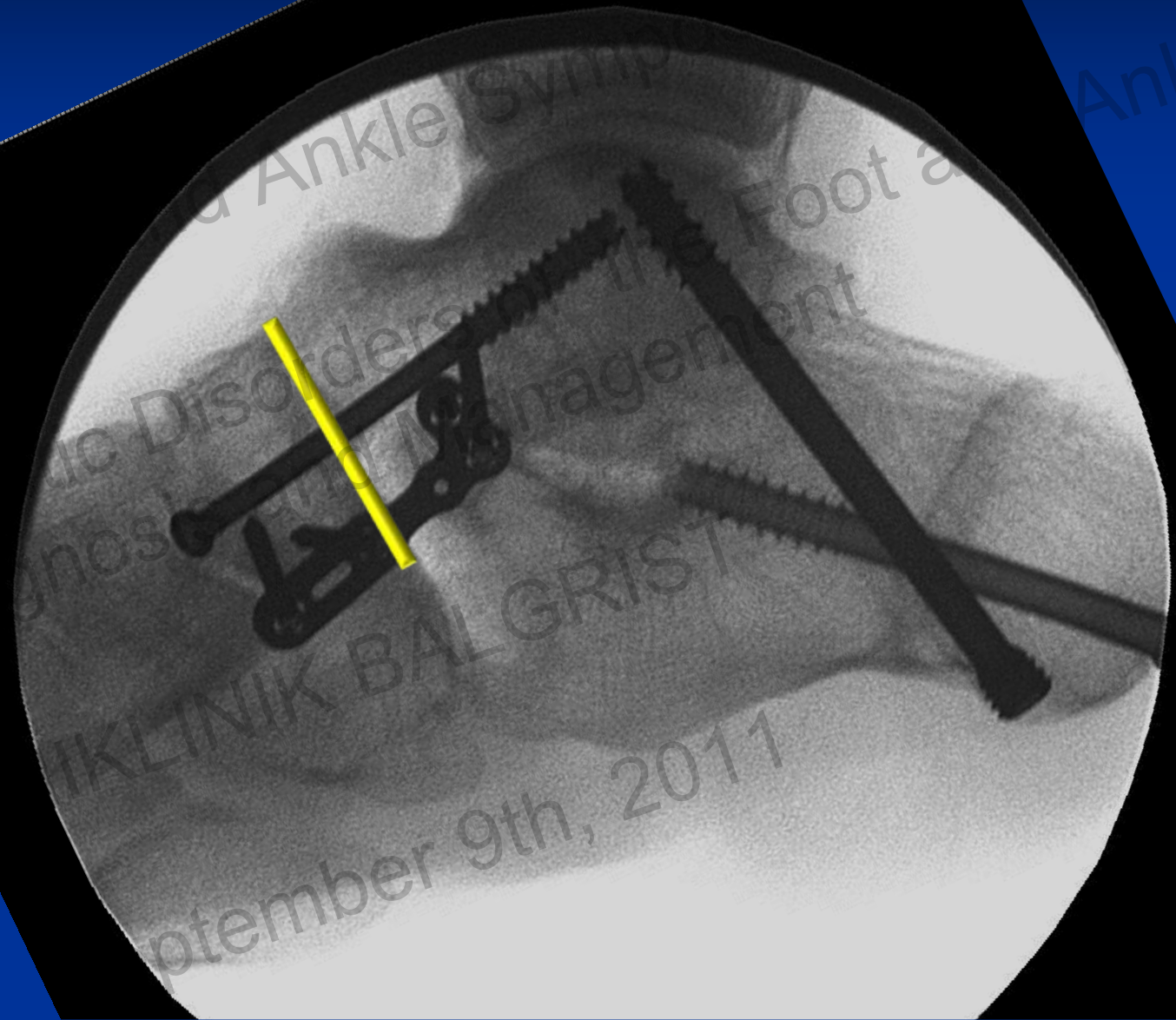
29
6" Mode
50 / 50

FLUOROSCAN
Insight

3rd Foot and Ankle Symposium
Disorders of the Foot
Analysis and Management
UNIK BALGRIST
September 9th, 2011
Foot and Ankle

FLUOROSCANY
INS
6" Mode
56

NS: Auto
KV: 61
mA: 0.078
dt: 0.03
0.9623 cGy cm²

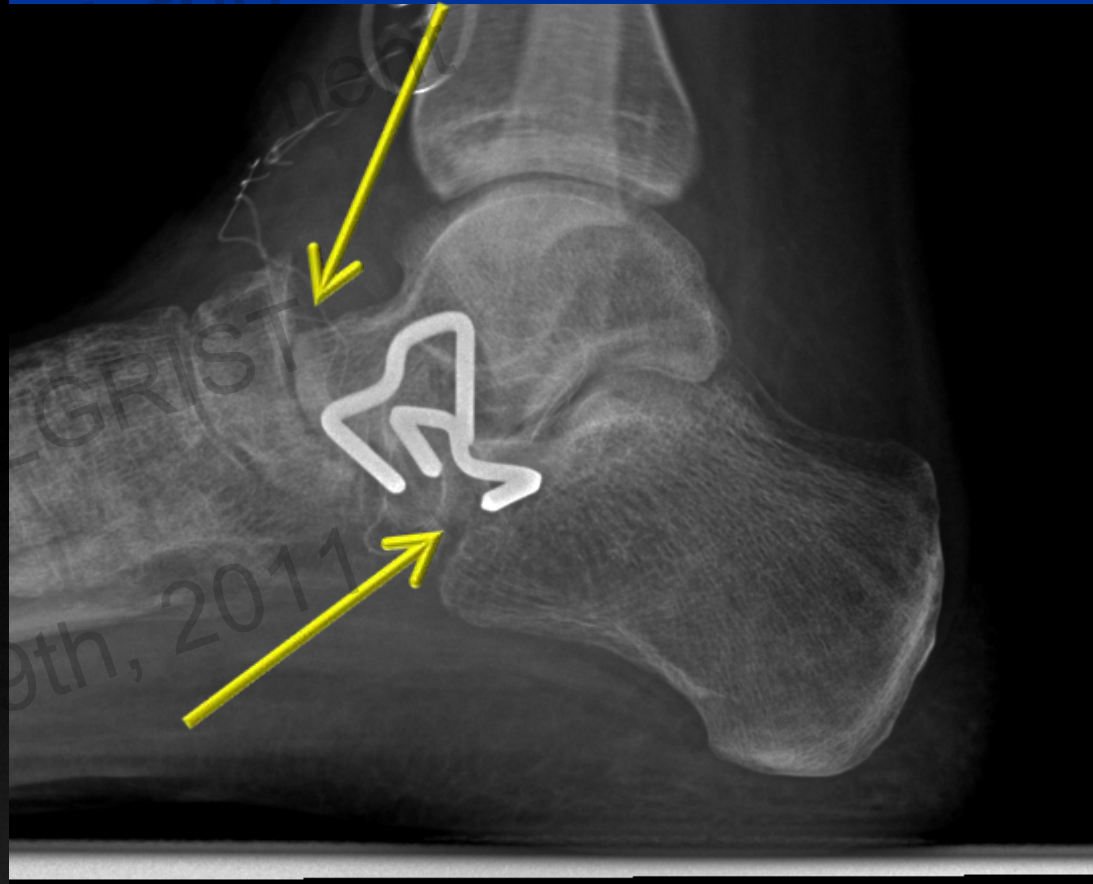
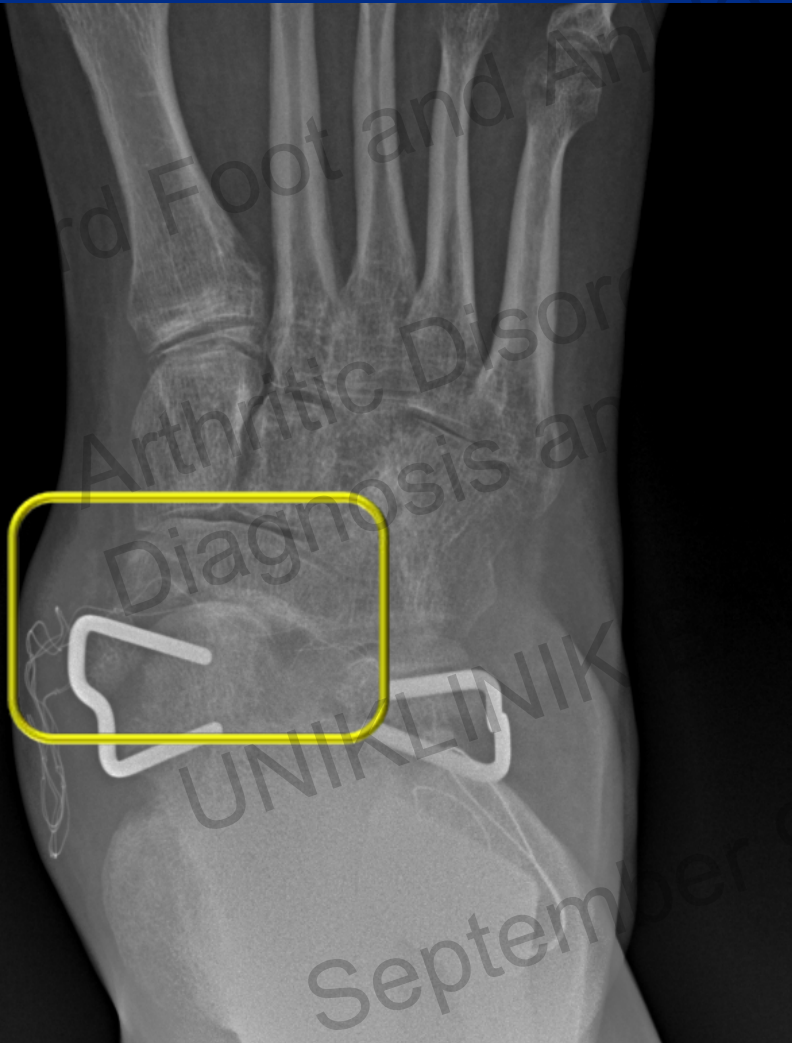


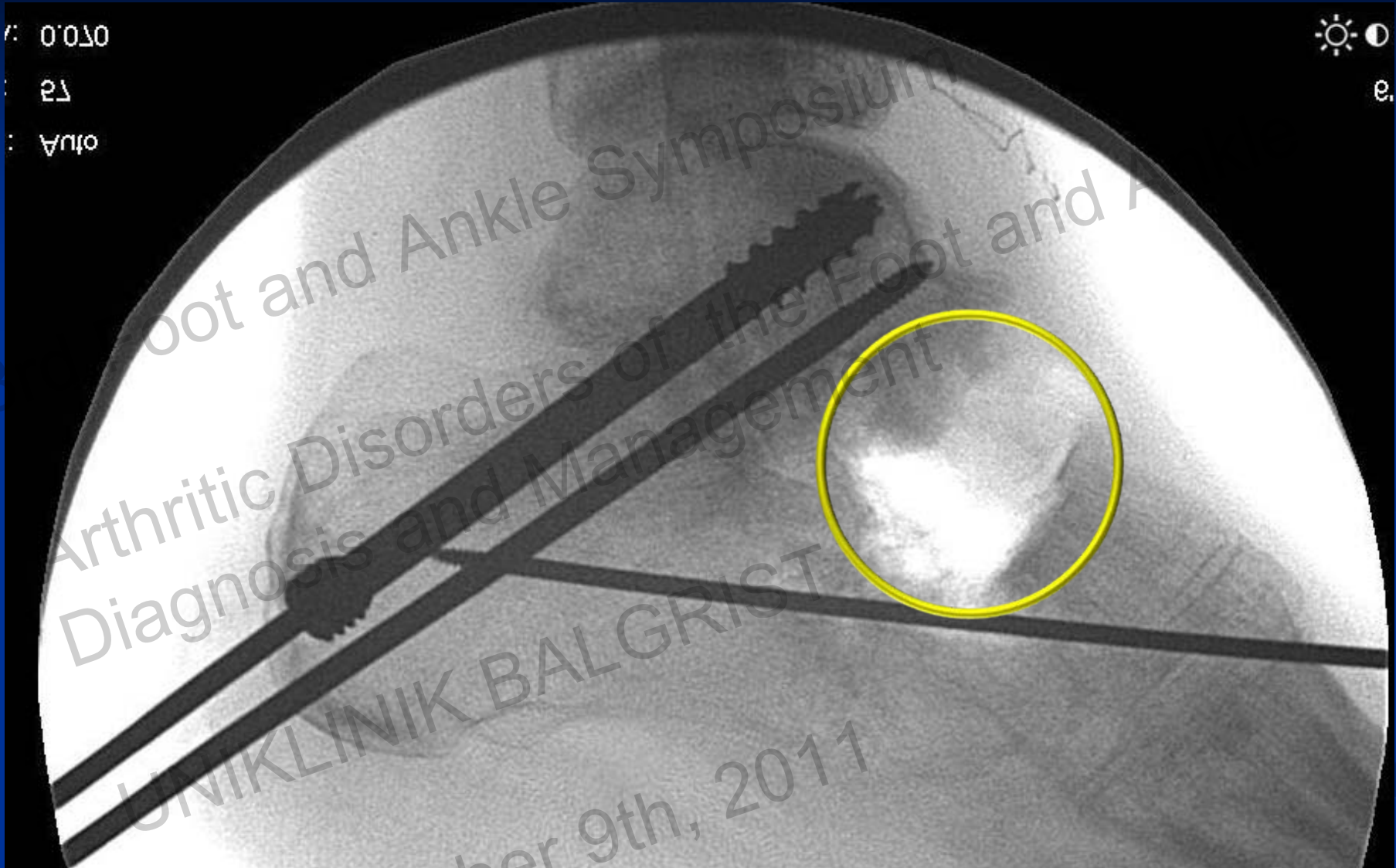
September 9th, 2011

left foot
23800664
otts, darence

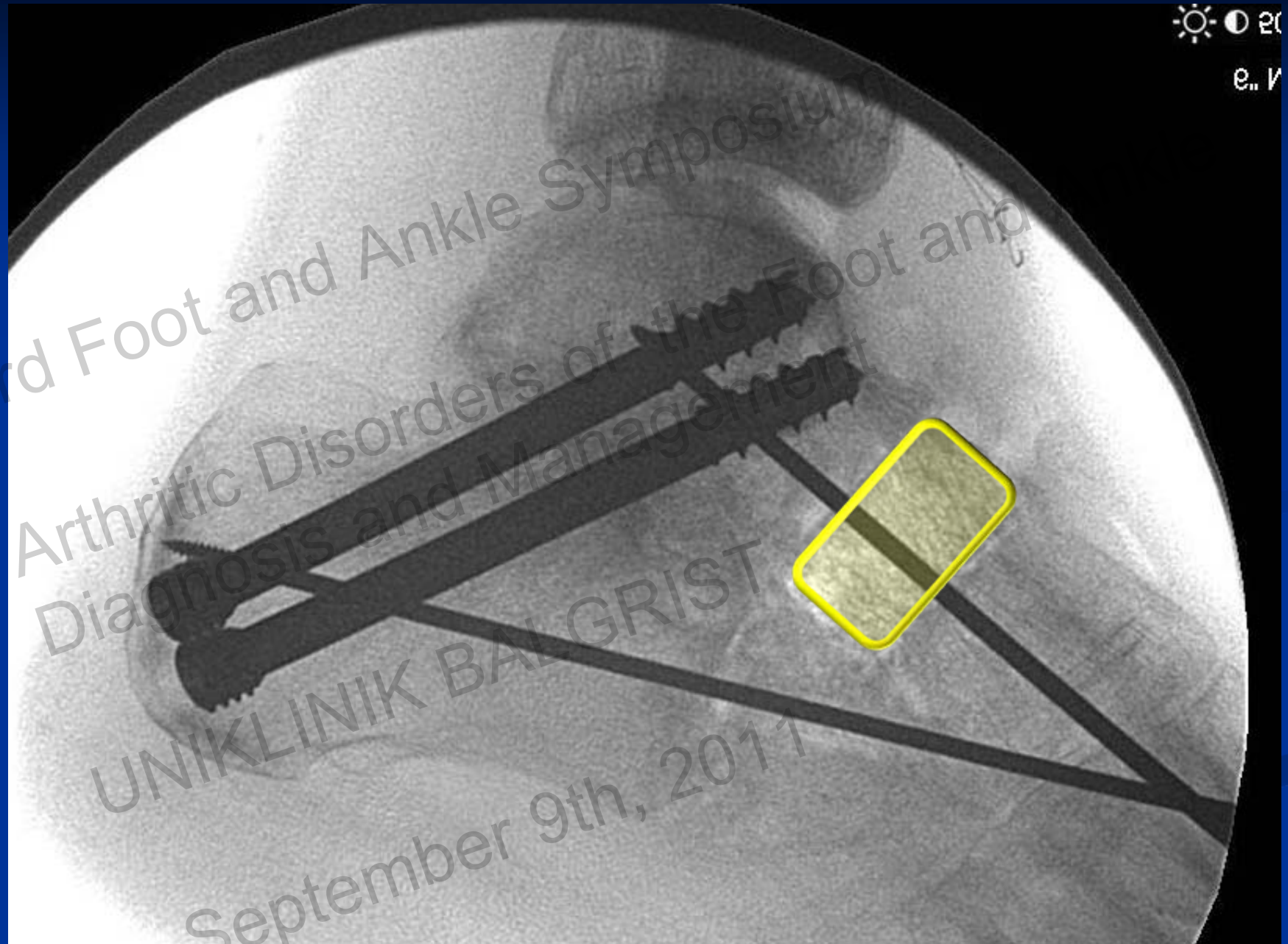
?????

- **Failed TN fusion**
- **Disruption of TN stability**
- **Nonunion Evans Calc Ost**



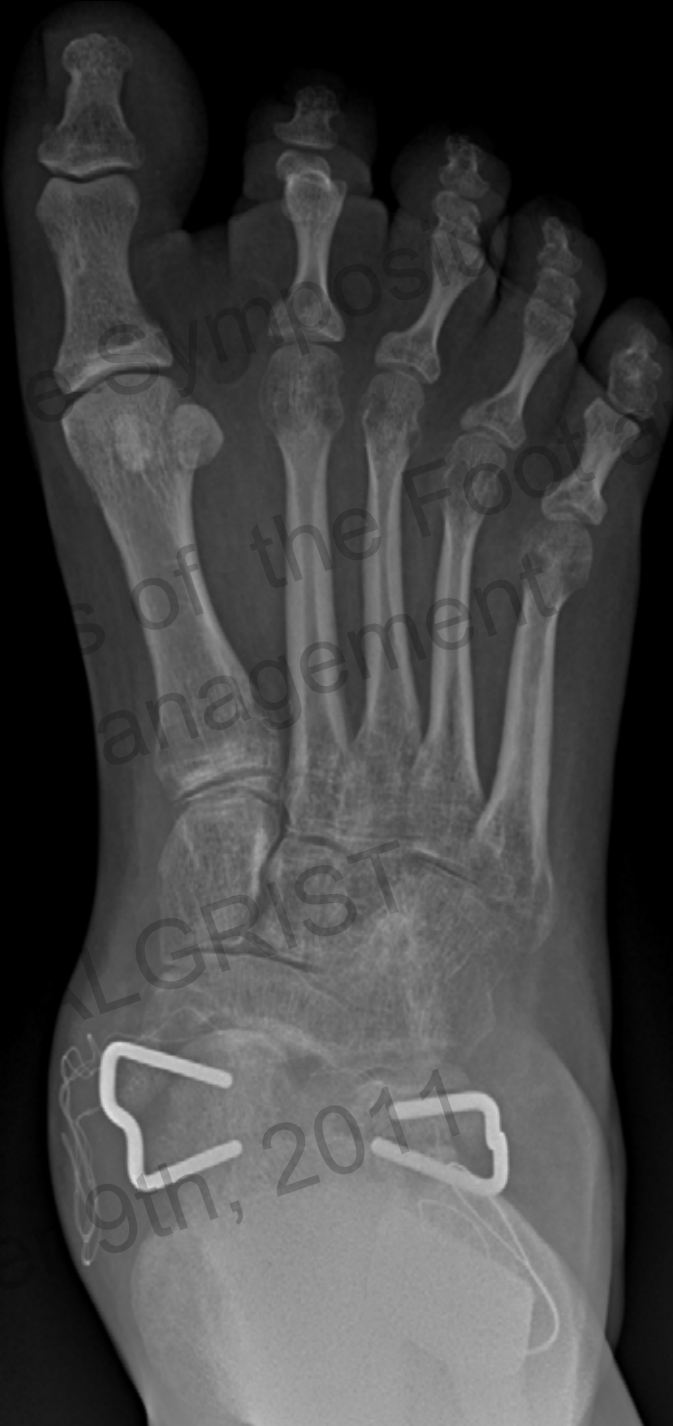

September 9th, 2011



3rd Foot and Ankle Symposium
Arthritic Disorders of the Foot and
Diagnosis and Management
UNIKLINIK BALGRIST
September 9th, 2011

● STANDING



3rd Foot and

Arthritic Disease
Diagnosis

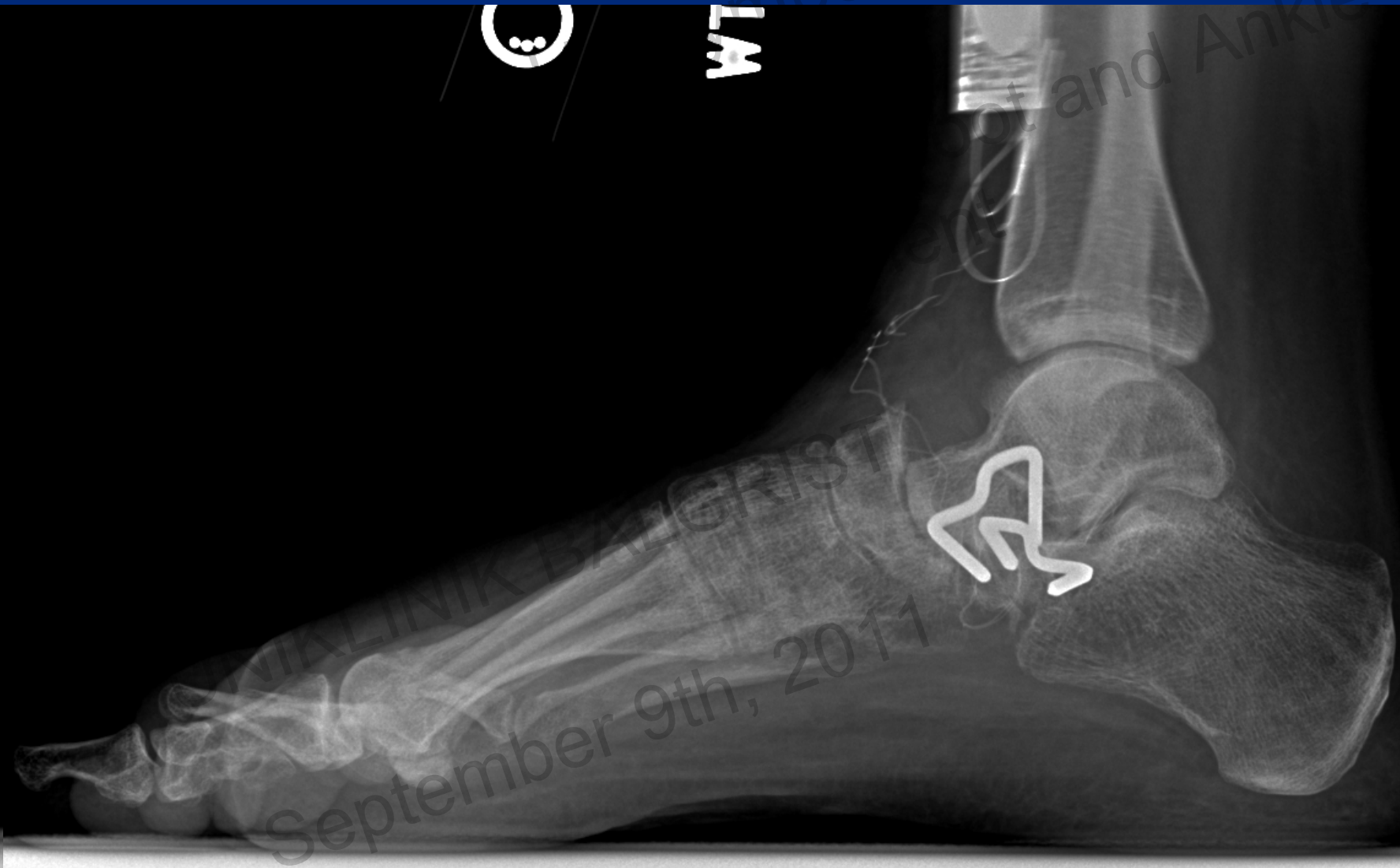UNIKLIN

Sep

© Symposium of the Foot and Ankle
Management

© ALGRIST
9th, 2011

id Ankle



WT

Symposium

Foot and Ankle

VIA LINIK BZL GKRIST

September 9th, 2011

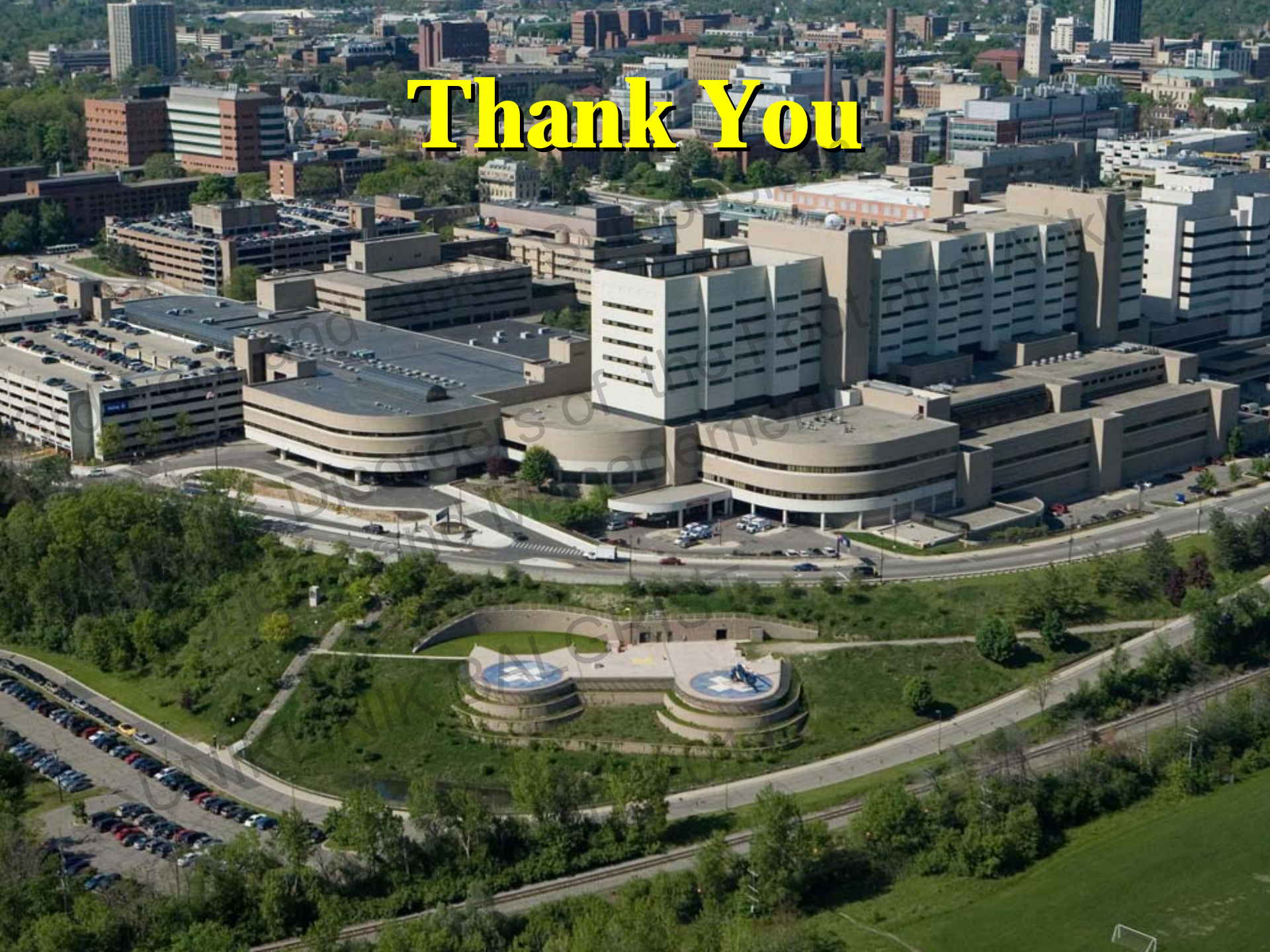Summary

- TN fixation
 - Superior compression
 - 1 medial and 1 dorsolateral screw
 - Superior stability
 - Naviculocuneiform screw

Summary

- Reduction Maneuvers – Mobile ST joint
 - Lamina spreader b/w lateral process talus and anterior process calcaneus
 - Recreate the sinus tarsi
 - K-wires medially
- Reduction Maneuvers – Rigid ST joint
 - Flat cut Talus and Navicular
- C-C joint fusion
 - Arthrosis
 - Required to correct deformity
 - Rigid ST joint (gapping in CC joint)
 - Lengthening required to obtain correction

Thank You



Thank You

