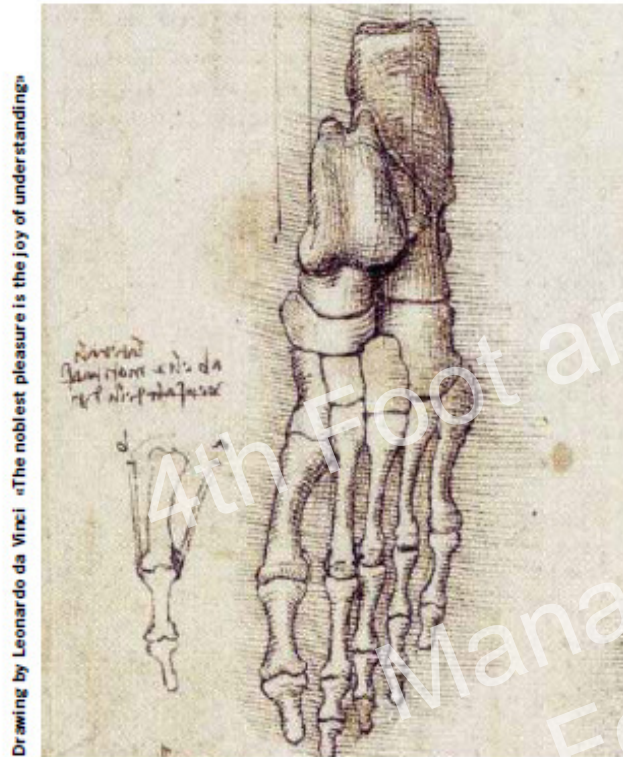
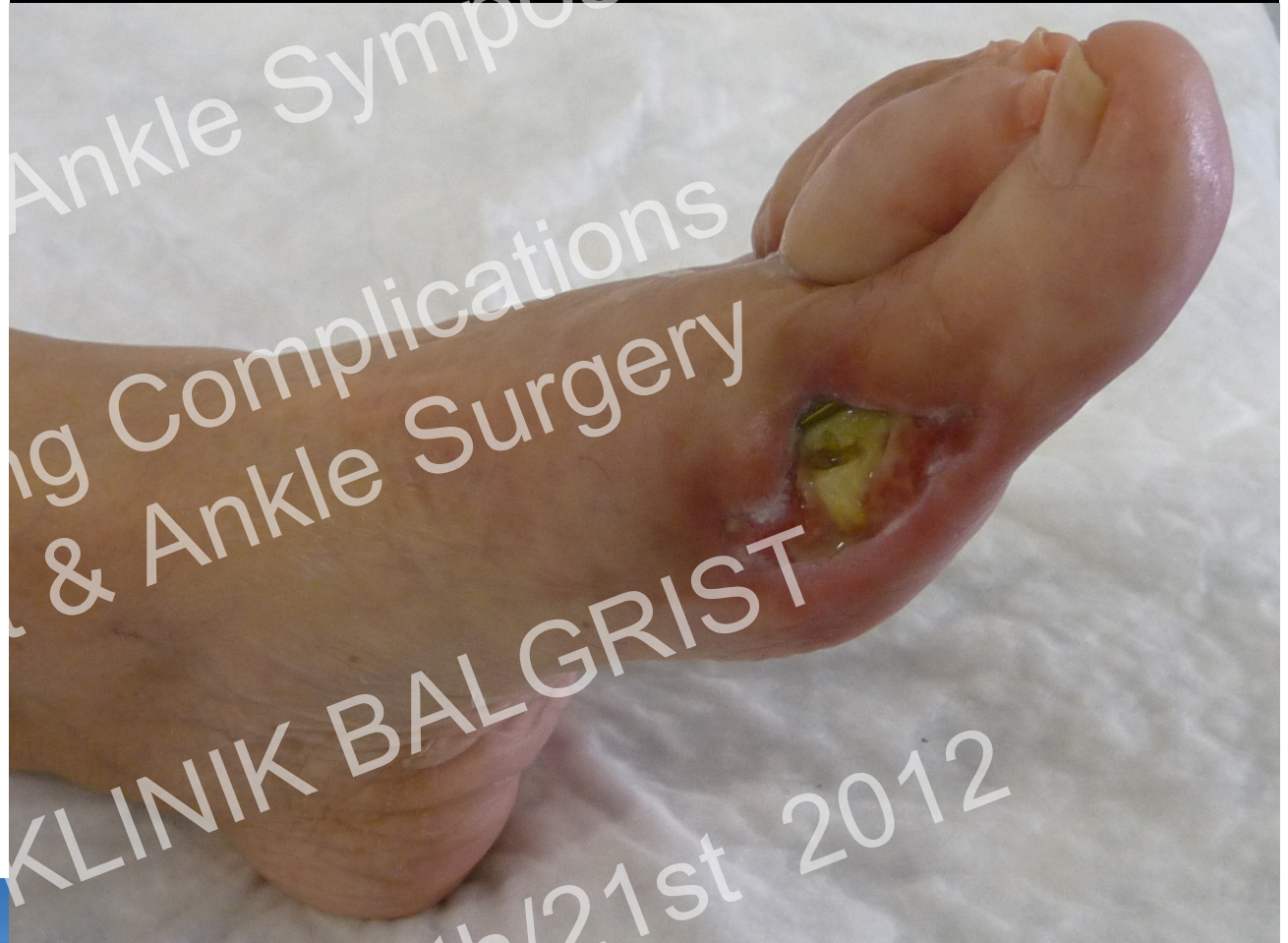
uniklinik
EXPERTISE IN MOTION
balgrist



WHAT IF MP1 FUSION GOES WRONG?



Manuel Monteagudo

Orthopaedic Foot and Ankle Surgery
Hospital Universitario Quirón, Madrid, Spain
mmontyr@yahoo.com

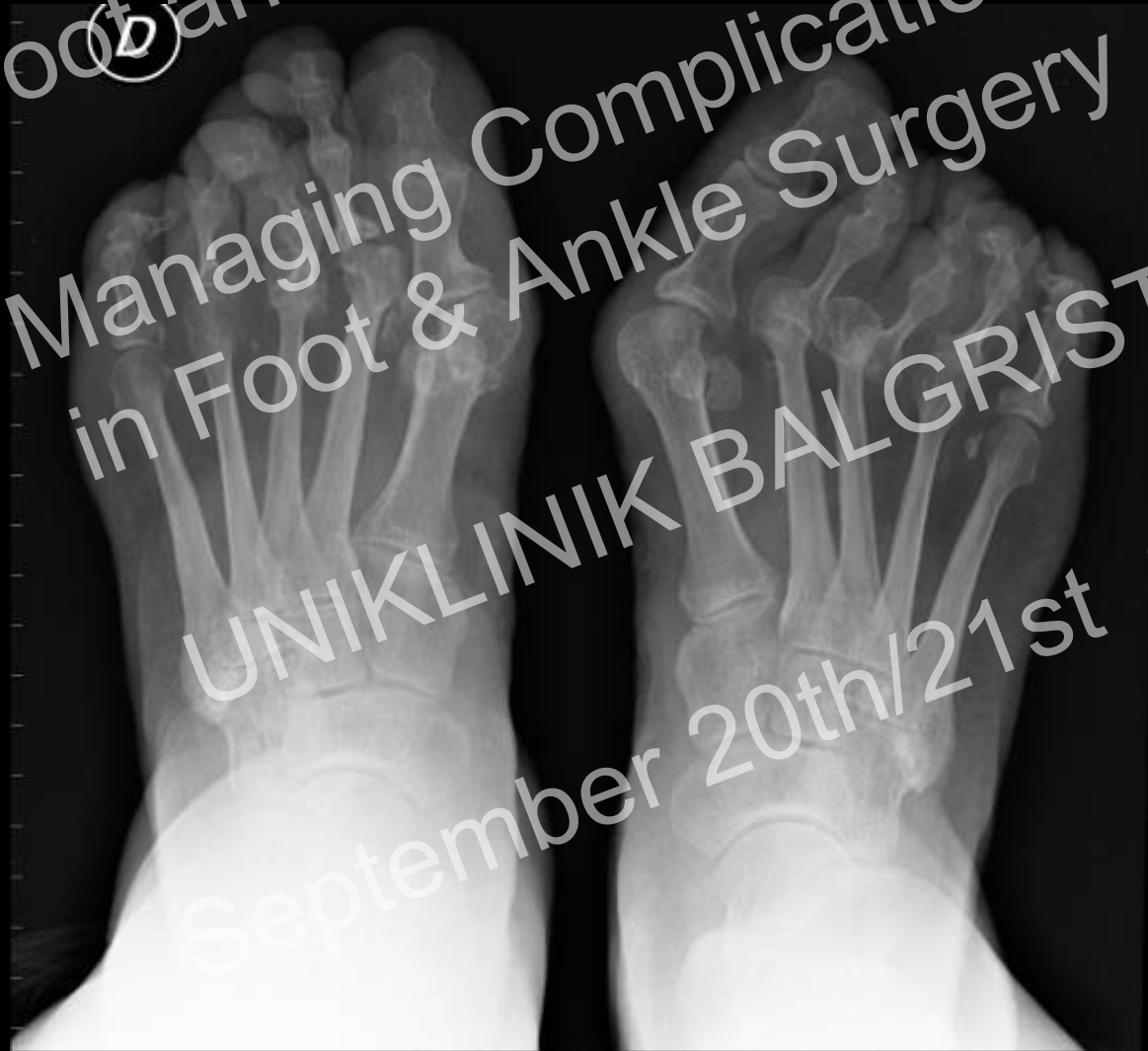

DISCLOSURE OF INTEREST

The author confirms there is no financial or personal relationships with other people or organizations that may have inappropriately influenced this presentation

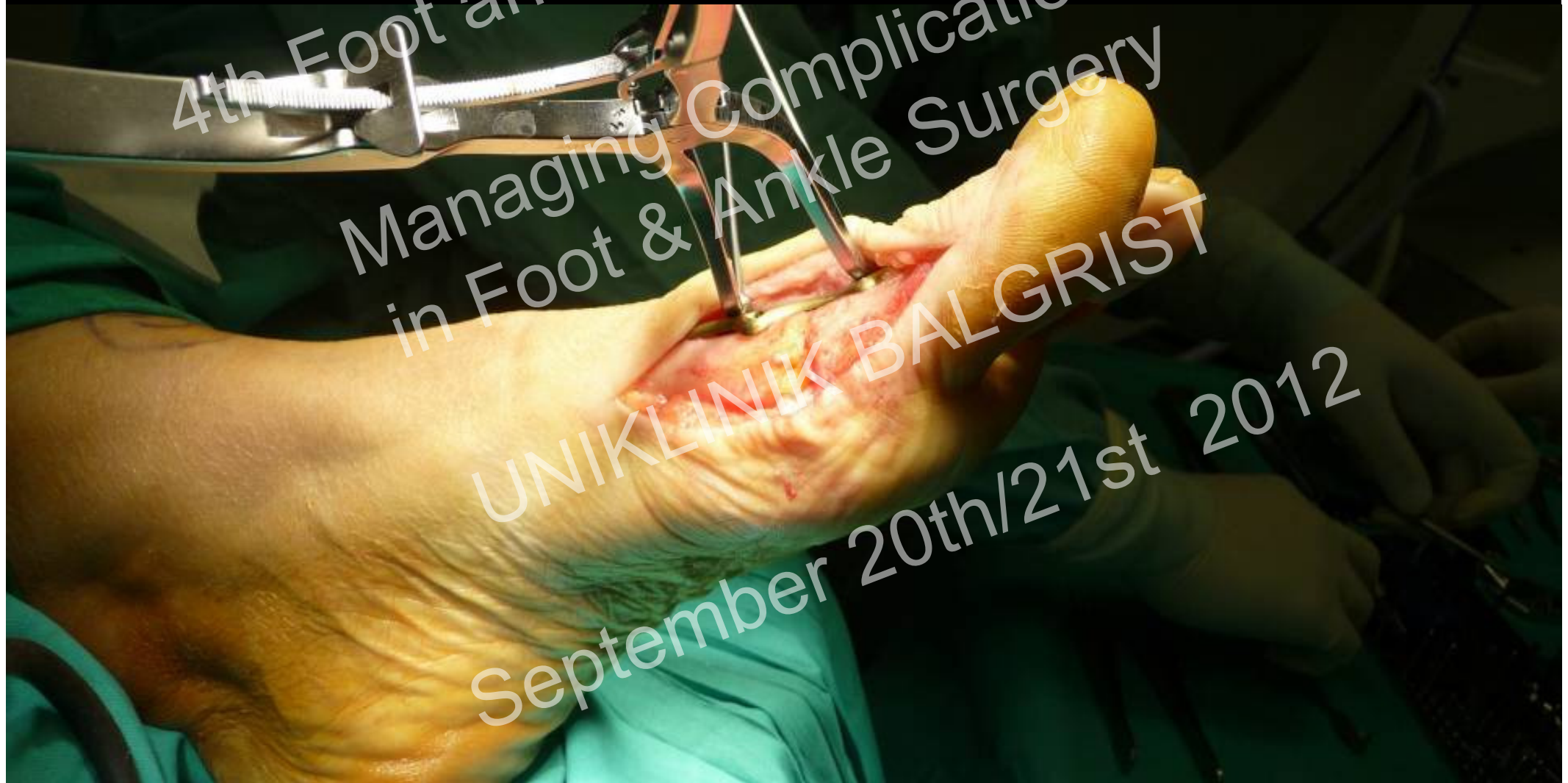MP1 FUSION CONSIDERATIONS ON COMPLICATIONS

FAILED FOREFOOT RECONSTRUCTION



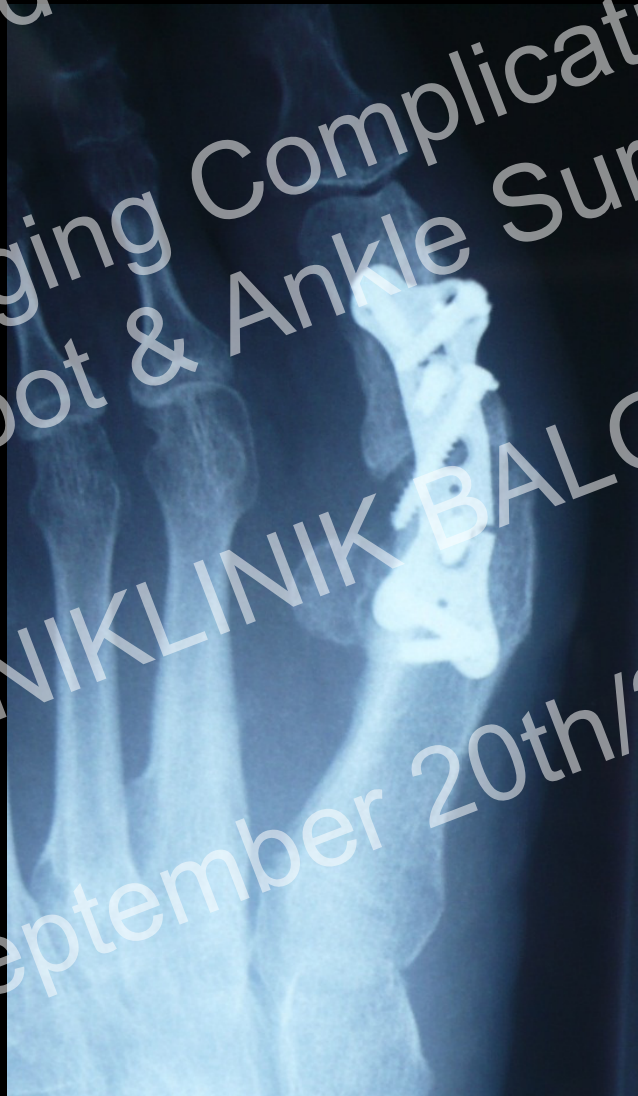MP1 FUSION CONSIDERATIONS ON COMPLICATIONS

MP1 FUSION



MP1 FUSION CONSIDERATIONS ON COMPLICATIONS

FAILED MP1 FUSION



MP1 FUSION CONSIDERATIONS ON COMPLICATIONS

BEWARE OF DEMANDING PATIENTS

PATIENT EXPECTATIONS ...

4th Foot and Ankle Symposium

Managing Complications
in Foot & Ankle Surgery

UNIKLINIK BALGRIST

September 20th/21st 2012

MP1 FUSION CONSIDERATIONS ON COMPLICATIONS

FAILED FOREFOOT SURGERIES

MORE CASES MEAN MORE FAILED CASES

IT IS A SAFE AND RELIABLE PROCEDURE

NOW, IT IS TIME FOR THE DARK SIDE ...

MP1 FUSION

WHAT IS A FAILED MP1 FUSION?

PERSISTENT OR WORSENERD PREOP CONDITION:

PAIN AND DISABILITY

NEUROVASCULAR INJURY

NON SHOEABLE FOREFOOT

INFECTION

SYMPTOMATIC MALUNION

SYMPTOMATIC NONUNION

AMPUTATION

MP1 FUSION COMPLICATIONS AND FAILURE

NEUROVASCULAR

NON INFECTIVE WOUND PROBLEMS

MALUNION

INFECTION

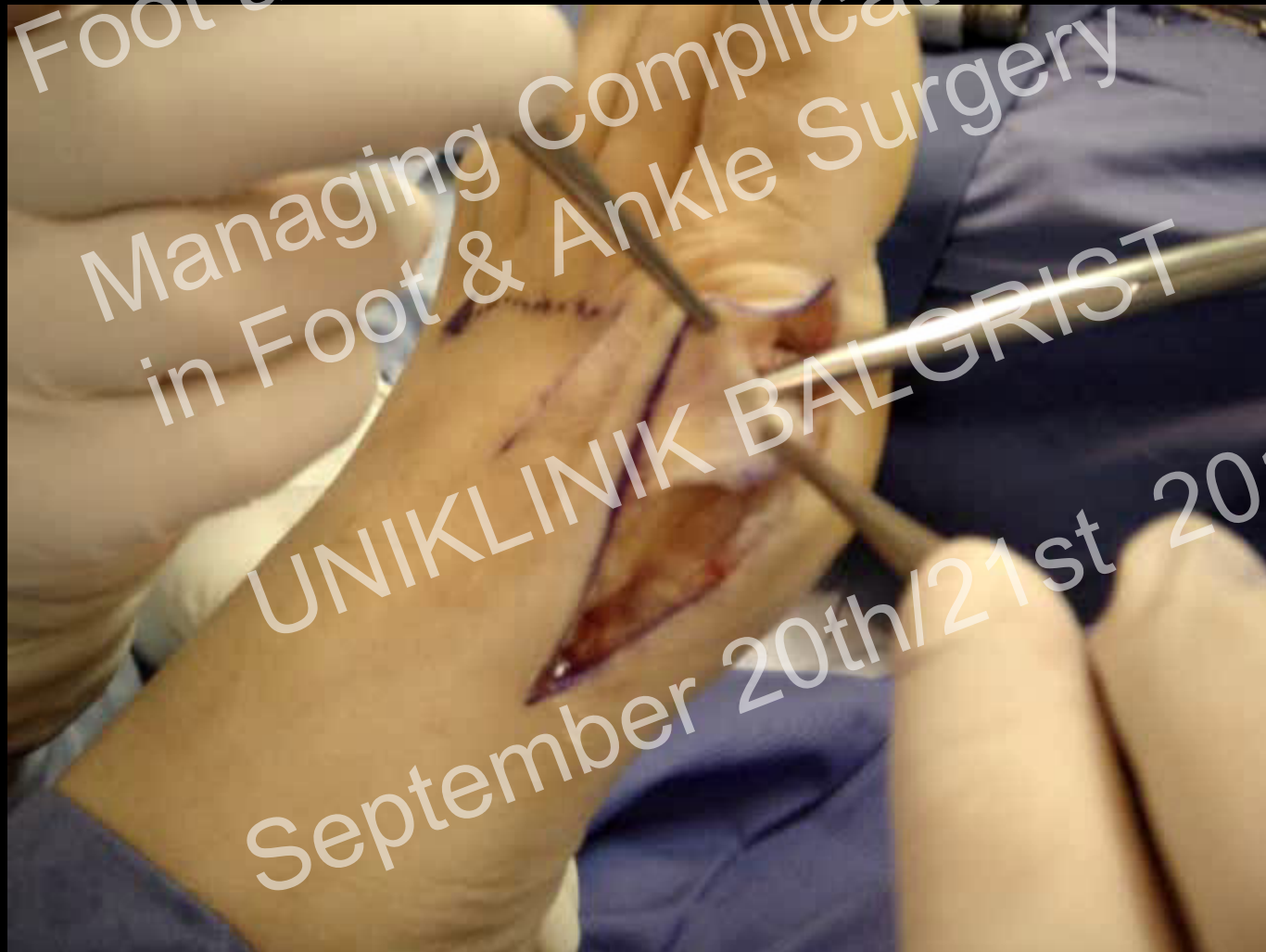NONUNION

AMPUTATION

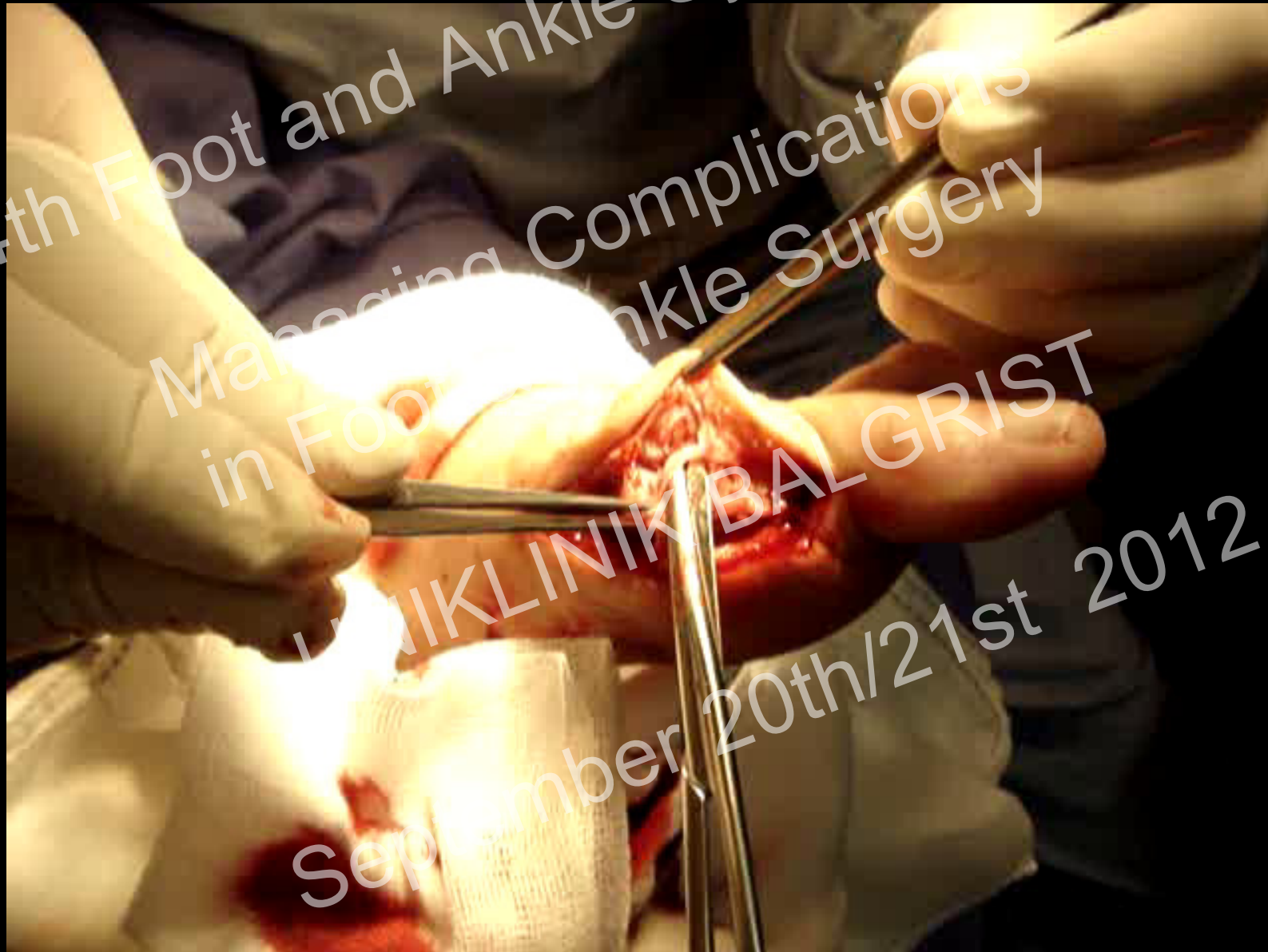METALWORK - IMPLANT

NEUROVASCULAR

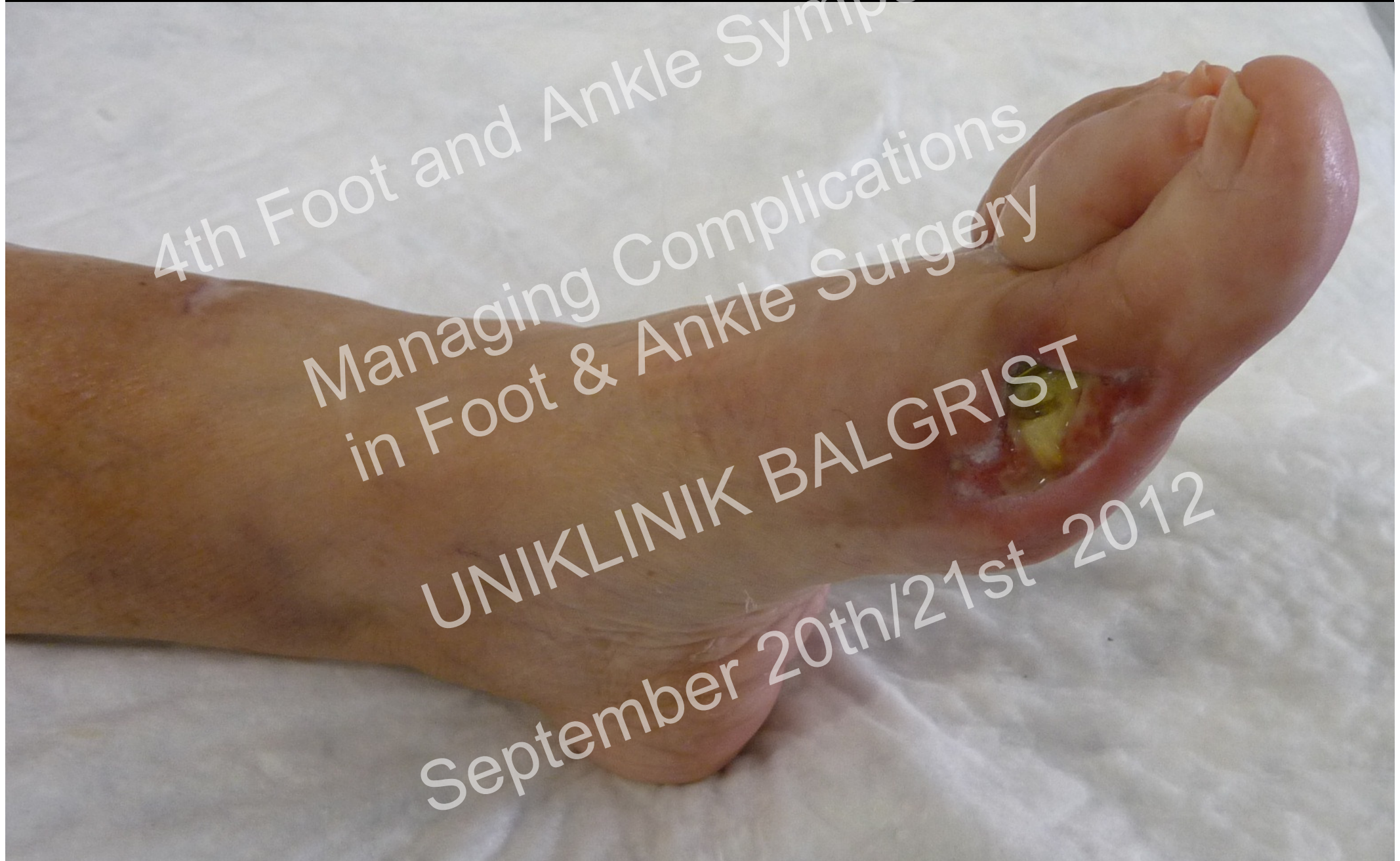DORSAL CUTANEOUS NERVE AND FIBROSIS



NEUROVASCULAR CAUSES AND SOLUTIONS



NON-INFECTIVE WOUND PROBLEMS



4th Foot and Ankle Symposium
Managing Complications
in Foot & Ankle Surgery
UNIKLINIK BALGRIST
September 20th/21st 2012

NON-INFECTIVE WOUND PROBLEMS

CAUSES

DIABETES AND RHEUMATOID ARTHRITIS

PREVIOUS SCARS

VASCULAR STATUS

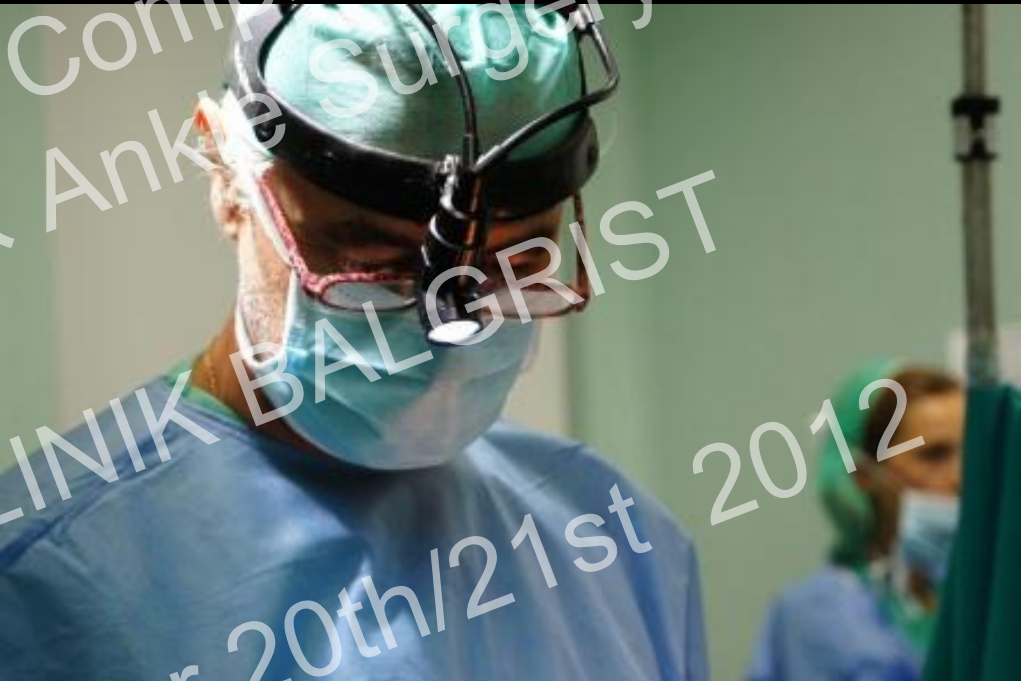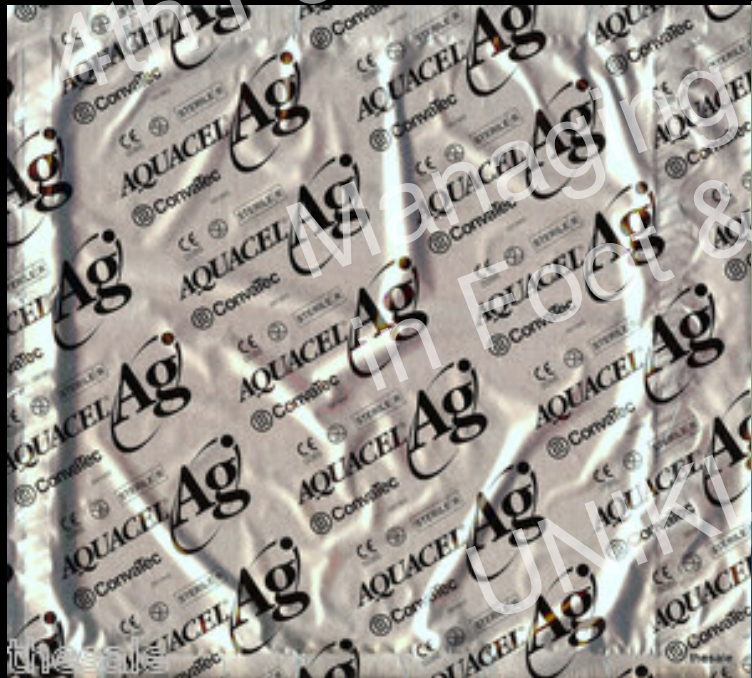
SMOKING

...

UNIKLINIK BALGRIST
September 20th/21st 2012

NON-INFECTIVE WOUND PROBLEMS SOLUTIONS

SILVER DRESSINGS



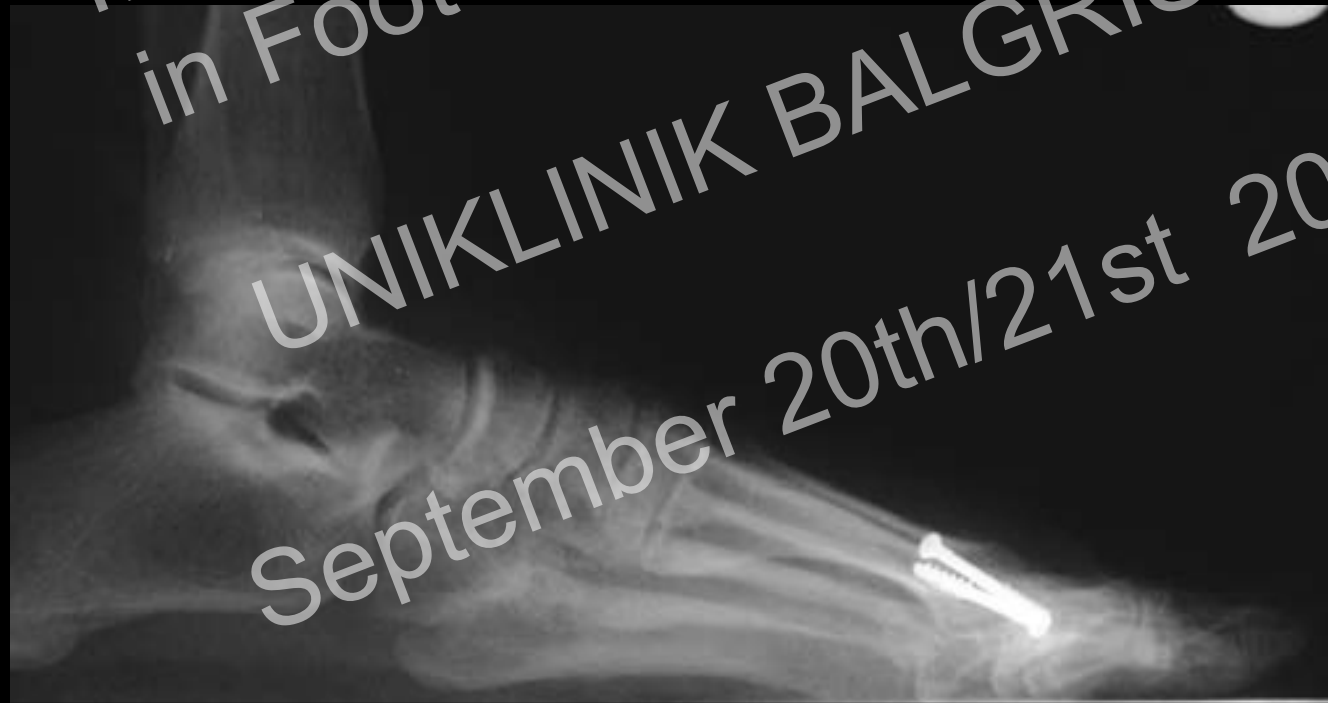BE PATIENT... IT MAY TAKE MONTHS
TALK TO PLASTIC SURGEONS IF DOUBTS

MALUNION

SAGITAL PLANE

HALLUX OVERLY PLANTARFLEXED

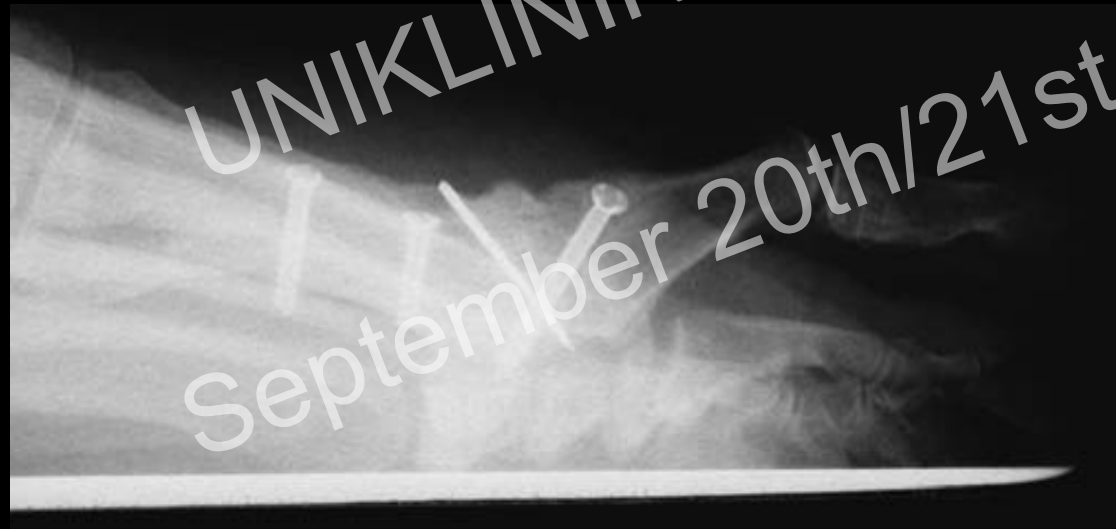WILL FUNCTION AS AN HALLUX RIGIDUS



MALUNION

SAGITAL PLANE

HALLUX OVERLY DORSIFLEXED
MAY HAVE NORMAL FUNCTION BUT DIFFICULTIES
WITH SHOEWEAR

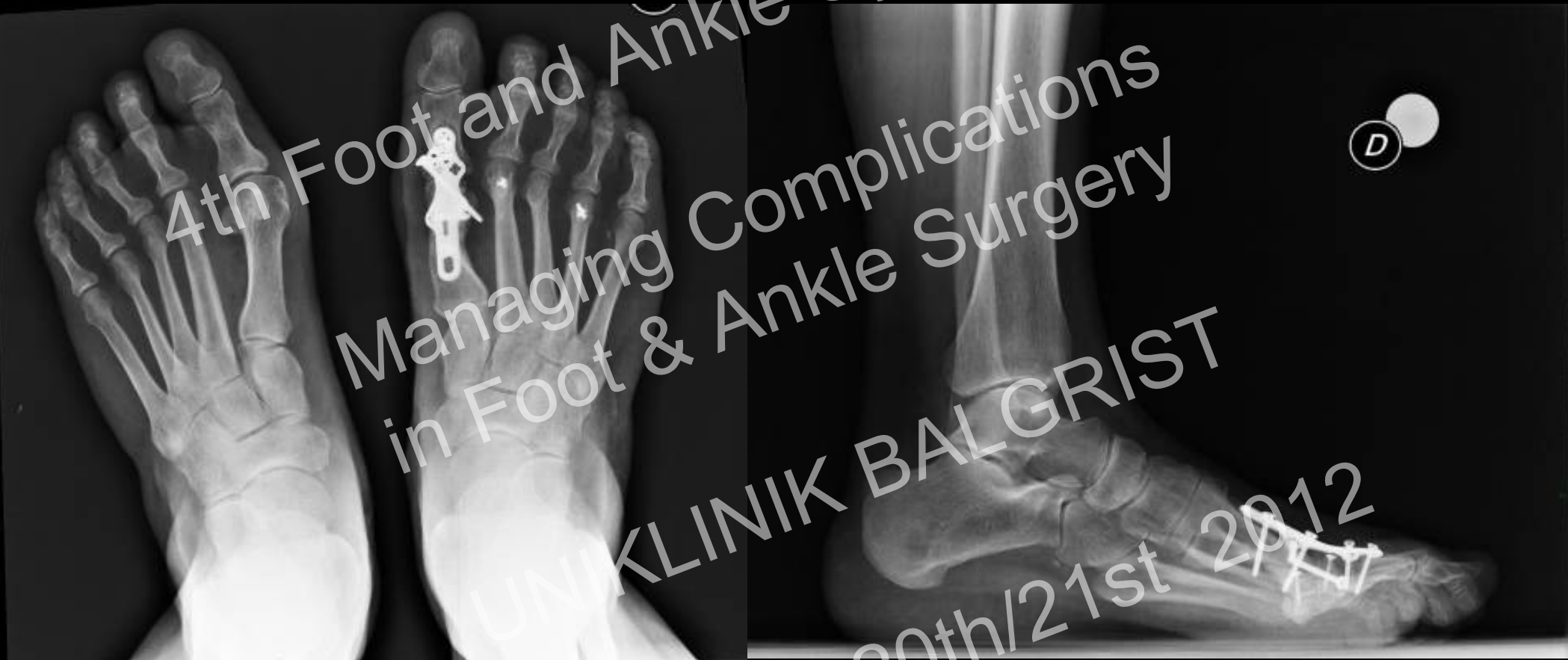

4th Foot and Ankle Symposium

Managing Complications in Foot & Ankle Surgery

UNIKLINIK BALGRIST

September 20th/21st 2012



4th Foot and Ankle Symposium

Managing Complications
in Foot & Ankle Surgery

UNIKLINIK BALGRIST

September 20th/21st 2012

A grayscale MRI scan of a human foot and ankle, showing the internal structures of the bones, joints, and soft tissues. The image is oriented with the heel at the top right and the toes at the bottom left.

4th Foot and Ankle Symposium

Managing Complications
in Foot & Ankle Surgery

UNIKLINIK BALGRIST

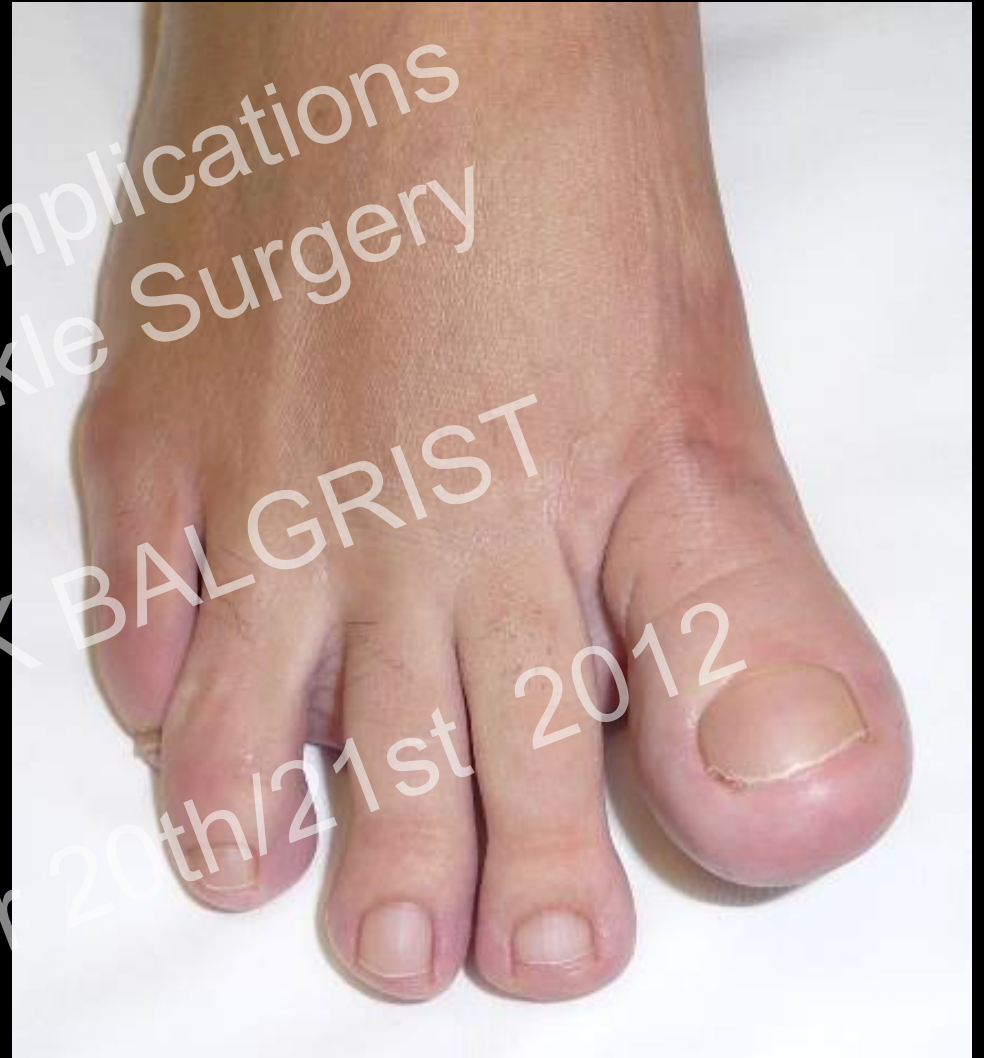September 20th/21st 2012

MALUNION

TRANSVERSE PLANE

ADDUCTION OF THE
HALLUX

SHOEWEAR PROBLEMS,
BUT MAY WORK

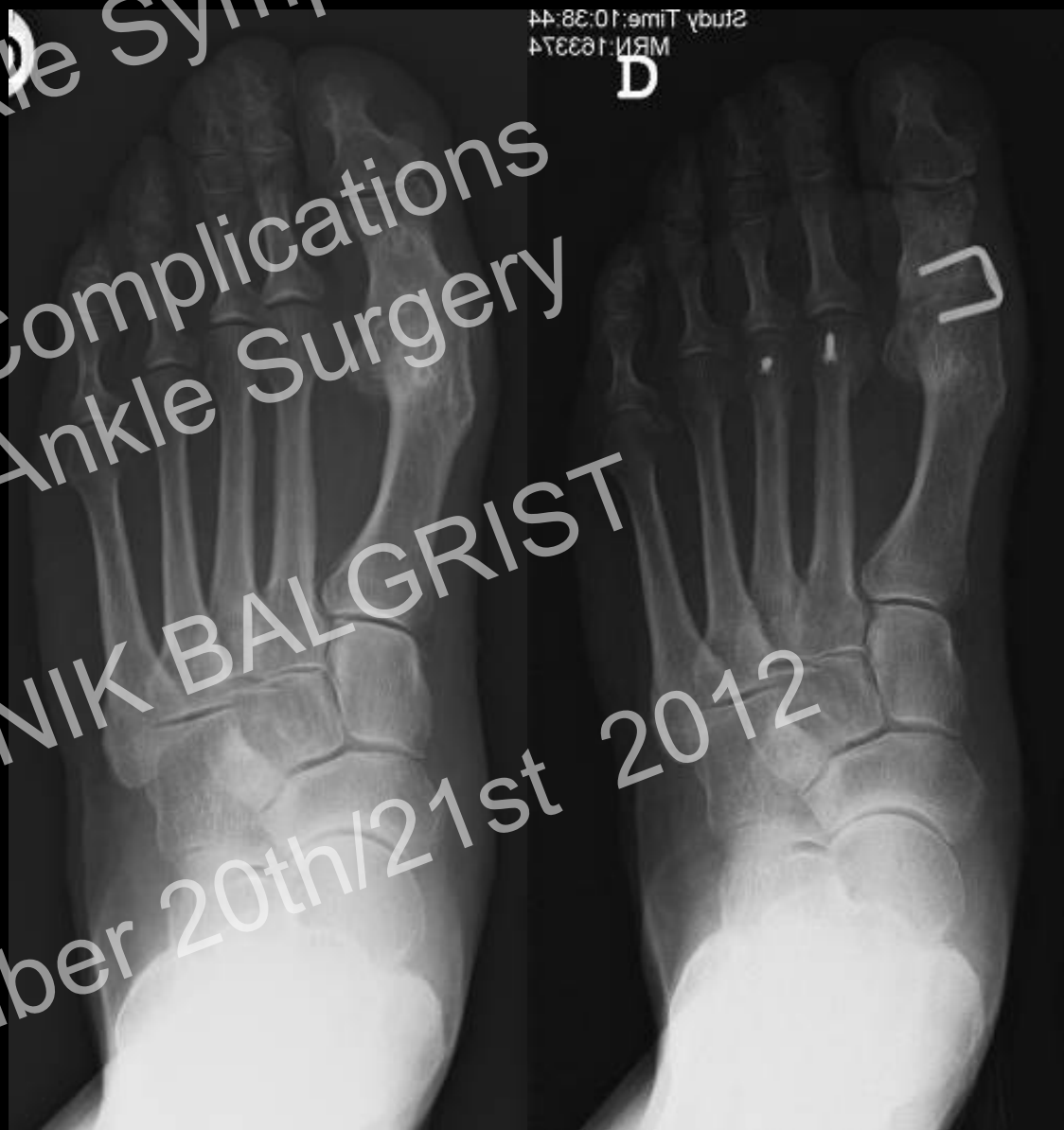

MALUNION

TRANSVERSE PLANE

ABDUCTION OF THE
HALLUX

CONFLICT WITH 2ND TOE

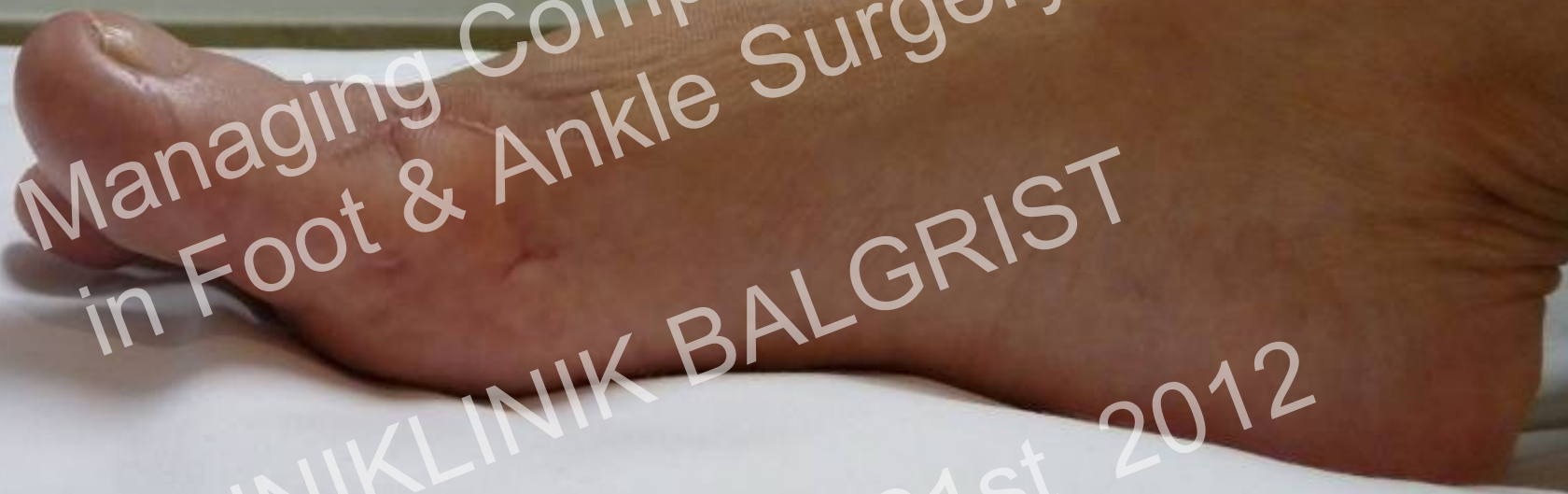

4th Foot and Ankle Symposium

Managing Complications
in Foot & Ankle Surgery

UNIKLINIK BALGRIST

September 20th/21st 2012



4th Foot and Ankle Symposium

Managing Complications
in Foot & Ankle Surgery

UNIKLINIK BALGRIST

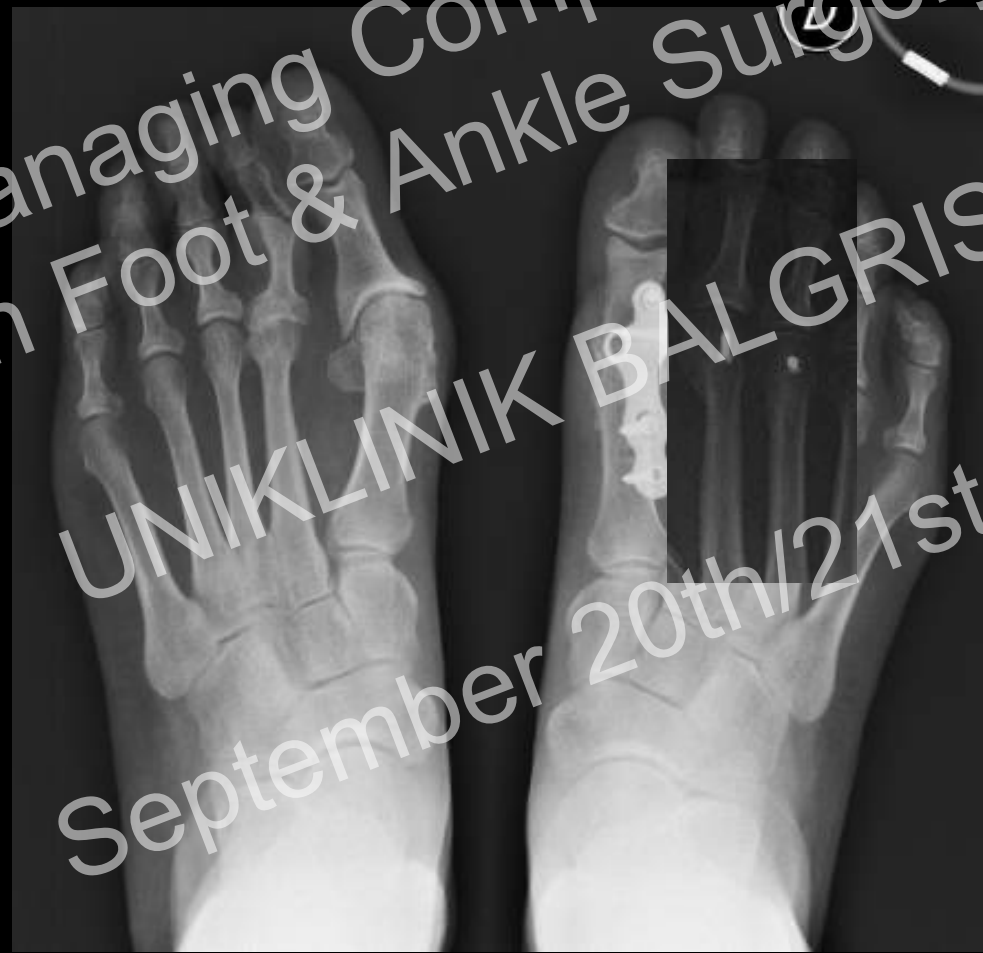September 20th/21st 2012



MALUNION

1ST SHORTENING

TRANSFER METATARSALGIA AND 2ND SPACE SYNDROME



MALUNION: CAUSES

SURGICAL TECHNIQUE

POSITION

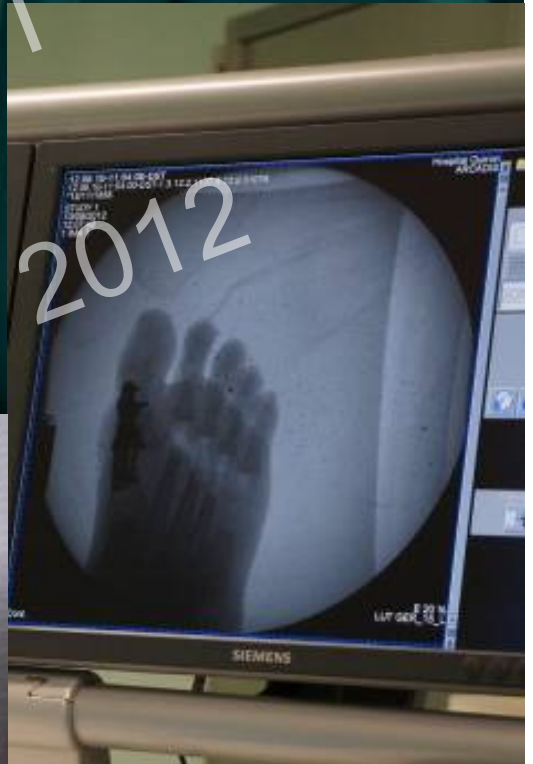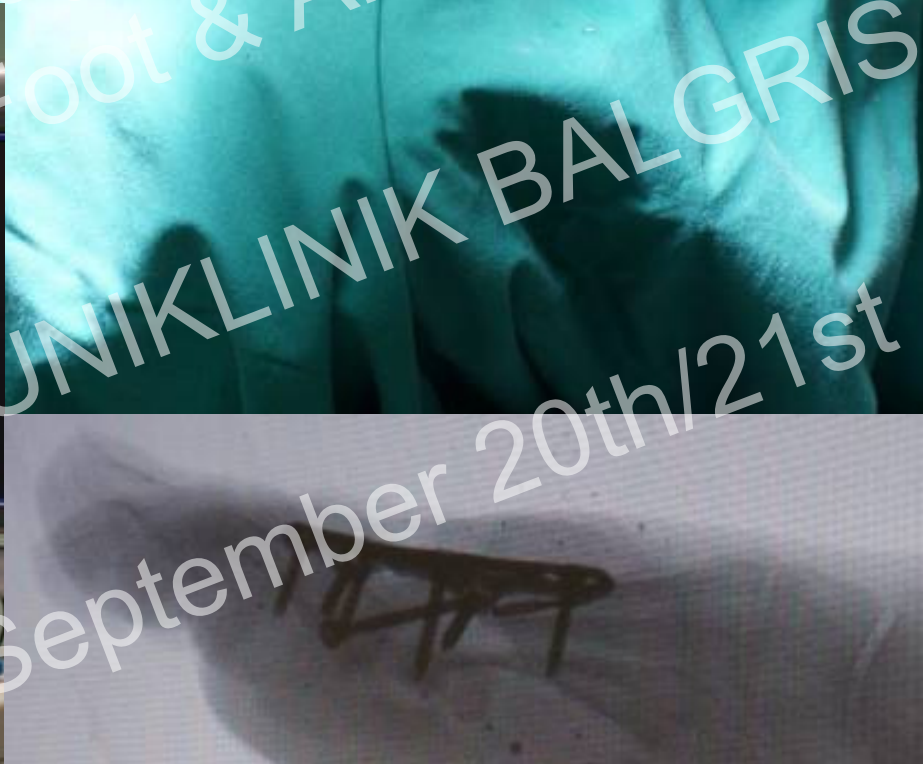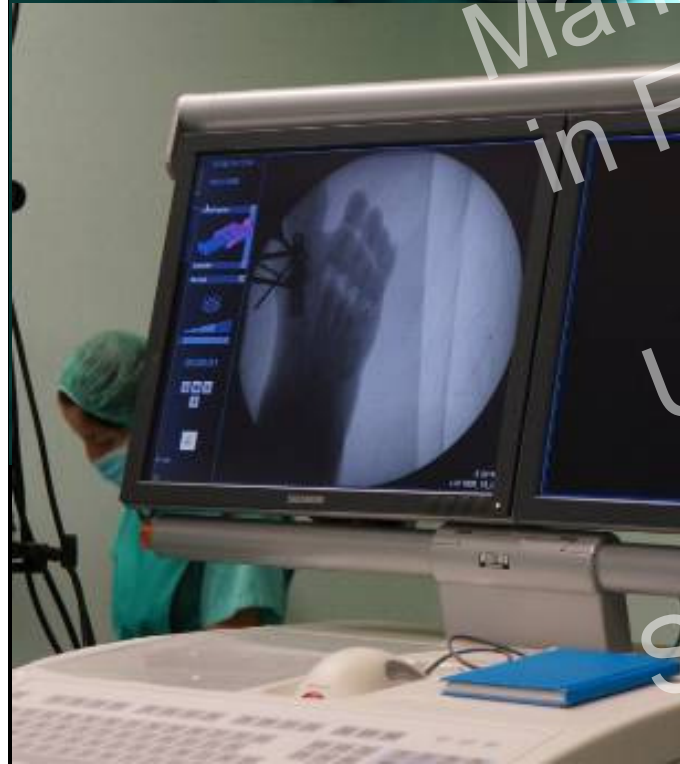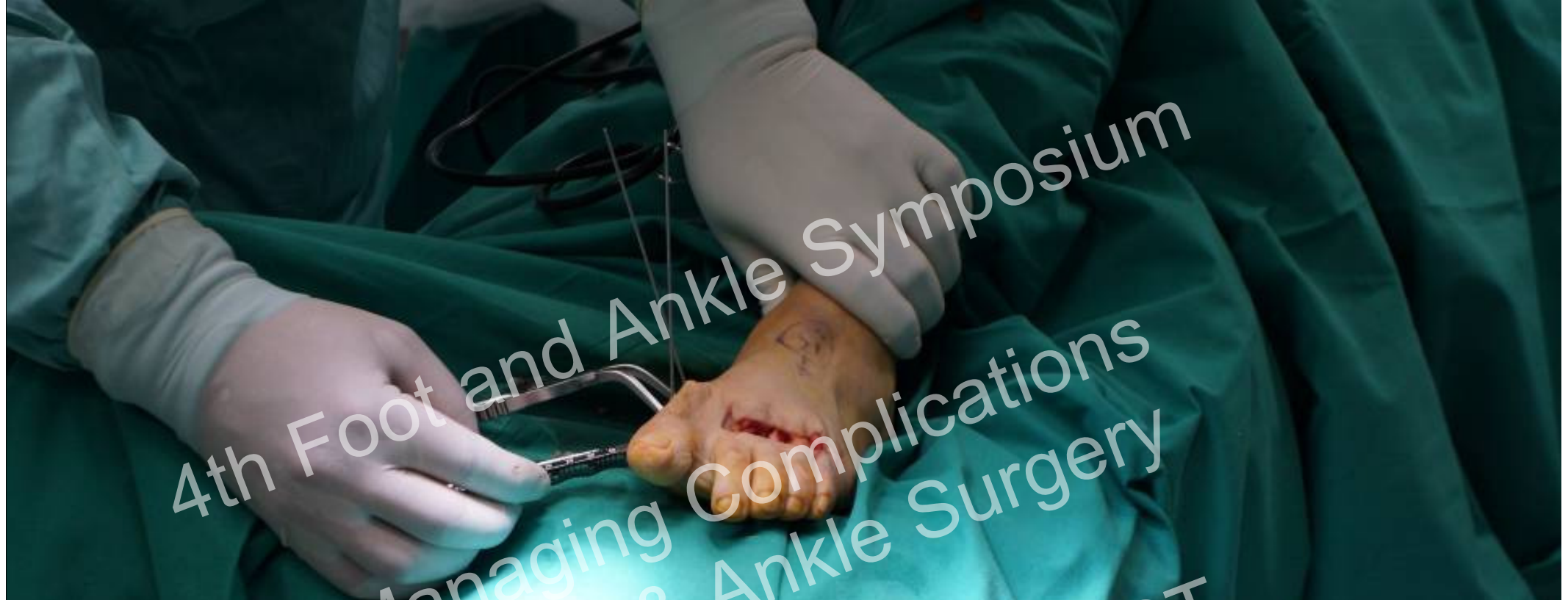POSITION

POSITION

POSITION

POSITION

4th Foot and Ankle Symposium
Managing Complications
in Foot & Ankle Surgery
UNIKLINIK KÖLN
September 20th/21st 2012



MALUNION: SOLUTIONS



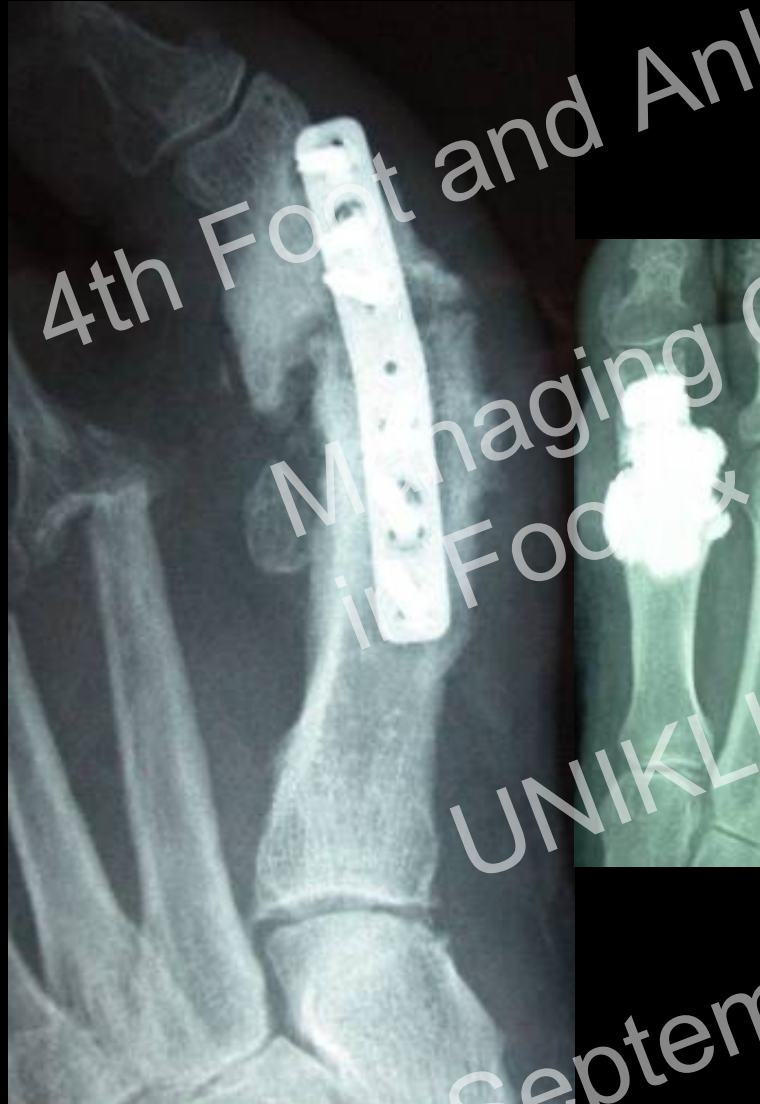SHOEWEAR MODIFICATIONS
SURGERY



CORRECTIVE OSTEOTOMIES AND FIXATION

TRIPLE WEIL OSTEOTOMIES vs RESECTION ARTHROPLASTY IF
SHORTENING 1ST RAY

INFECTION



METALWORK REMOVAL
DEBRIDEMENT

ANTIBIOTIC BEADS OR
CEMENT SPACER

REDO FUSION O KELLER

NON-UNION

PRIMARY MP1 FUSION – 1-14% NON UNIONS

REVISION MP1 FUSION – 8-21% NON UNIONS

(BONE BLOCK DISTRACTION ARTHRODESIS)

NON-UNION MAY BE ASYMPTOMATIC ...

I HAVE SEEN MORE ASYMPTOMATIC THAN SYMPTOMATIC
MP1 NON UNIONS

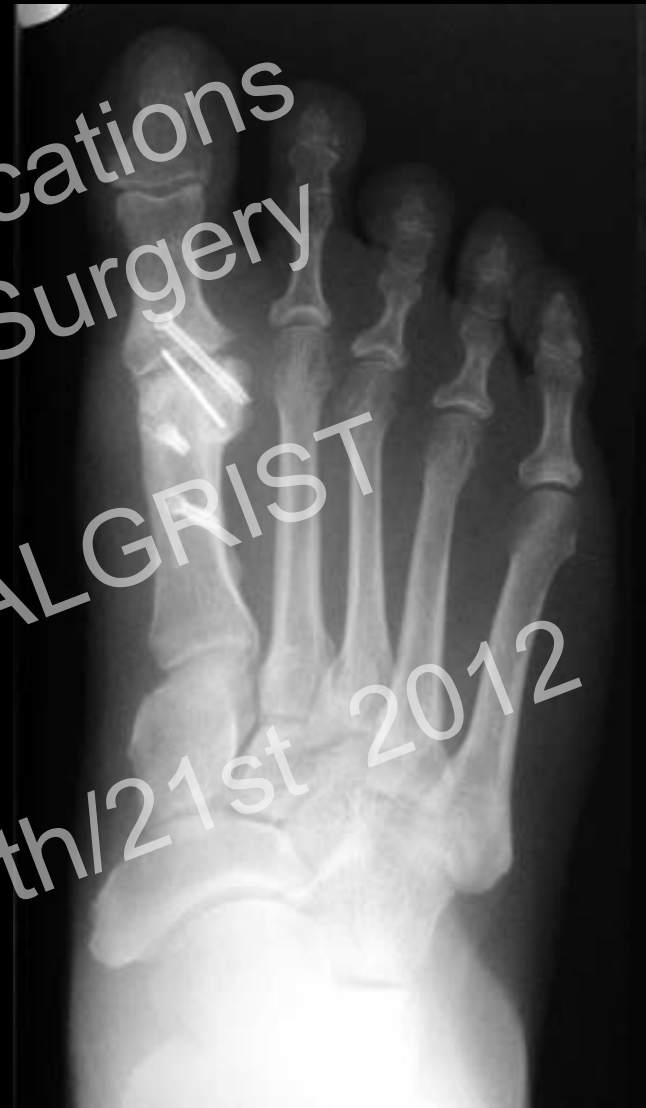TALK TO YOUR PATIENT ON FIBROUS UNION vs BONY UNION

WORK WELL AS LONG AS HALLUX POSITION ADECUATE

NON-UNION: SYMPTOMATIC ...

RETAINED PIN OR
SCREW

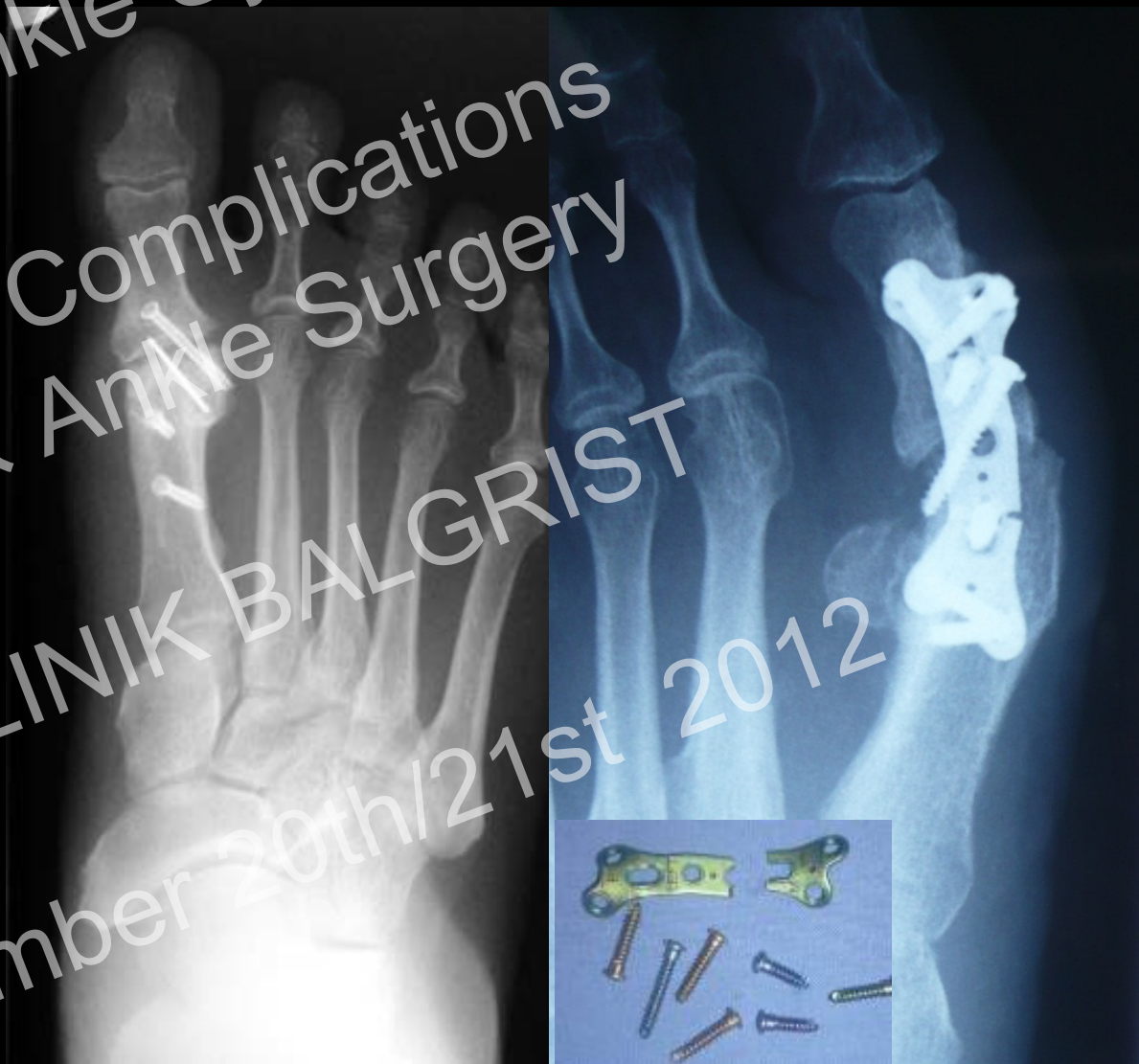STRESS MOVEMENT
OF FLEXIBLE
NONUNION AGAINST
IMPLANT



NON-UNION: SYMPTOMATIC ...

RETAINED PIN OR
SCREW

STRESS MOVEMENT
OF FLEXIBLE
NONUNION AGAINST
IMPLANT



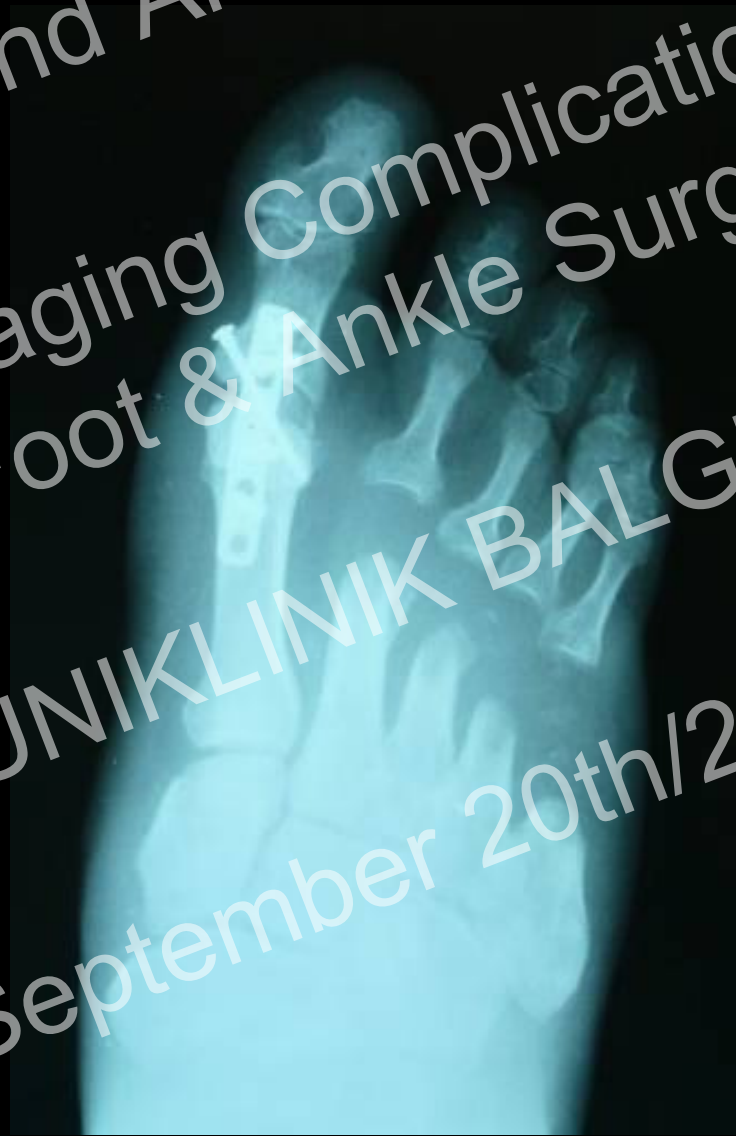NON-UNION: ASYMPTOMATIC ...

4th Foot and Ankle Symposium

Managing Complications
in Foot & Ankle Surgery

UNIKLINIK BALGRIST

September 20th/21st 2012



NON-UNION: CAUSES

PATIENT

DIABETES AND RHEUMATOID ARTHRITIS

PREVIOUS SCARS

VASCULAR STATUS

SMOKING

4th Foot and Ankle Symposium

Managing Complications
in Foot & Ankle Surgery

UNIKLINIK BALGRIST

September 20th/21st 2012

NON-UNION: CAUSES

SURGICAL TECHNIQUE

BONE PREPARATION

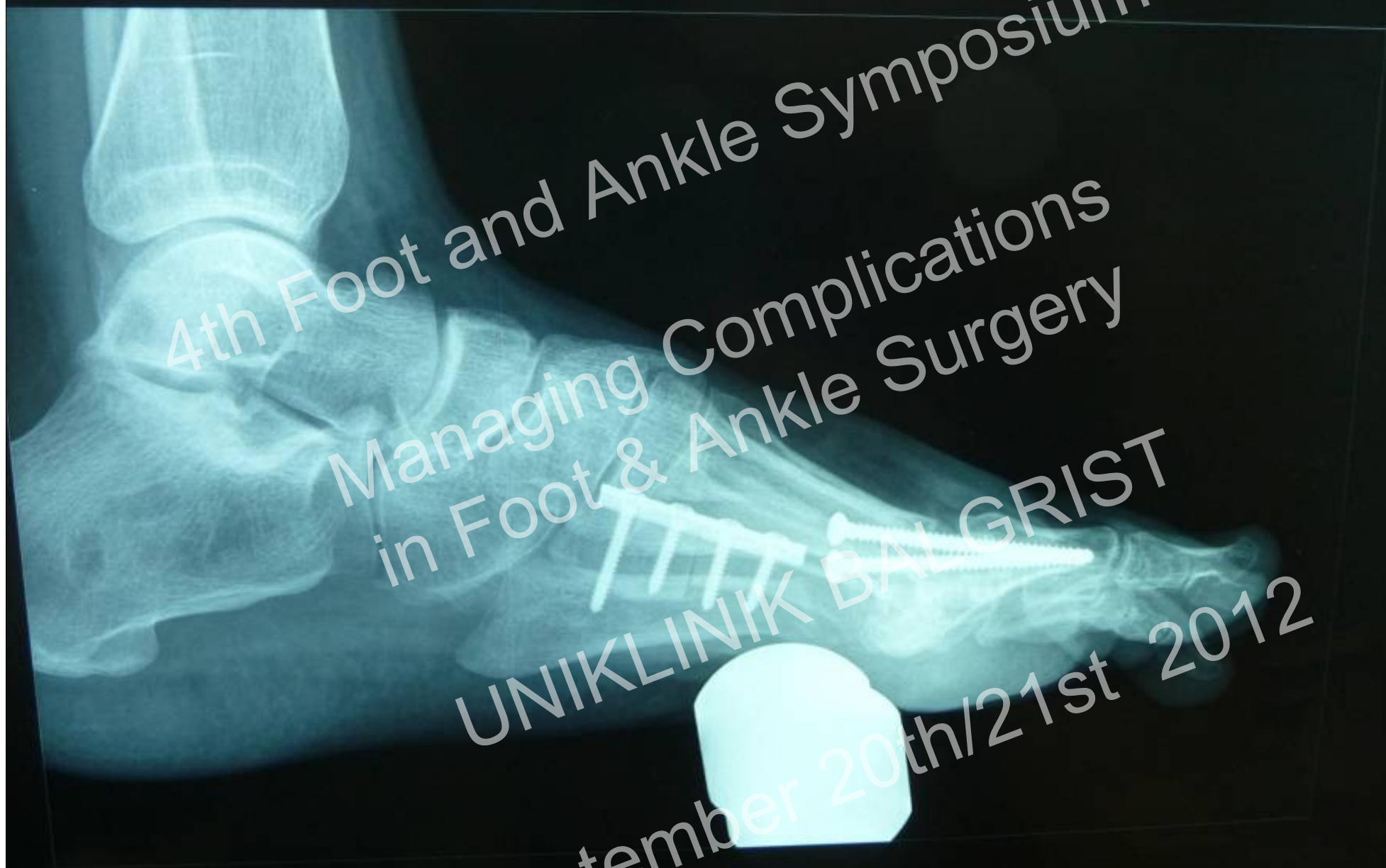IMPLANT SELECTION

4th Foot and Ankle Symposium

Managing Complications
in Foot & Ankle Surgery

UNIKLINIK BALGRIST

September 20th/21st 2012



4th Foot and Ankle Symposium

Managing Complications
in Foot & Ankle Surgery

UNIKLINIK BALGRIST

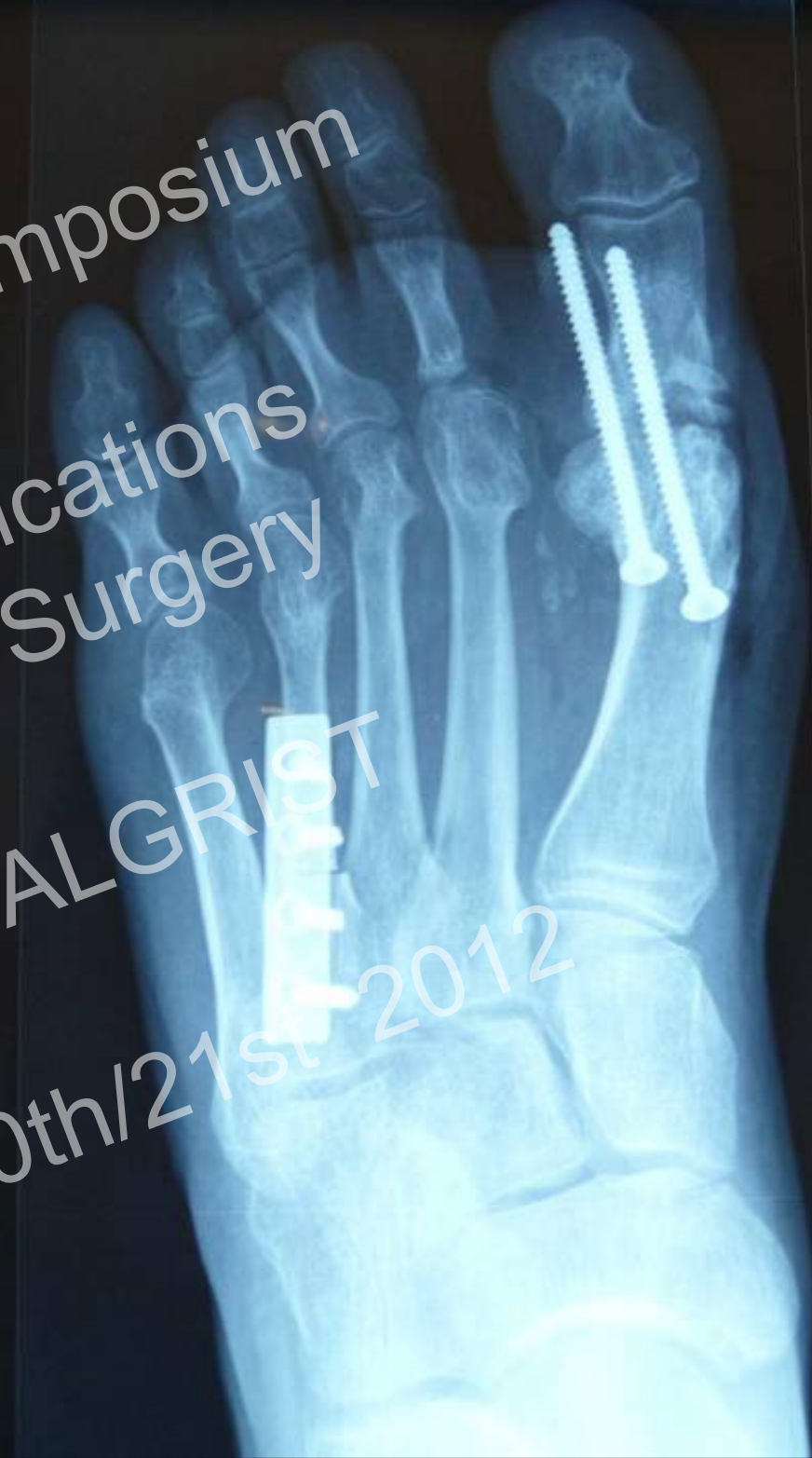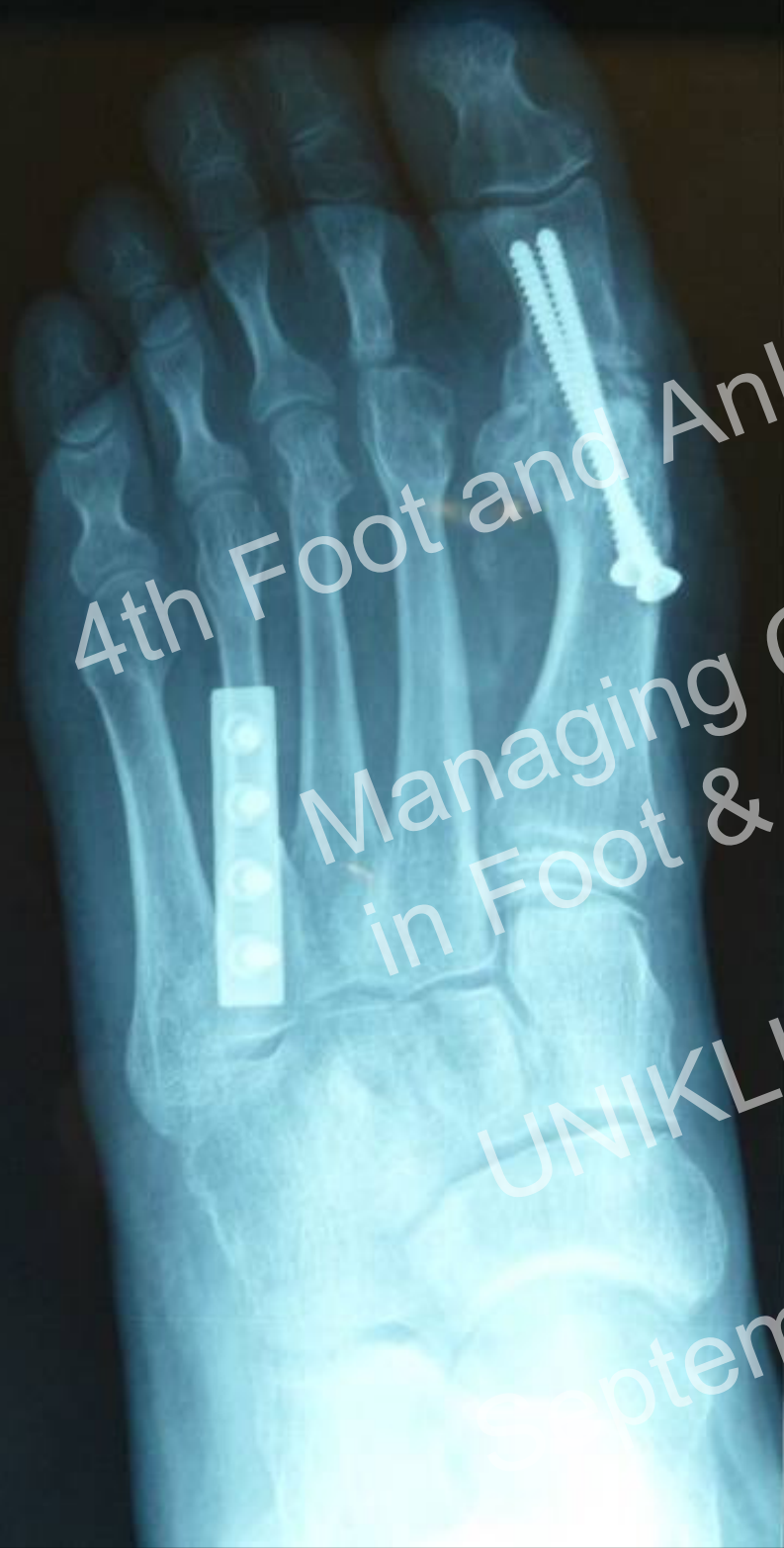September 20th/21st 2012

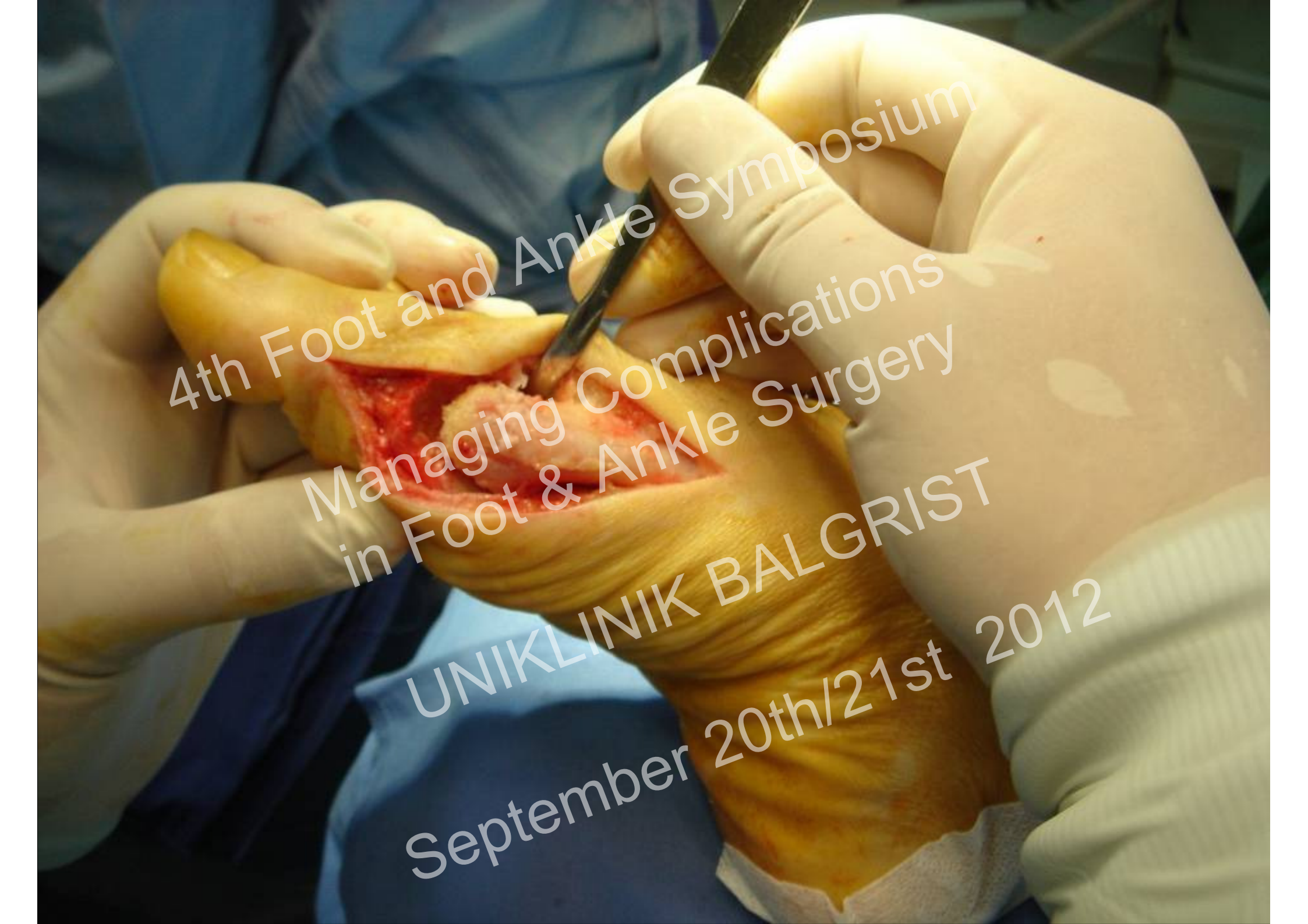4th Foot and Ankle Symposium

Managing Complications
in Foot & Ankle Surgery

UNIKLINIK BALGRIST

September 20th/21st 2012





4th Foot and Ankle Symposium

Managing Complications
in Foot & Ankle Surgery

UNIKLINIK BALGRIST

September 20th/21st 2012

NON-UNION: SOLUTIONS

ONLY IMPLANT REMOVAL AND DEBRIDEMENT

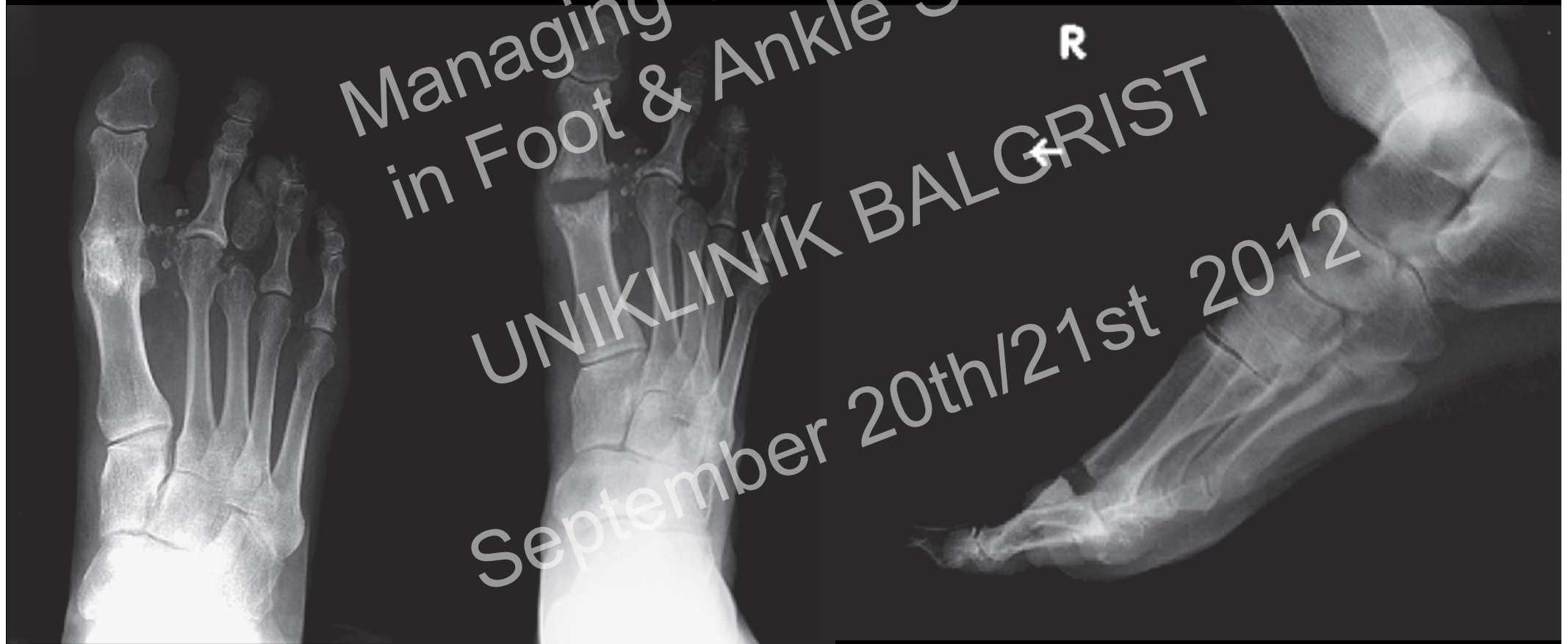Hope M, et al. Is it necessary to re-fuse a non-union of a hallux metatarsophalangeal joint arthrodesis? *Foot Ankle Int* 2010; 31:662-669.

ACCEPTABLE OUTCOME SCORES IN 7/11 PATIENTS

NON-UNION: SOLUTIONS

RECONVERSION TO INTERPOSITION ARTHROPLASTY
FREE TENDON GRAFT

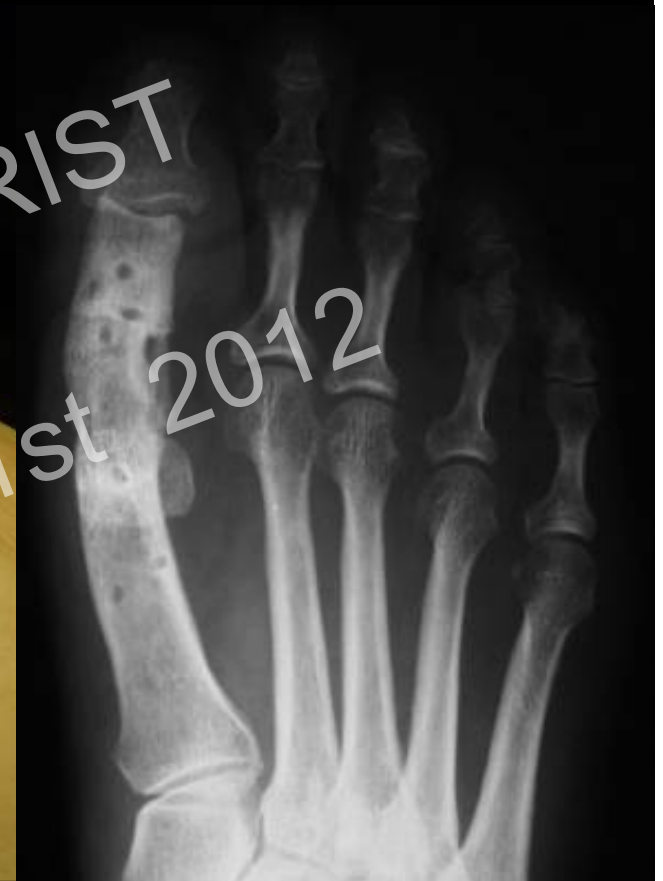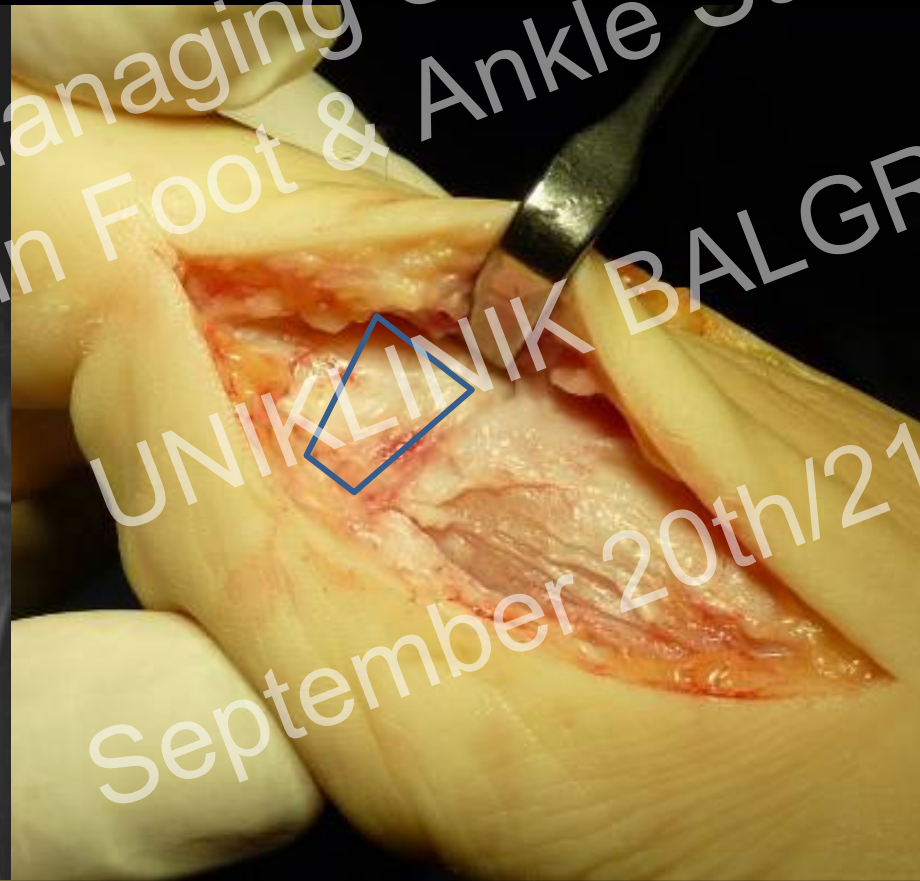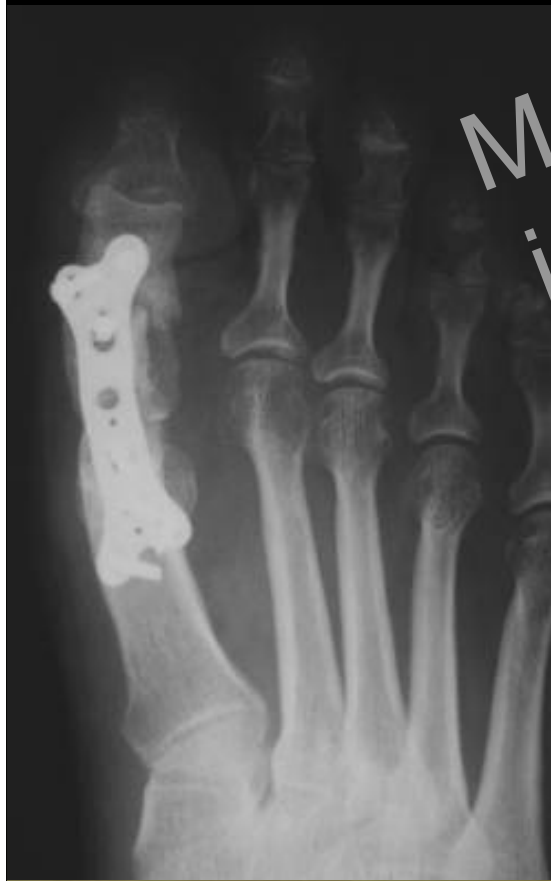(COURTESY OF M MYERSON)



NON-UNION: SOLUTIONS

BONE BLOCK DISTRACTION ARTHRODESIS

PROMOTE UNION - MAINTAIN LENGTH 1ST RAY



(INFECTED) NON-UNION: SOLUTIONS

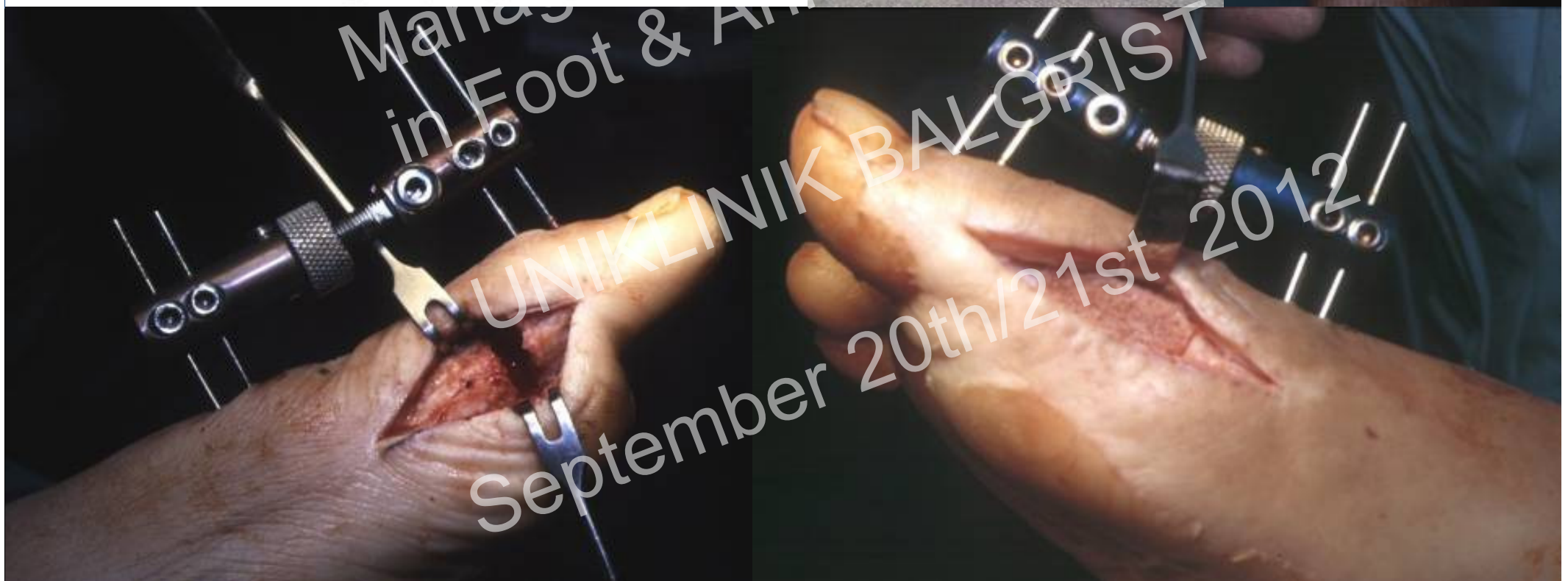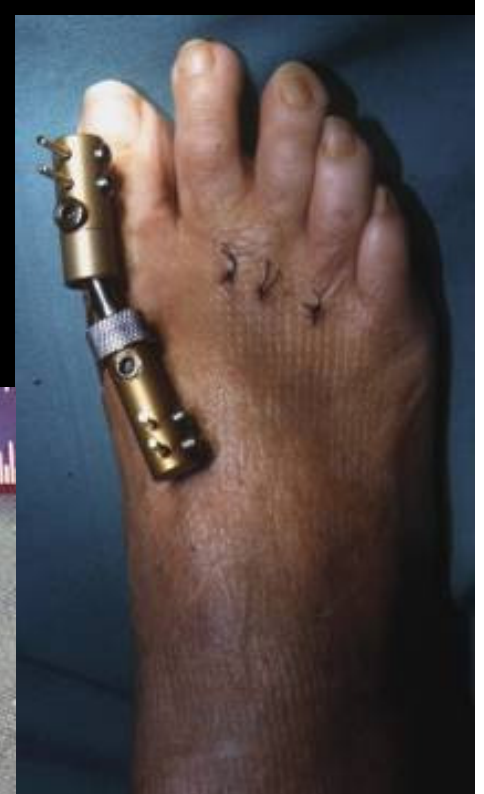(Courtesy Dr MNSamper)

Foot and Ankle Surgery 1999; 5: 227-233

Metatarsophalangeal arthrodesis of the first toe by distraction and bone interposition for the treatment of severe first ray deficiency

M. NÚÑEZ-SAMPER, M.N. KUBBA AND
L.F. LLANOS ALCÁZAR

Traumatology and Orthopaedic Surgery Unit, Virgen del Mar Clinic, Madrid, Spain



DEBRIDEMENT AND BONE PREPARATION

4th Foot and Ankle Symposium

Managing Complications
in Foot & Ankle Surgery

UNIKLINIK BALGRIST

September 20th/21st 2012

IMPLANT CHOICE FOR FAILURES



NEW IMPLANTS

REVISION SURGERY – COMPRESSION & STABILITY

VARIABLE ANGLE + LOCKING SCREWS

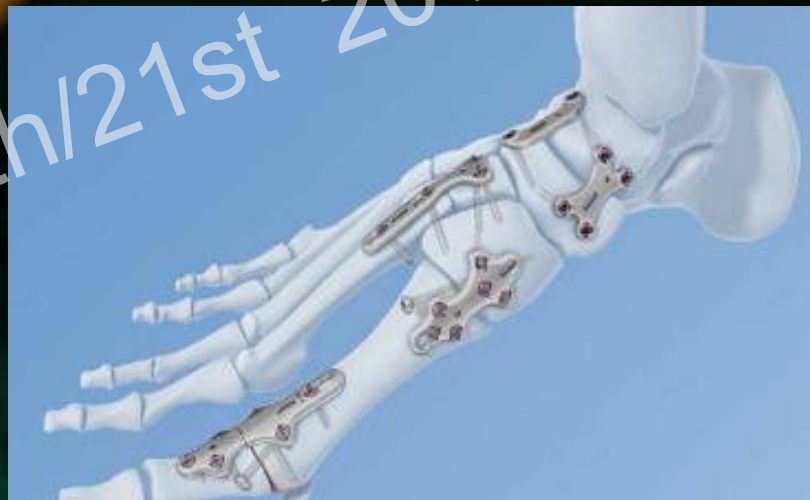
ENHANCED PRIMARY STABILITY IN POOR BONE CONDITIONS

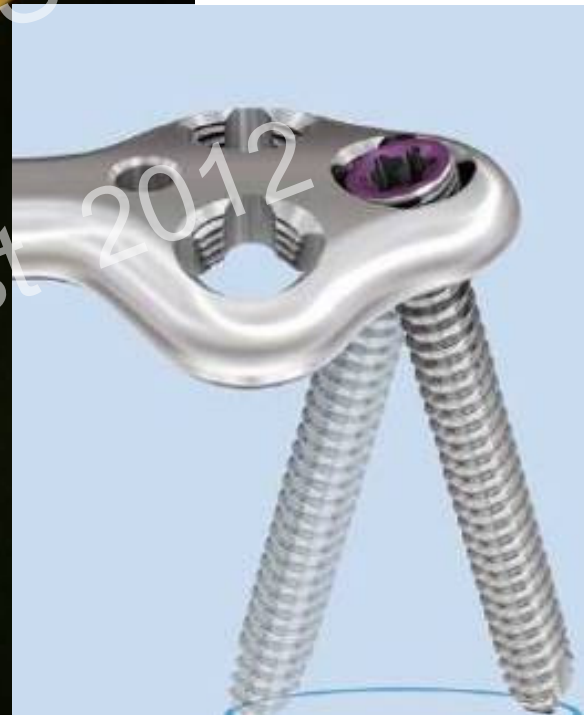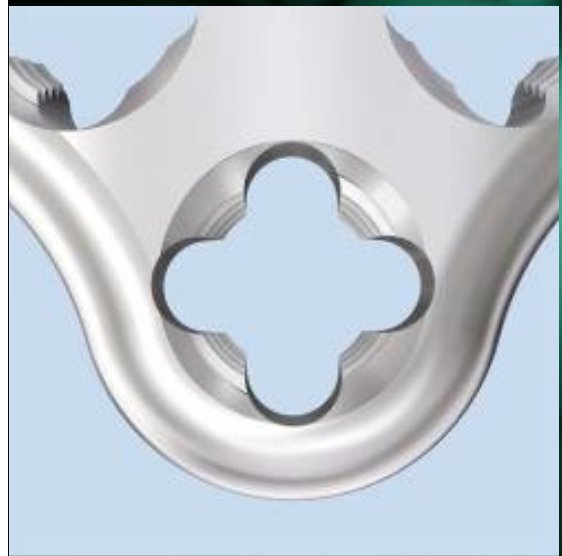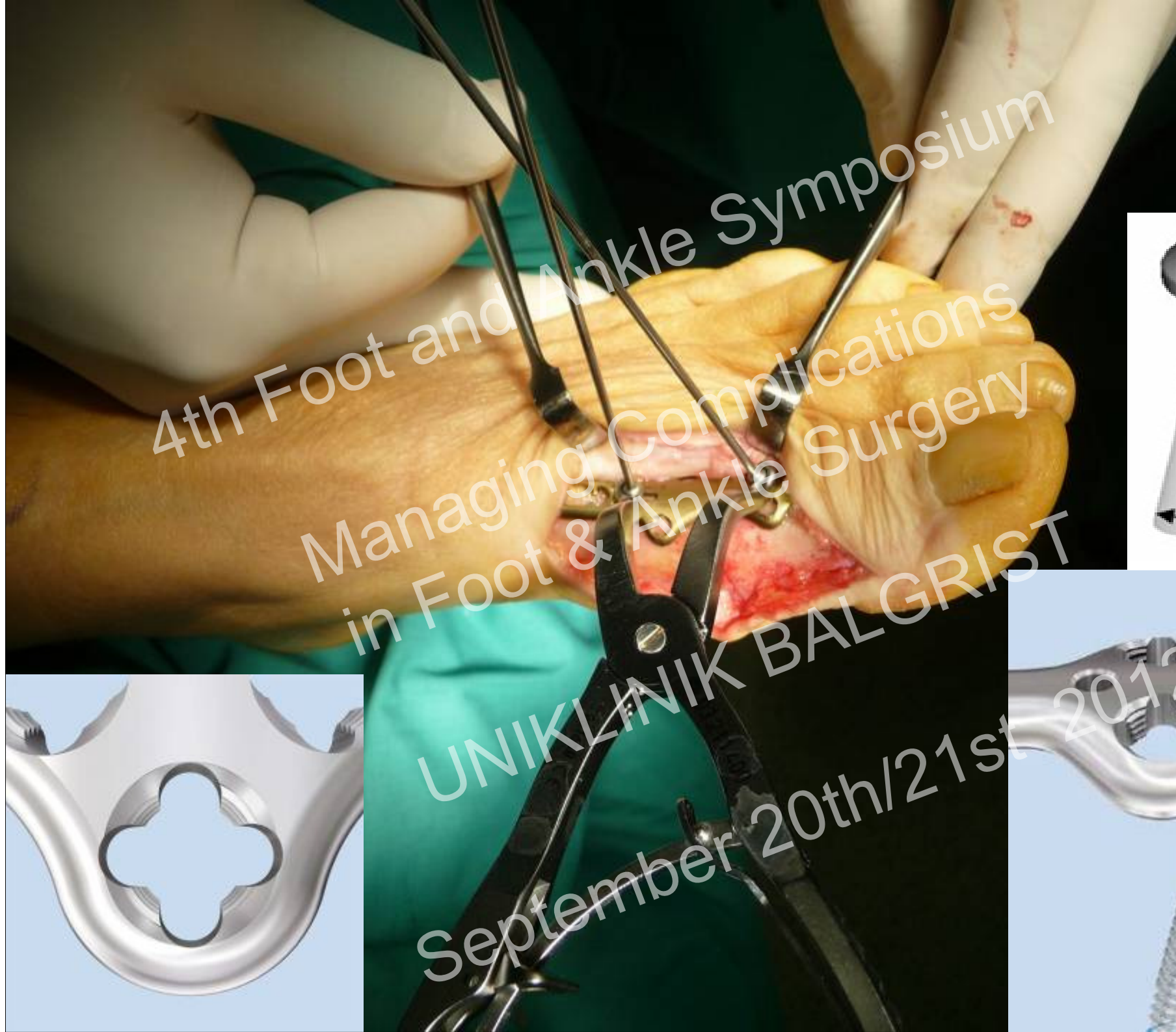4th Foot and Ankle Symposium

Managing Complications
in Foot & Ankle Surgery

UNIKLINIK BALGRIST

September 20th/21st 2012





4th Foot and Ankle Symposium

Managing Complications
in Foot & Ankle Surgery

UNIKLINIK BALGRIST

September 20th/21st 2012

D

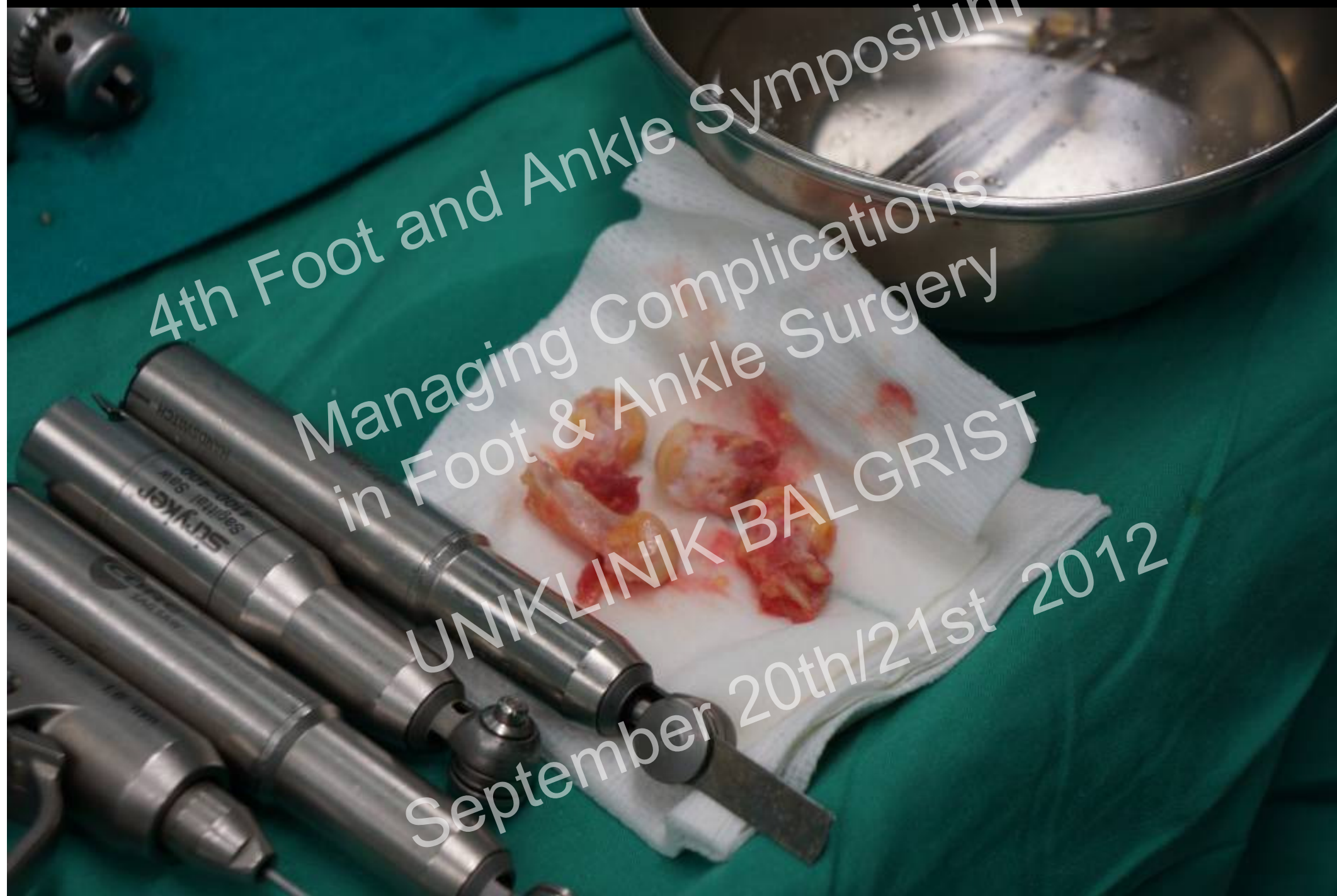4th Foot and Ankle Symposium

Managing Complications
in Foot & Ankle Surgery

UNIKLINIK BALGRIST

September 20th/21st 2012

ILIAC CREST vs FOREFOOT BONE



4th Foot and Ankle Symposium

Managing Complications
in Foot & Ankle Surgery

UNIKLINIK BALGRIST

September 20th/21st 2012

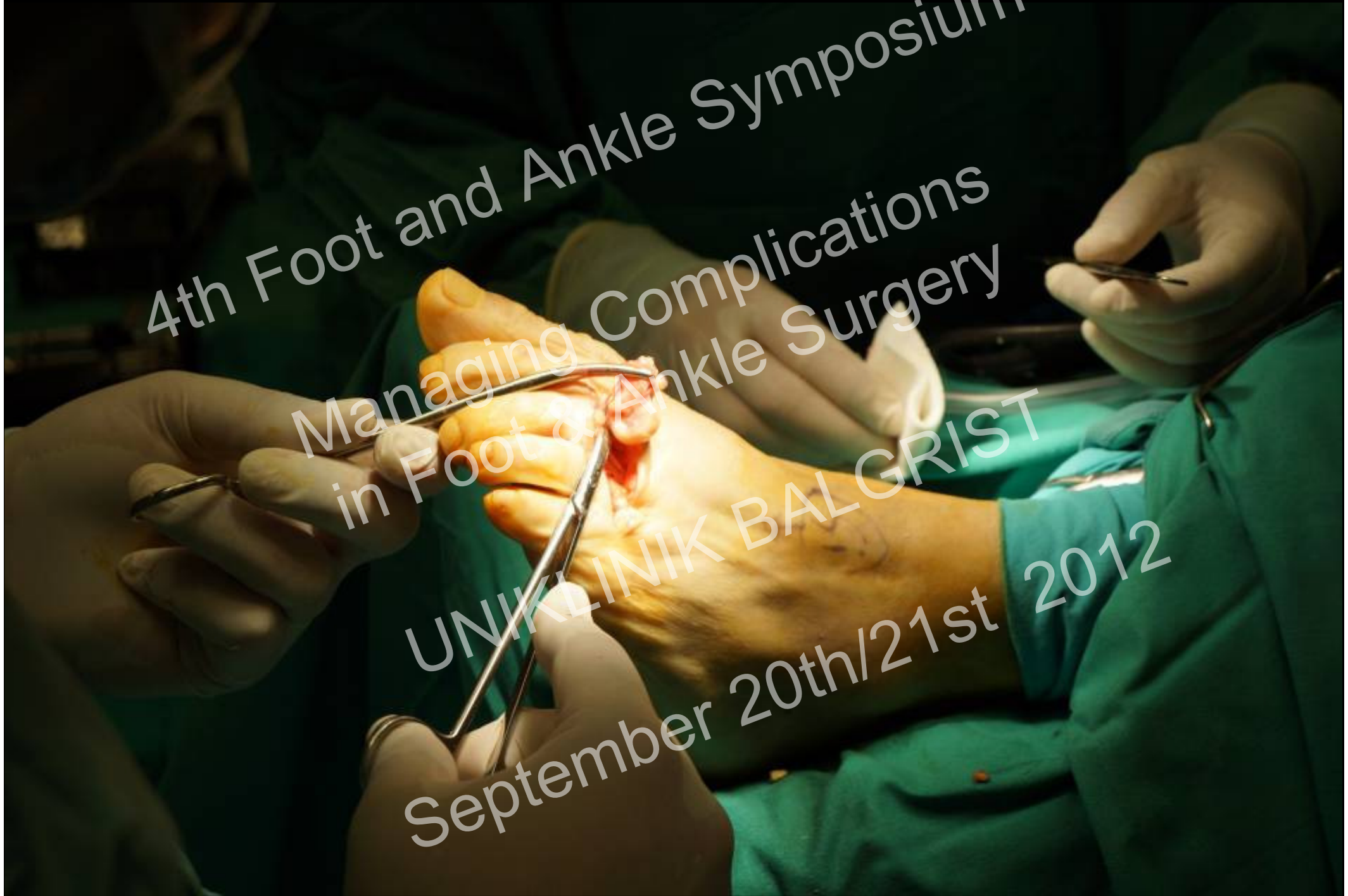AUTOGRAFTS

4th Foot and Ankle Symposium

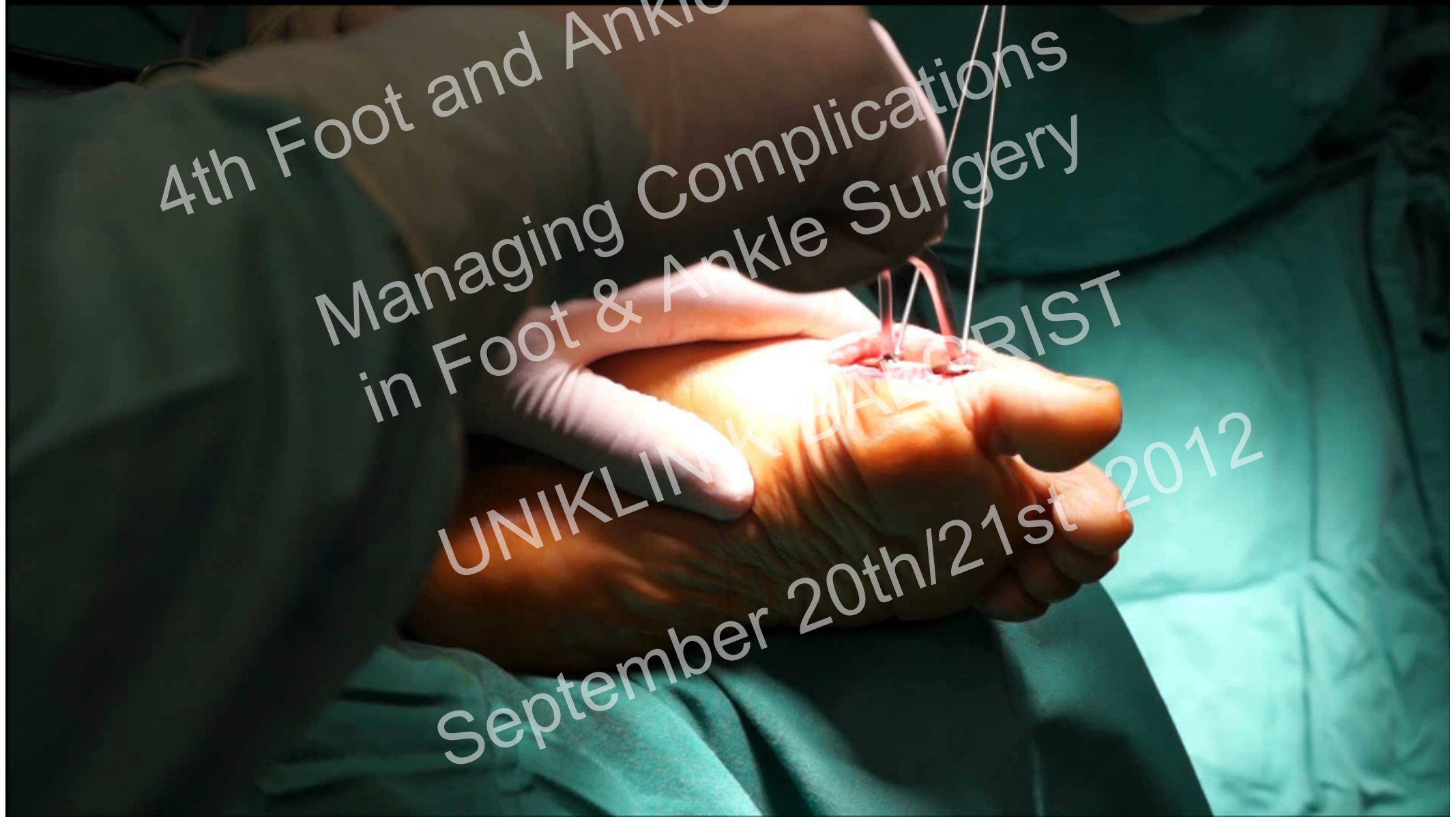Managing Complications
in Foot & Ankle Surgery

UNIKLINIK BALGRIST

September 20th/21st 2012



SURGICAL CONSIDERATIONS TO AVOID FAILURE



No cut

POSTOP



4th Foot and Ankle Symposium

Managing Complications
in Foot & Ankle Surgery

UNIKLINIK BALGRIST

September 20th/21st 2012

6sp

1

IAL

VOI

PLS

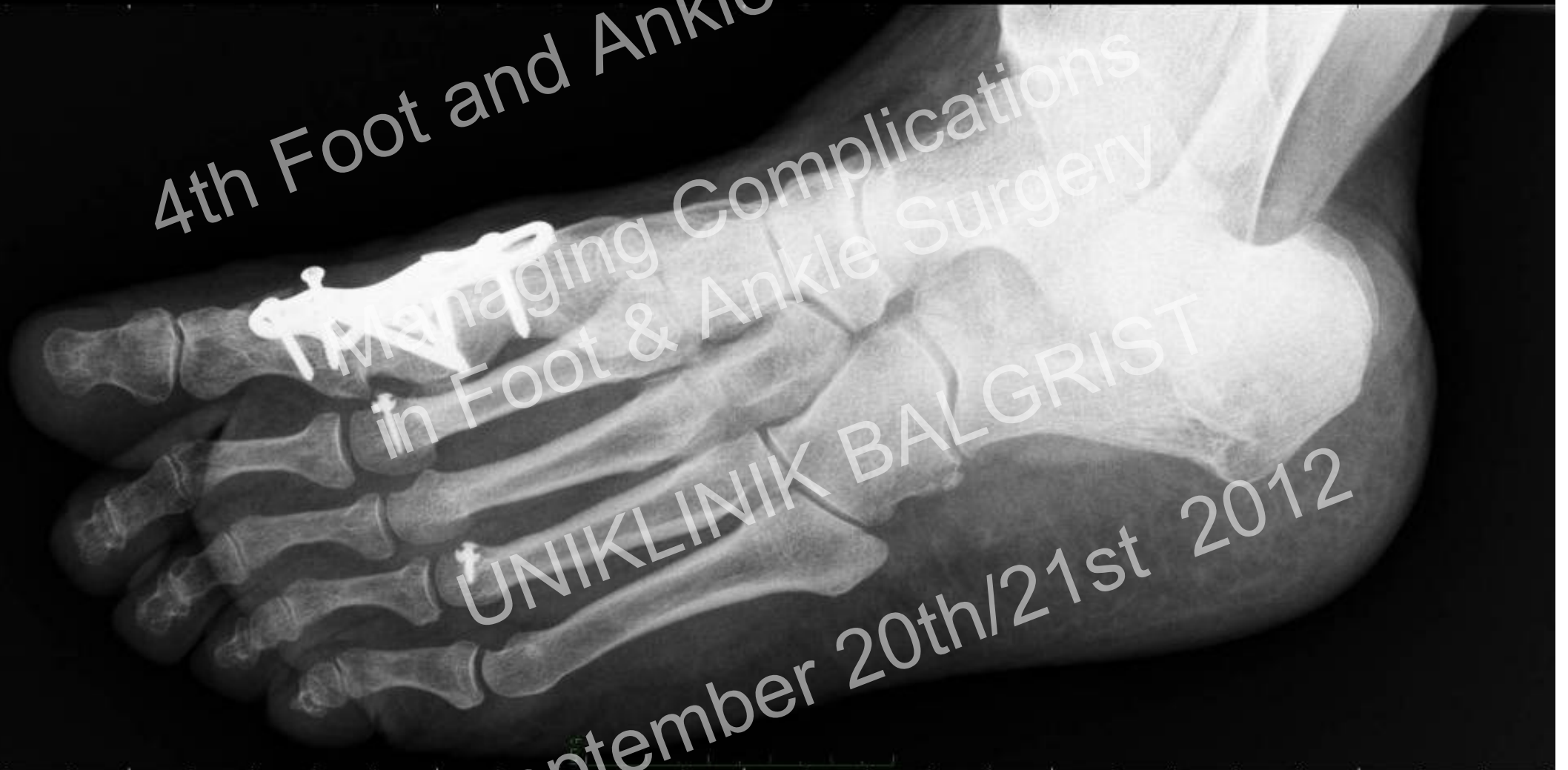IMPLANT RELATED

4th Foot and Ankle Symposium

Managing Complications
in Foot & Ankle Surgery

UNIKLINIK BALGRIST

September 20th/21st 2012



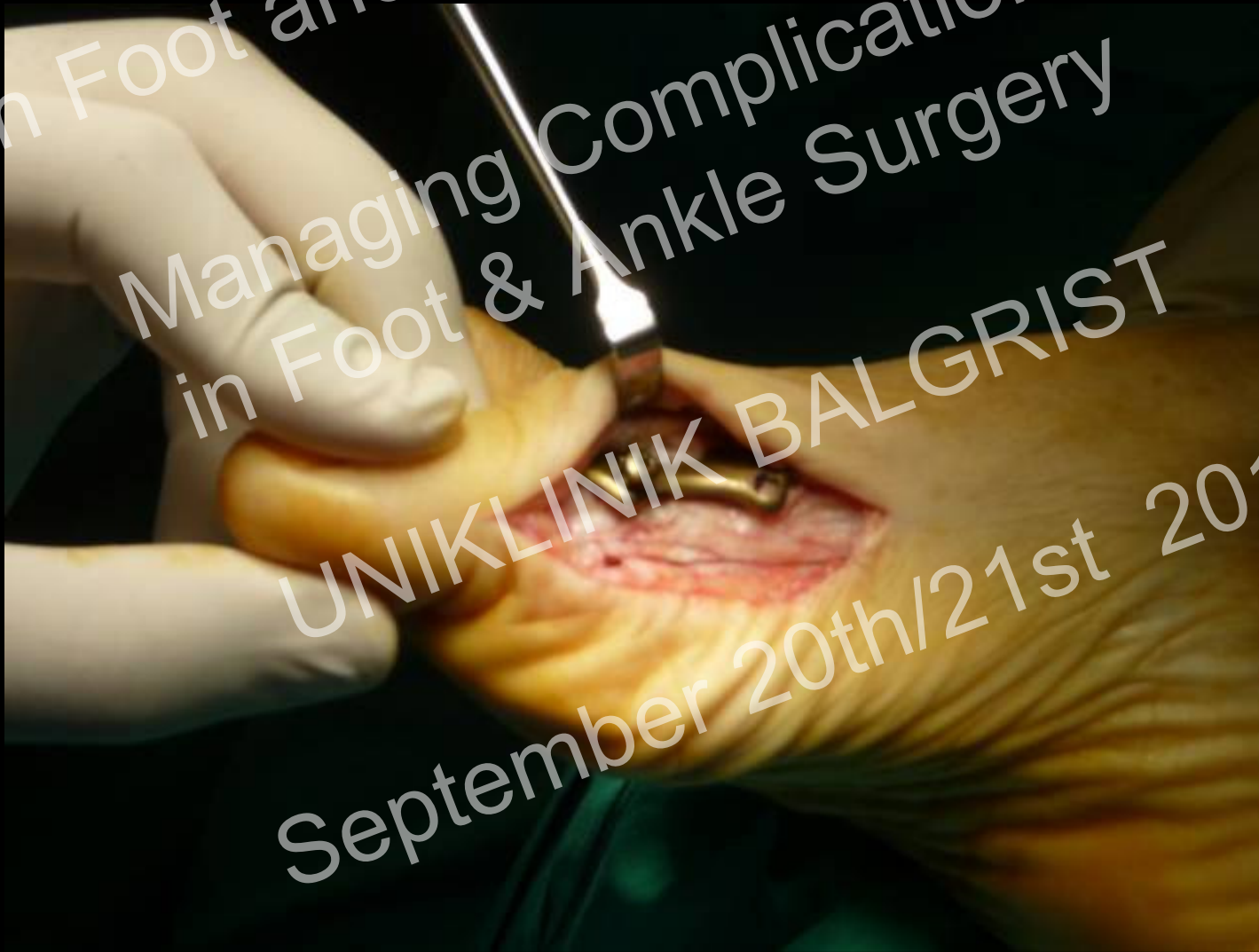IMPLANT RELATED

4th Foot and Ankle Symposium

Managing Complications
in Foot & Ankle Surgery

UNIKLINIK BALGRIST

September 20th/21st 2012



IMPLANT RELATED: SOLUTIONS

GET TO KNOW THE IMPLANT

LOCKING SCREWS

POSITION AWAY FROM INTERPHALANGEAL JOINT

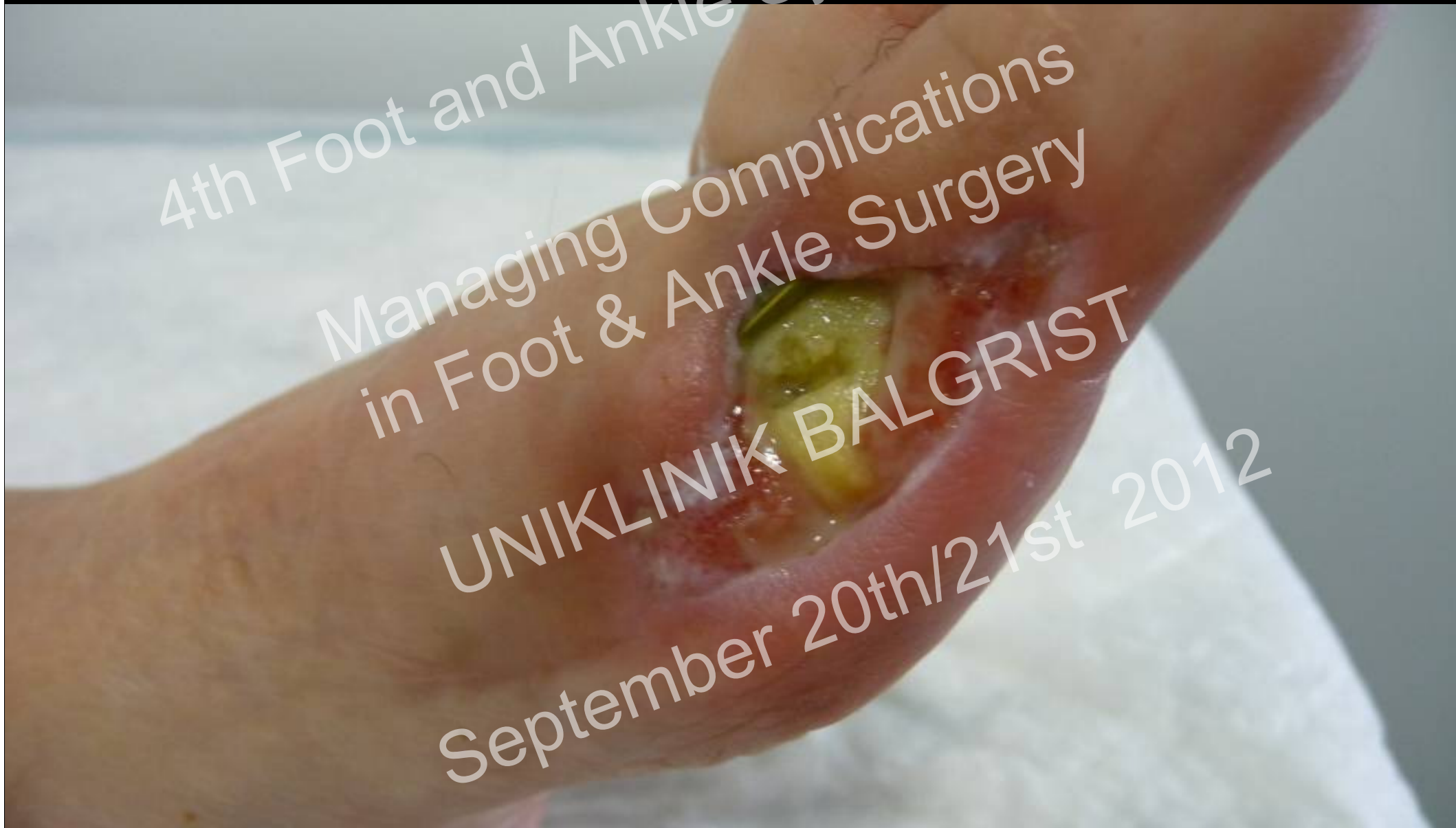AMPUTATION

4th Foot and Ankle Symposium

Managing Complications
in Foot & Ankle Surgery

UNIKLINIK BALGRIST

September 20th/21st 2012



AMPUTATION CAUSES

SOMETIMES INEVITABLE

DIABETES AND RHEUMATOID

MEDICOLEGAL PROTECTION

4th Foot and Ankle Symposium

Managing Complications
in Foot & Ankle Surgery

UNIKLINIK BALGRIST

September 20th/21st 2012

AMPUTATION SOLUTIONS

FIND A GOOD ORTHOPAEDIC TECHNICIAN

BE REALISTIC WITH PATIENT EXPECTATIONS

LOW PHYSICAL DEMAND

4th Foot and Ankle Symposium

Managing Complications
in Foot & Ankle Surgery

UNIKLINIK BALGRIST

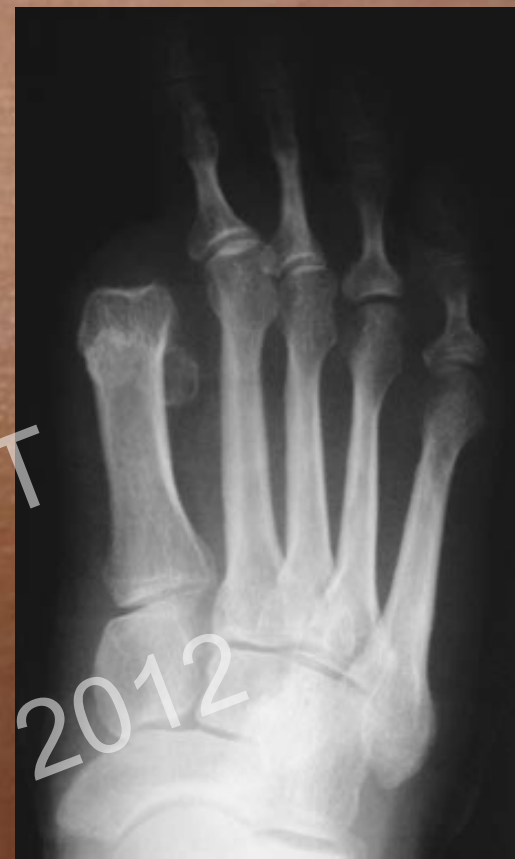September 20th/21st 2012

4th Foot and Ankle Symposium

Managing Complications
in Foot & Ankle Surgery

UNIKLINIK BALGRIST

September 20th/21st





4th Foot and Ankle Symposium

Managing Complications
in Foot & Ankle Surgery

UNIKLINIK BALGRIST

September 20th/21st 2012

4th Foot and Ankle Symposium

Managing Complications
in Foot & Ankle Surgery

UNIKLINIK BALGRIST

September 20th/21st 2012

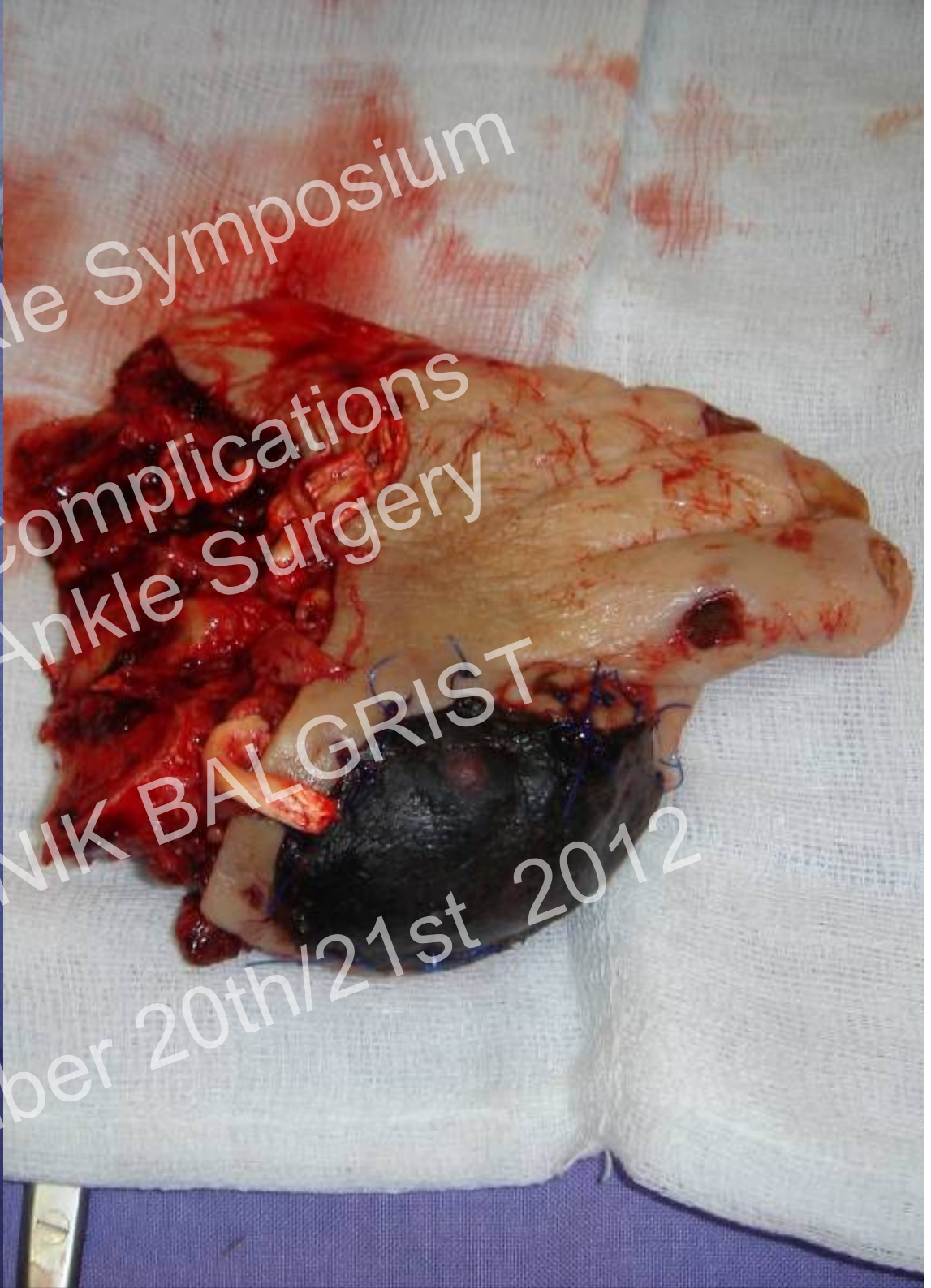
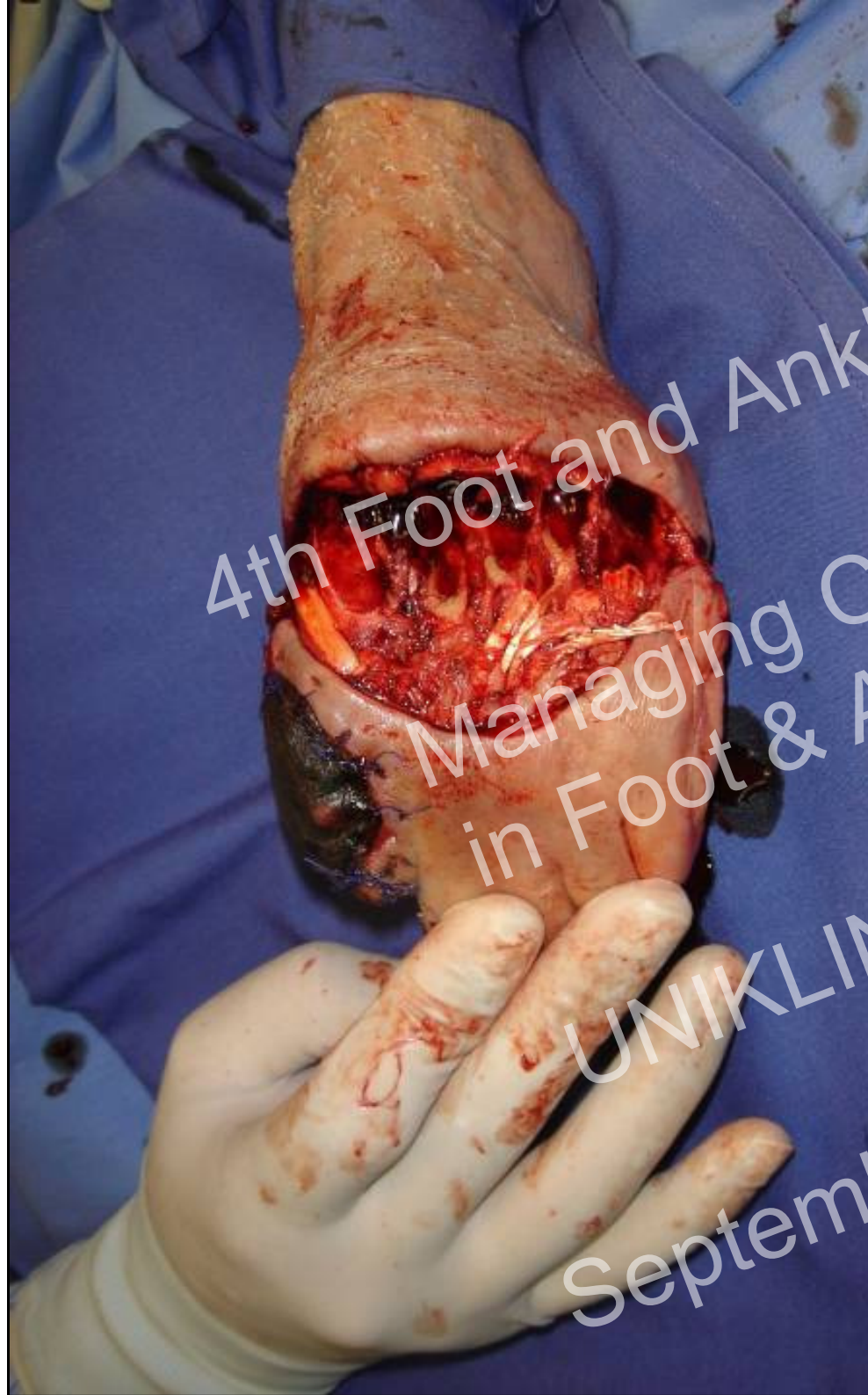
4th Foot and Ankle Symposium

Managing Complications
in Foot & Ankle Surgery

UNIKLINIK BALGRIST

September 20th/21st 2012



4th Foot and Ankle Symposium
Managing Complications
in Foot & Ankle Surgery

UNIKLINIK BALGRIST

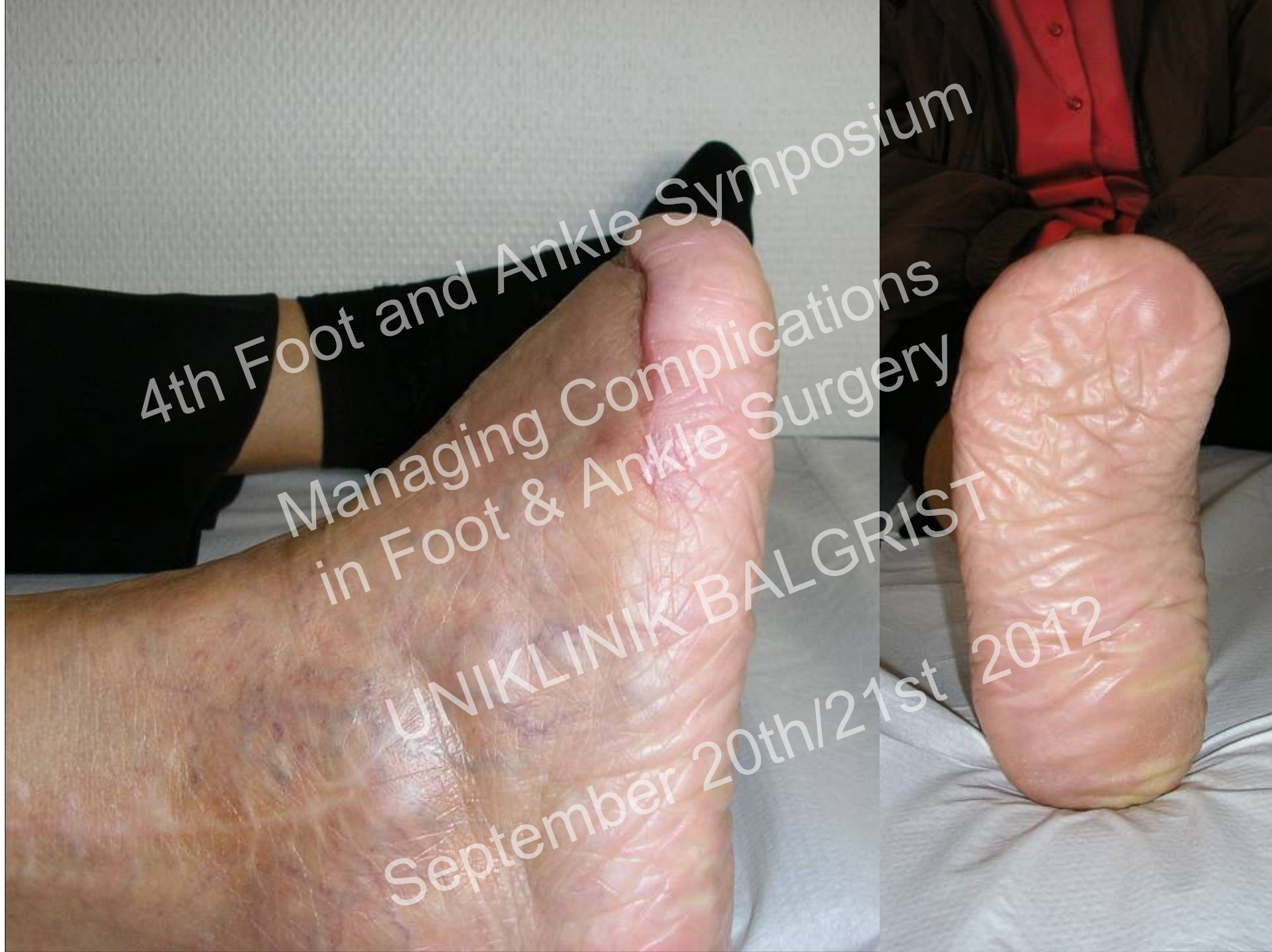September 20th/21st 2012

4th Foot and Ankle Symposium

Managing Complications
in Foot & Ankle Surgery

UNIKLINIK BALGRIST

September 20th/21st 2012

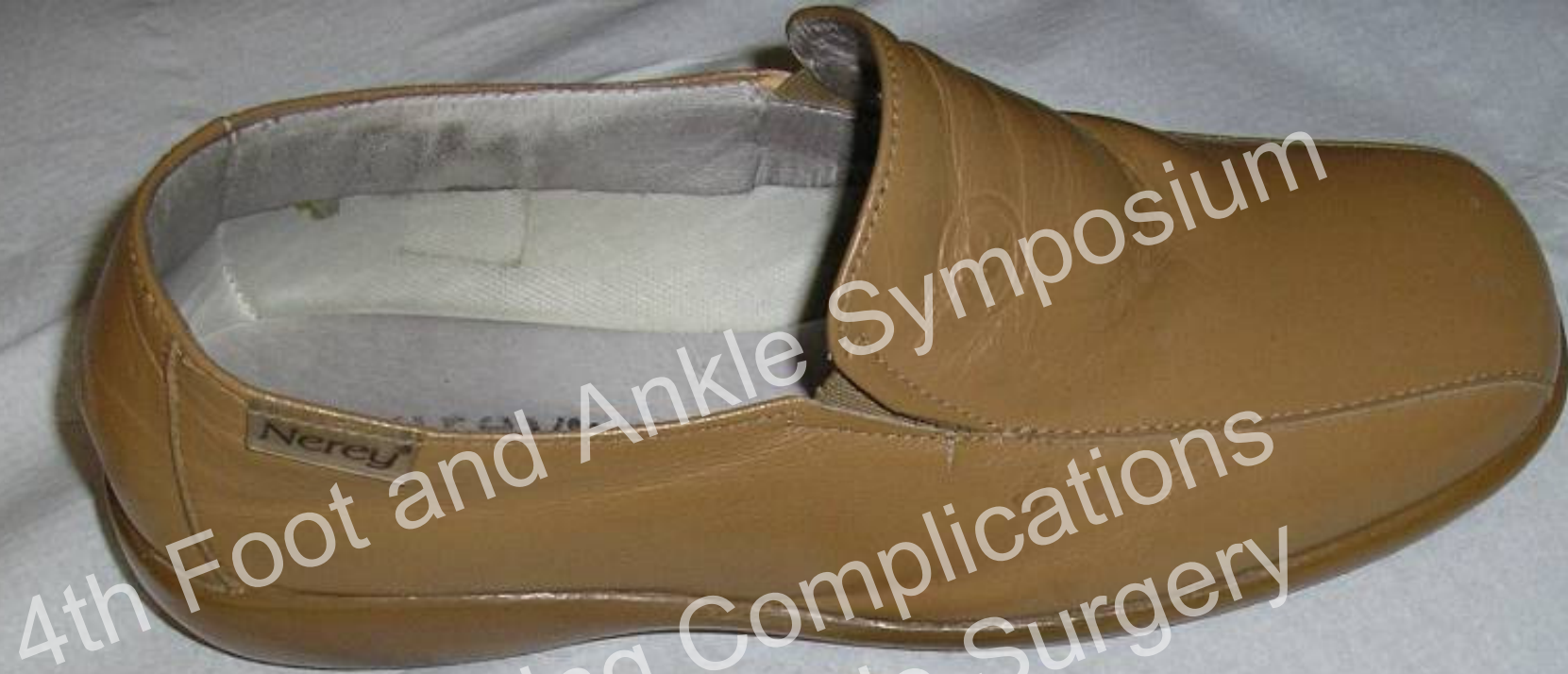

4th Foot and Ankle Symposium

Managing Complications
in Foot & Ankle Surgery

UNIKLINIK BALGRIST

September 20th/21st 2012



4th Foot and Ankle Symposium

Managing Complications
in Foot & Ankle Surgery

UNIKLINIK BALGRIST

September 20th/21st 2012

CONCLUSIONS

MP1 FUSIONS ARE ON THE RISE
COMPLICATIONS WILL BE ON THE RISE
SOME NONUNIONS ARE ASYMPTOMATIC

CONCLUSIONS

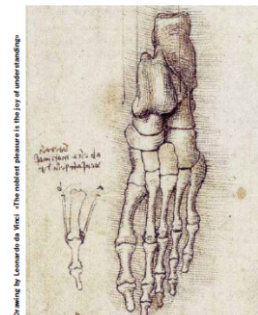
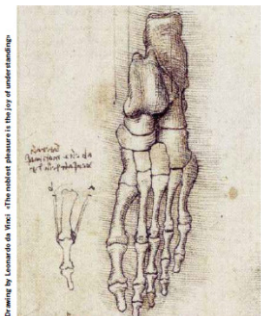
IF REVISION NEEDED:

ENSURE PROPER POSITIONING OF HALLUX

LENGTH 1ST RAY

LOCAL BONE FROM LESSER METATARSALS

NEW IMPLANTS ALLOW FOR INCREASED PRIMARY
STABILITY



THANK YOU FOR YOUR ATTENTION

4th Foot and Ankle Symposium
Managing Complications
in Foot & Ankle Surgery



UNIKLINIK BALGRIST
September 20th/21st 2012