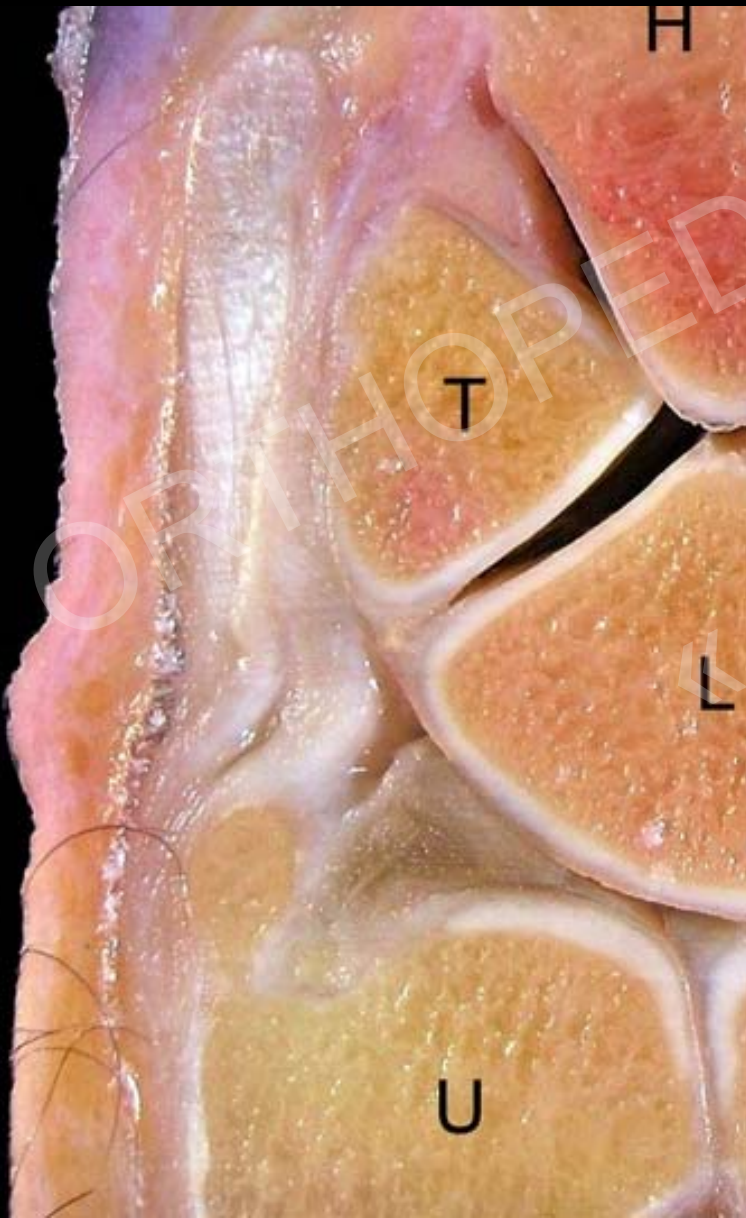

Orthopedics Update «Hand»

CT/MR Diagnostik an der Hand

Christian W. A. Pfirrmann
Orthopedic University Hospital Balgrist
University of Zurich Switzerland
christian.pfirrmann@balgrist.ch

Imaging of the Hand & Wrist

	Rx	US	MR	MR Arthro	MR iv Gad	CT	CT Arthro
TFC			**	***	**		**
Ligaments		**	**	***	**		**
Cartilage			**	***	**		***
Bone Fracture	***		**			***	
Bone AVN	**				***		
Tendon		***	***				
Ganglion		***	***				
Inflammatory	**	***			***		
Tumors		*			***		
Nerves		***	**		**		

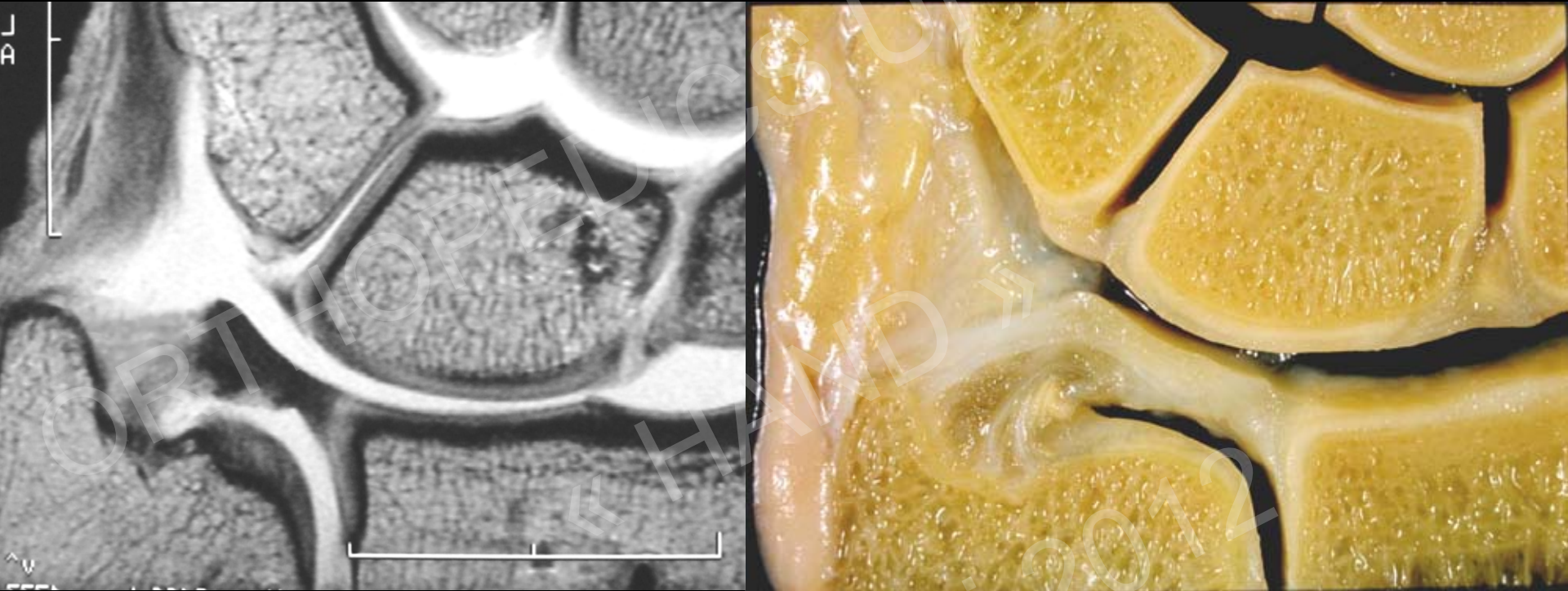
TFC

Imaging modality of choice:

1. MR Arthrography (With injection of DRUG)
2. MR / MR with iv Gadolinium
3. CT Arthrography



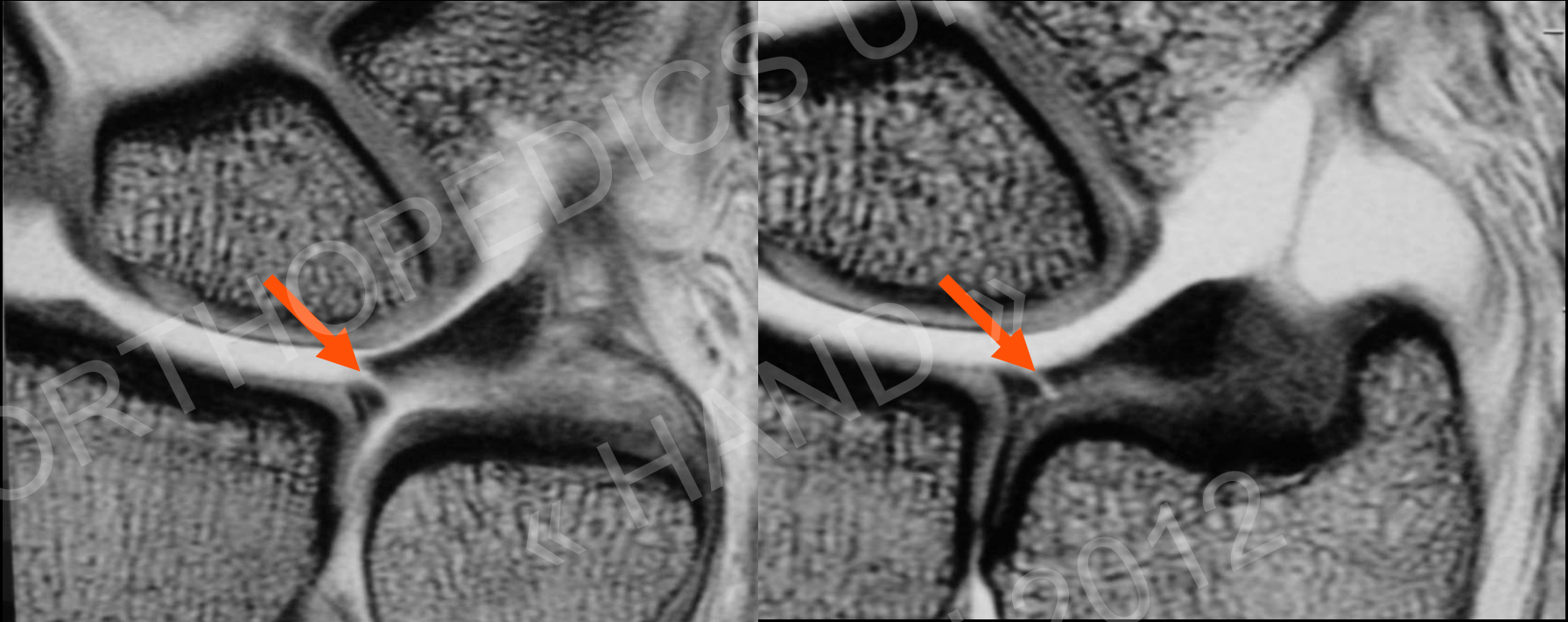
TFC: MR Arthrography Coronal Plane



TFC: Ulnar attachment: Hyper - isointens signal, 2 parts:

- horizontal: styloid process
- vertical: ulnar fovea
- separated by the „ligamentum subcruentum“ (vascularized)

TFC-Tear

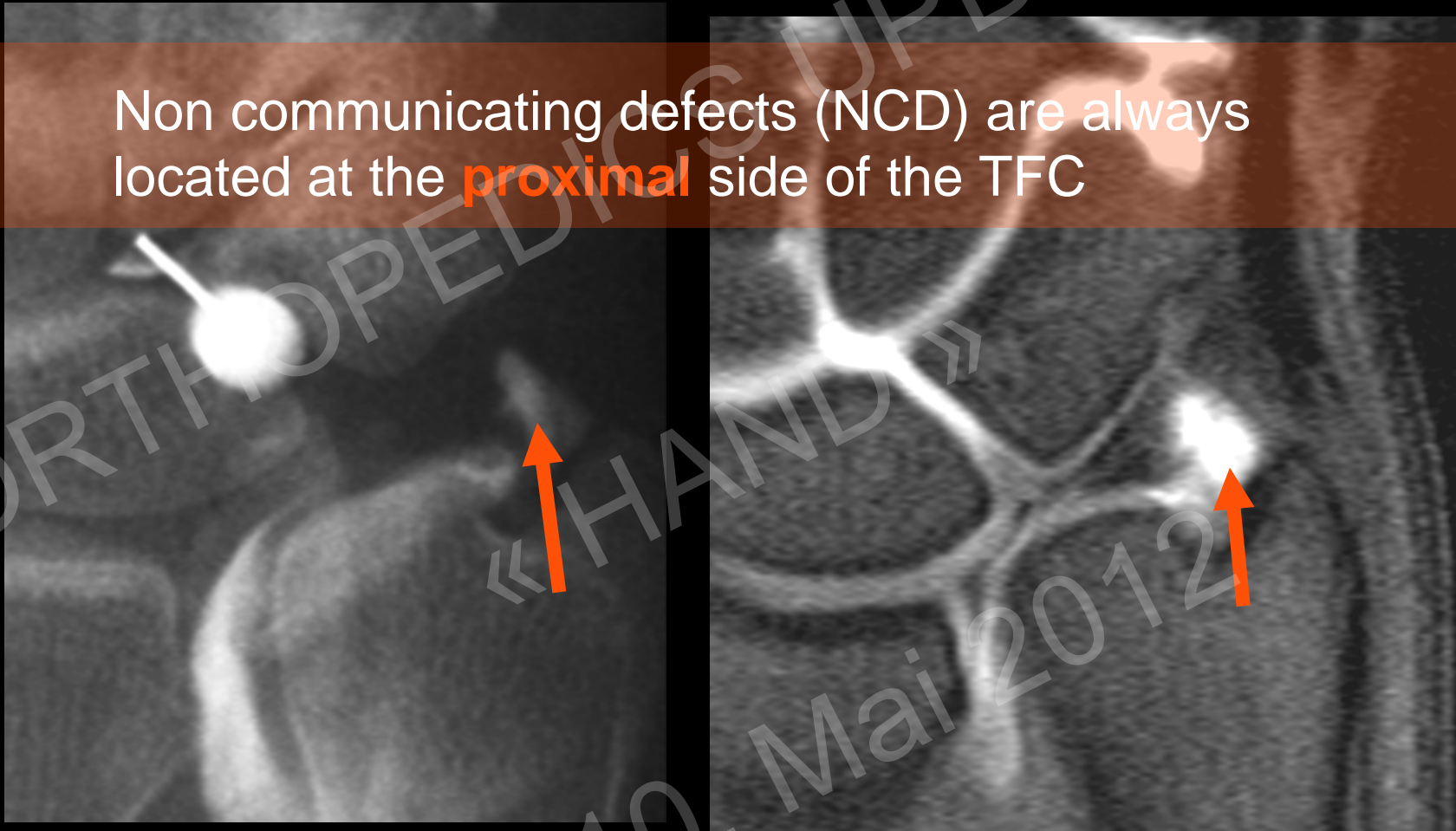


Central perforation

10. Mai 2012

Communicating vs Non communicating

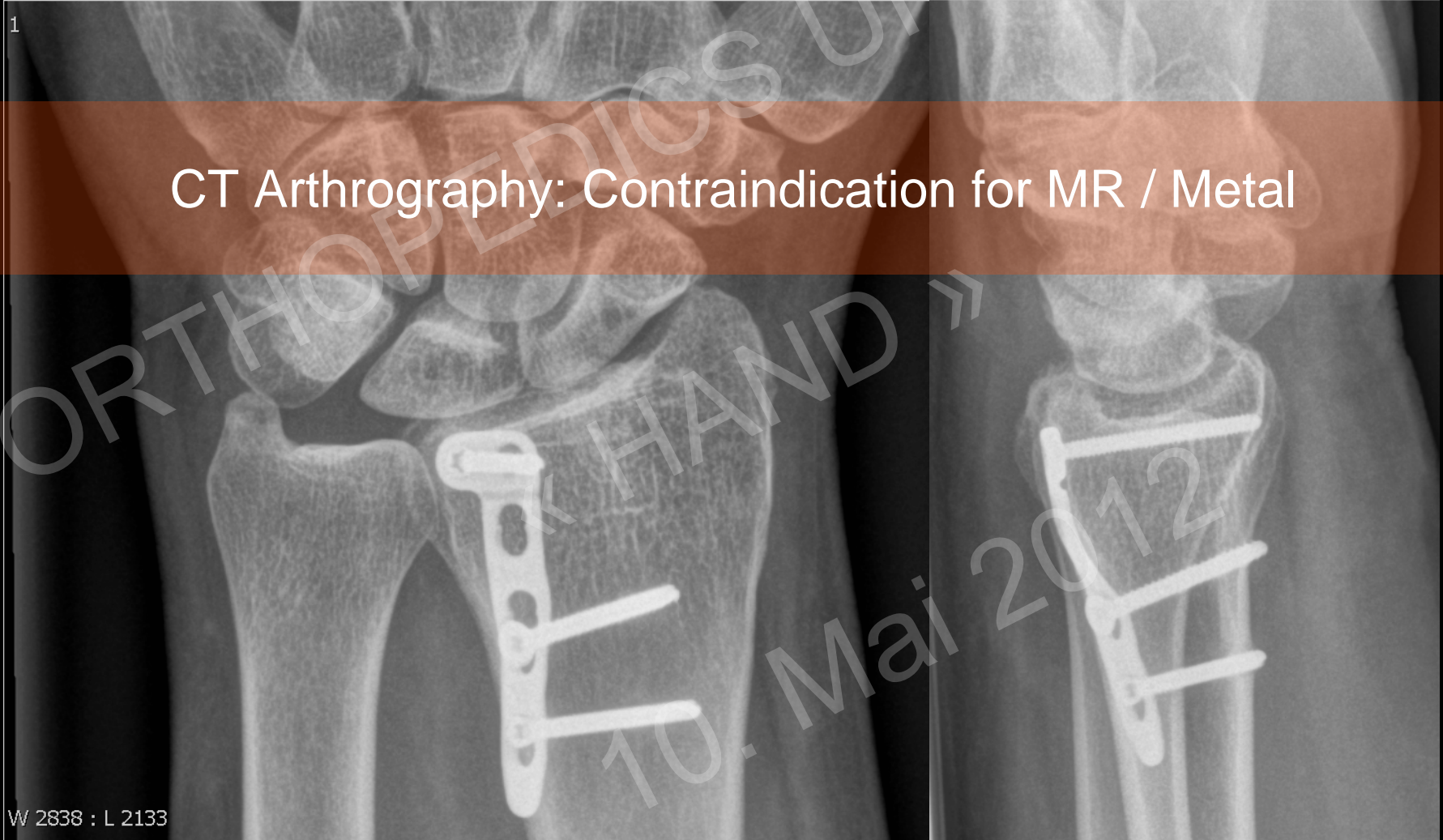
Non communicating defects (NCD) are always located at the **proximal** side of the TFC



=> Direct arthrography of the DRUG helps to diagnose NCDs

TFC: CT Arthrography

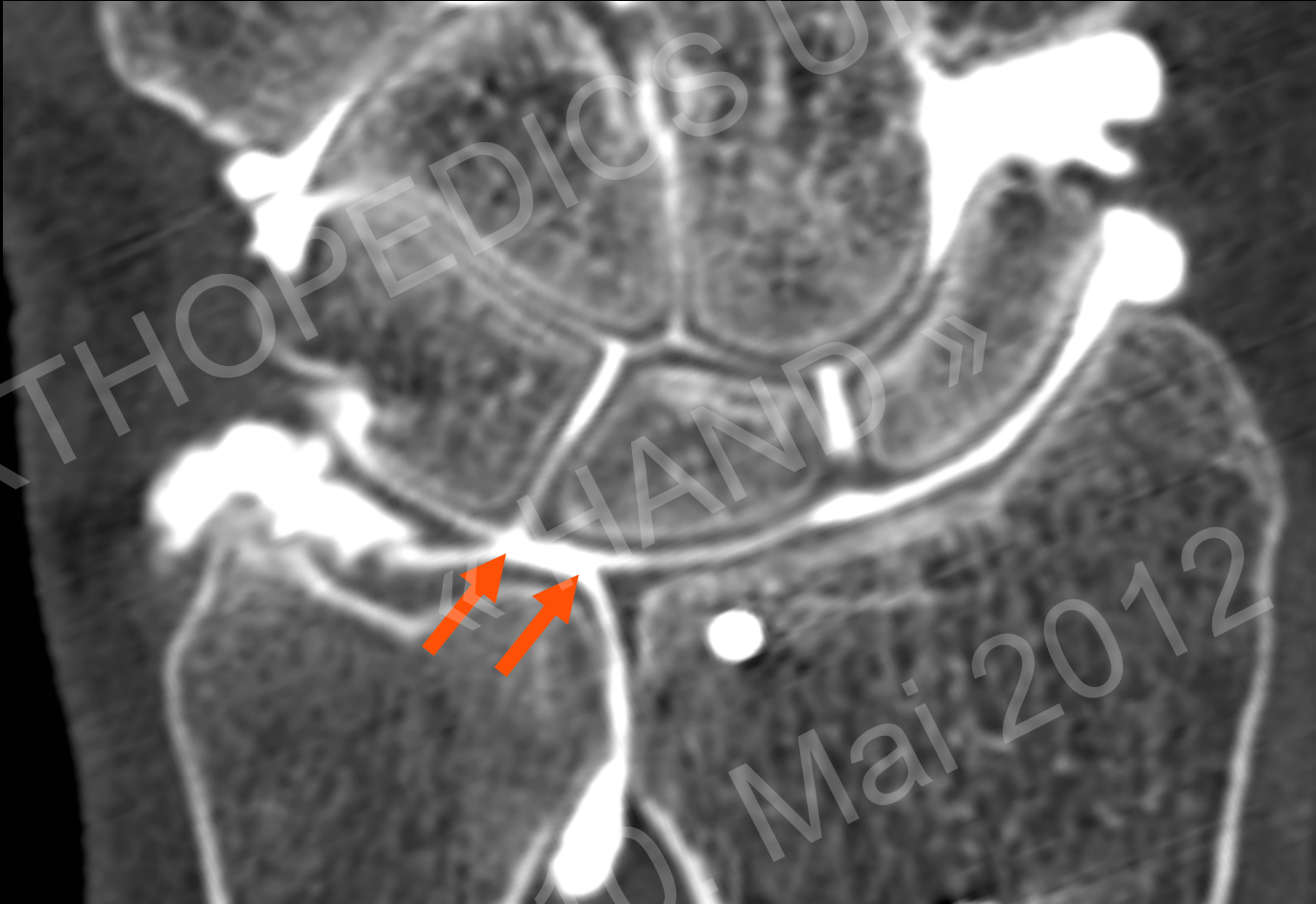
CT Arthrography: Contraindication for MR / Metal



W 2838 : L 2133



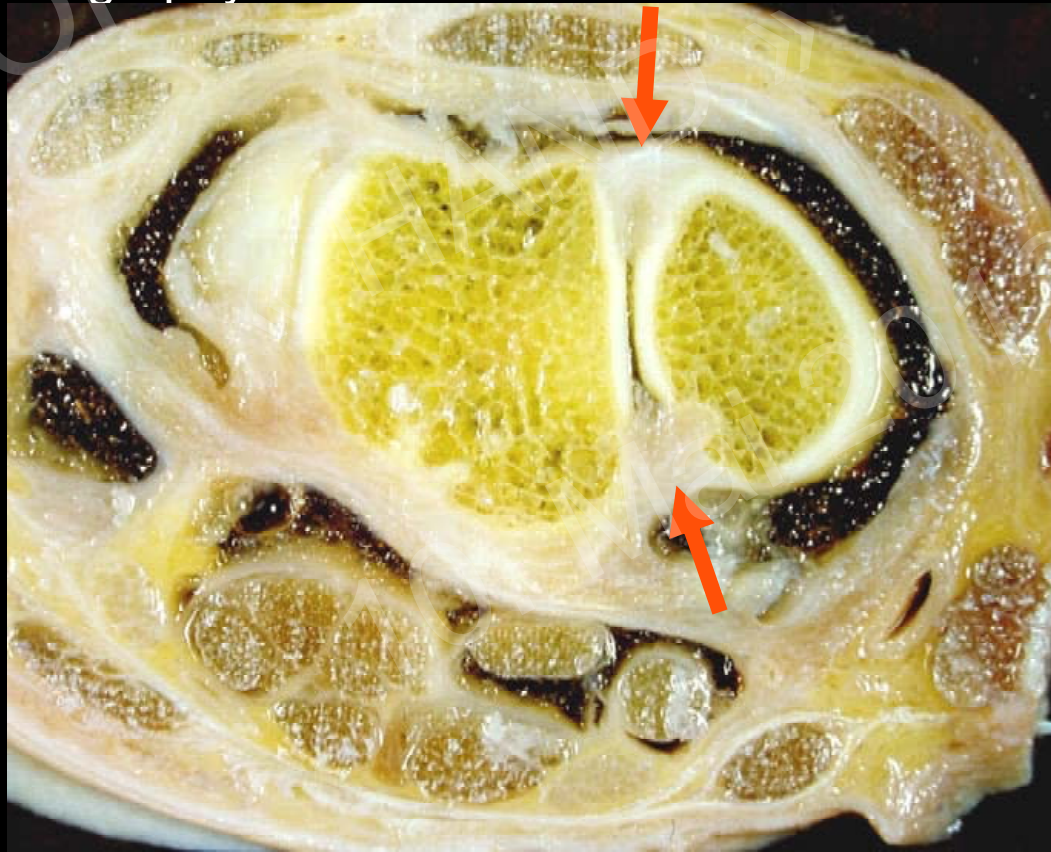
TFC: CT Arthrography



Interosseous Ligaments

Imaging modality of choice:

1. MR Arthrography
2. US, MR / MR with iv Gadolinium
3. CT Arthrography



Interosseous Ligaments

3 Components (U-Form):

Proximal part (membranaceous/thin)

biomechanically not relevant

communications frequent

frequency increases with age

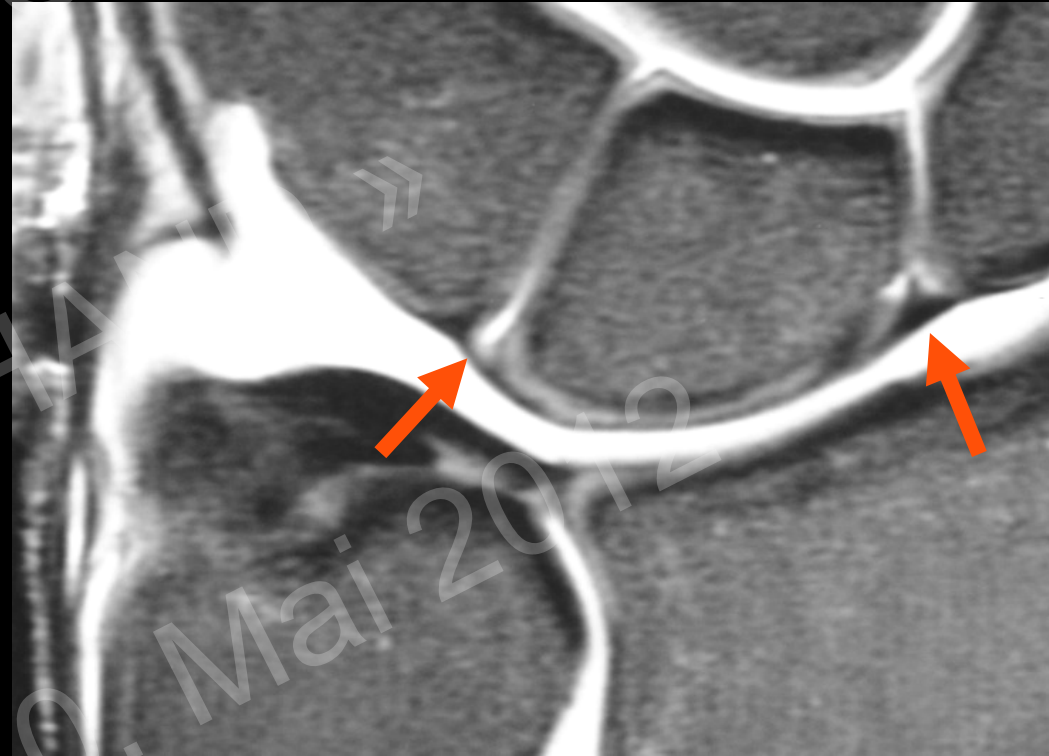may be asymptomatic

Dorsal part (thick)

biomechanically important

Palmar part (thick)

biomechanically important



Interosseous Ligaments

3 Components (U-Form):

Proximal part (membranaceous/thin)

biomechanically not relevant

communications frequent

frequency increases with age

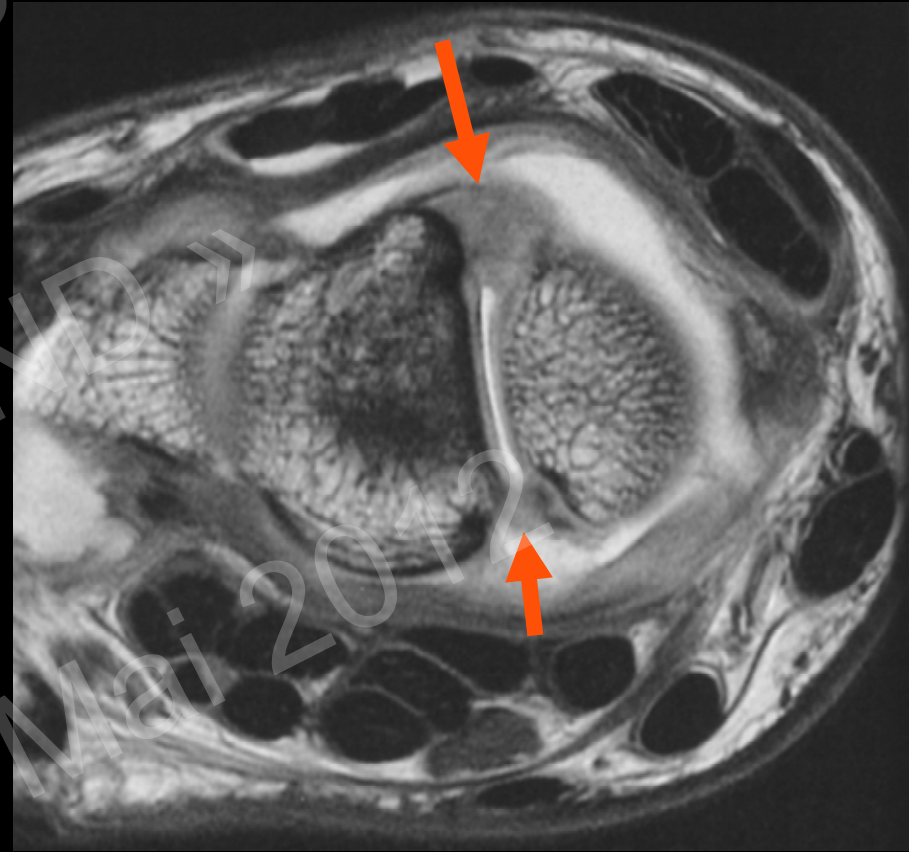may be asymptomatic

Dorsal part (thick)

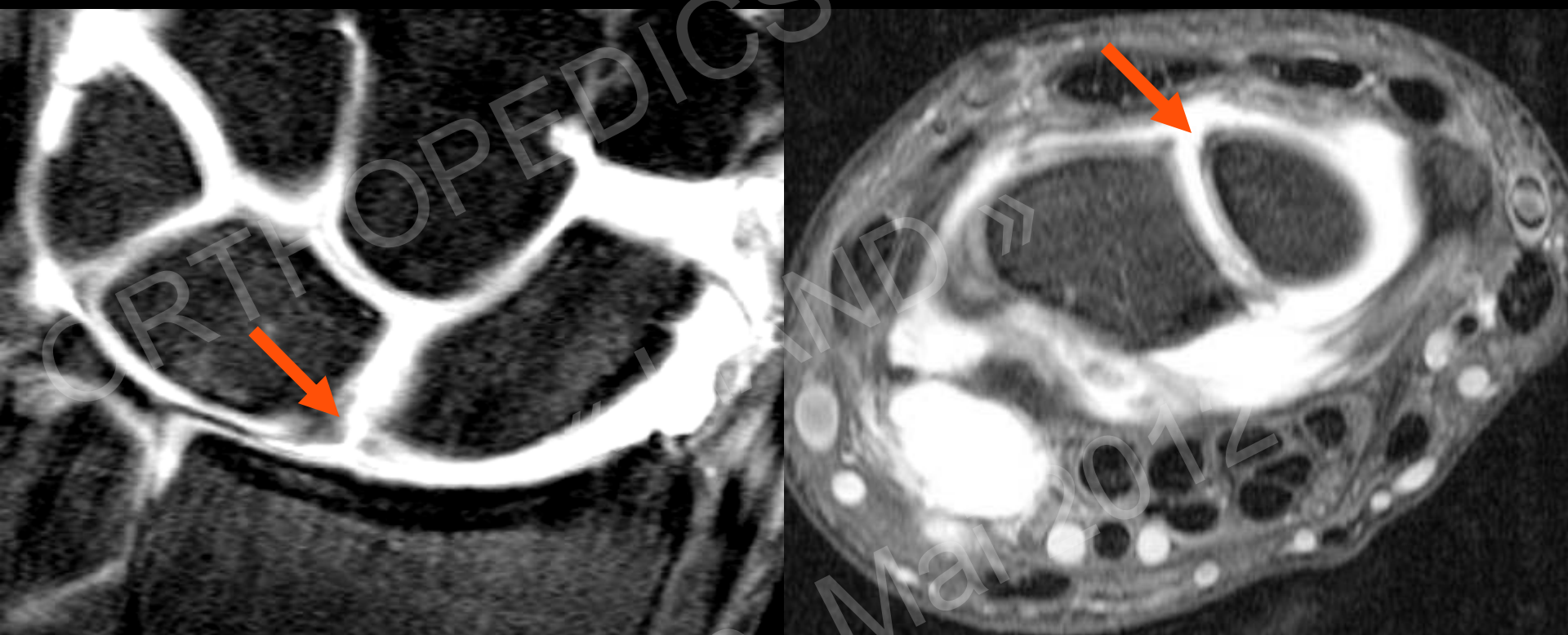biomechanically important

Palmar part (thick)

biomechanically important

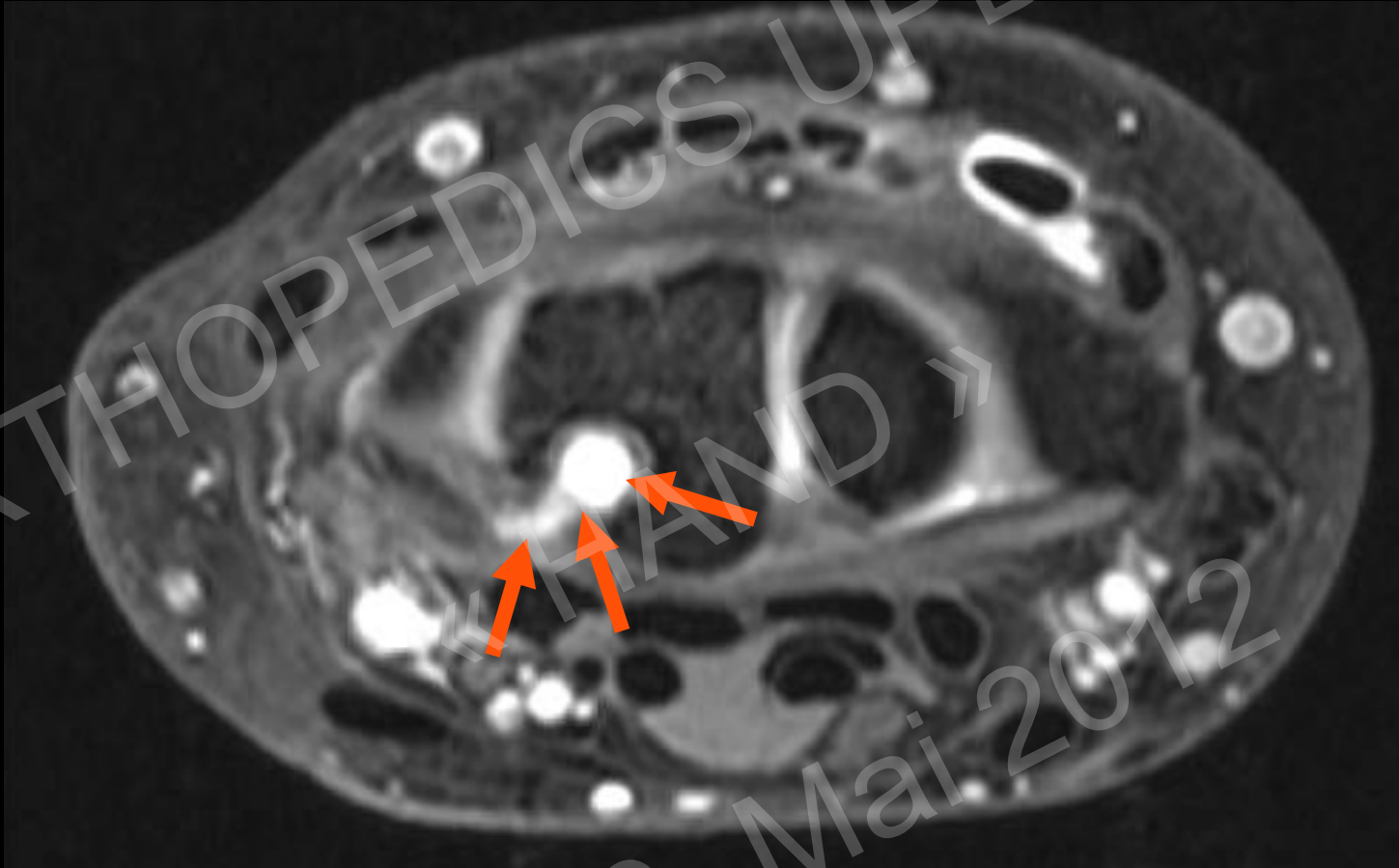


SL Ligament



SL Ligament Tear

LT-Ligament

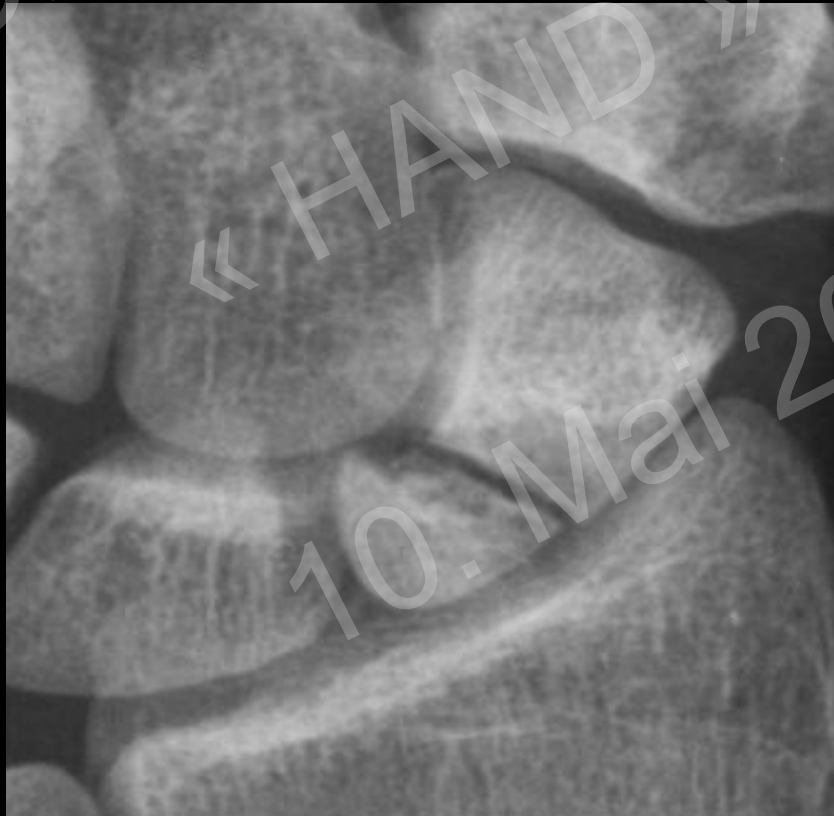

Intraosseous ganglion from palmar part of LT Ligament

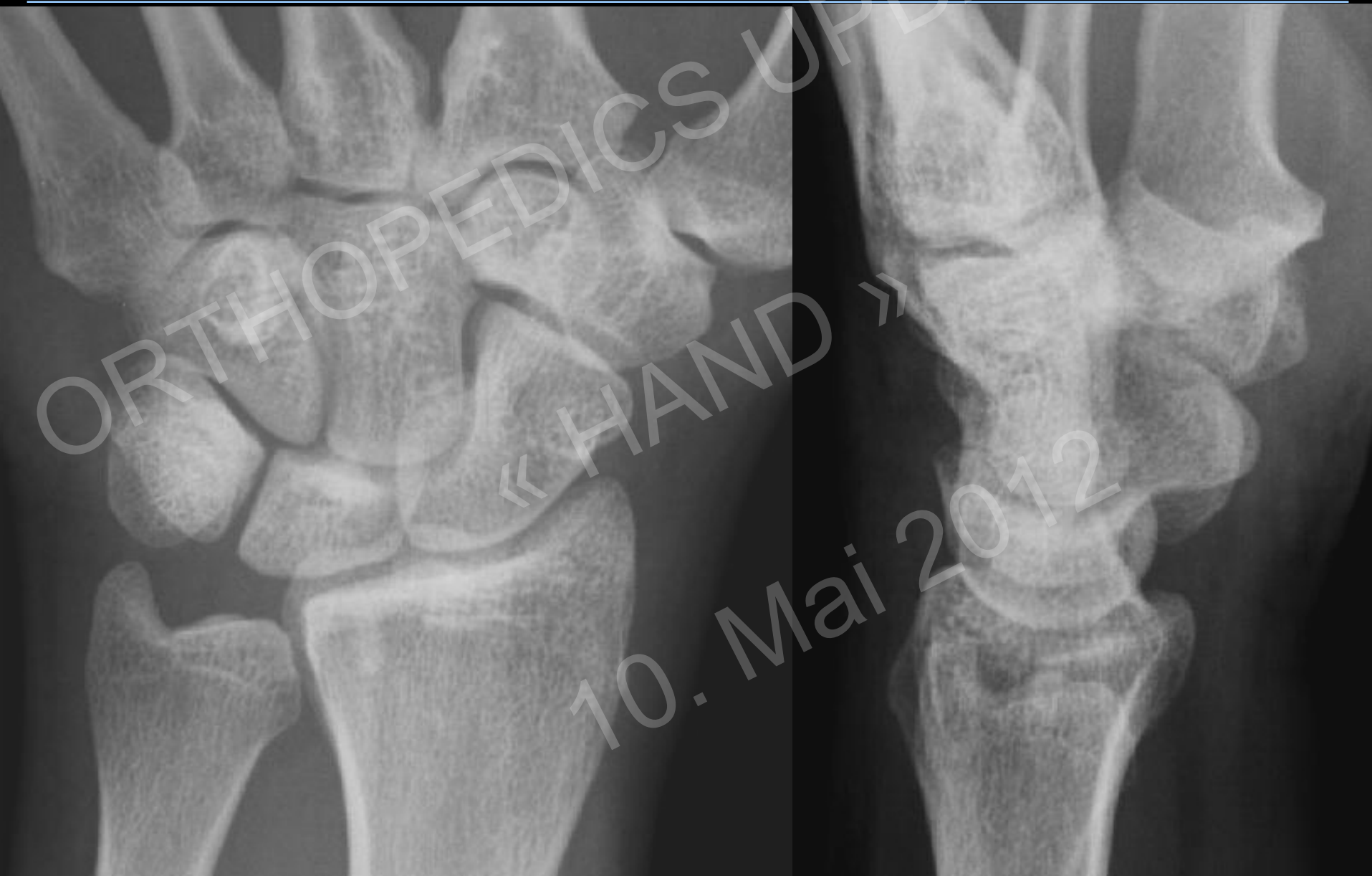Fracture

Imaging modality of choice:

1. Rx
2. CT
3. MR



Trauma: Fracture?



Trauma: Fracture?

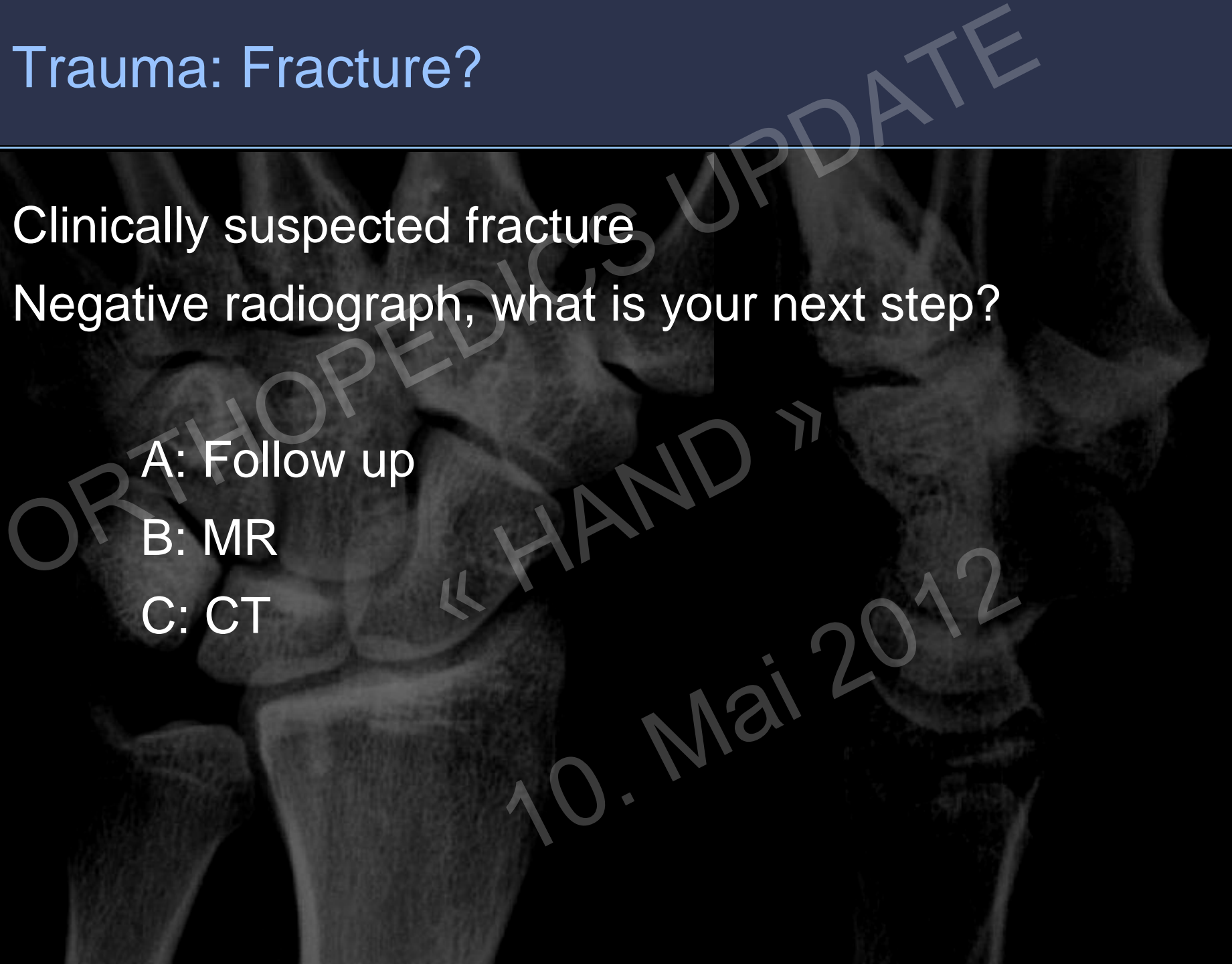
Clinically suspected fracture

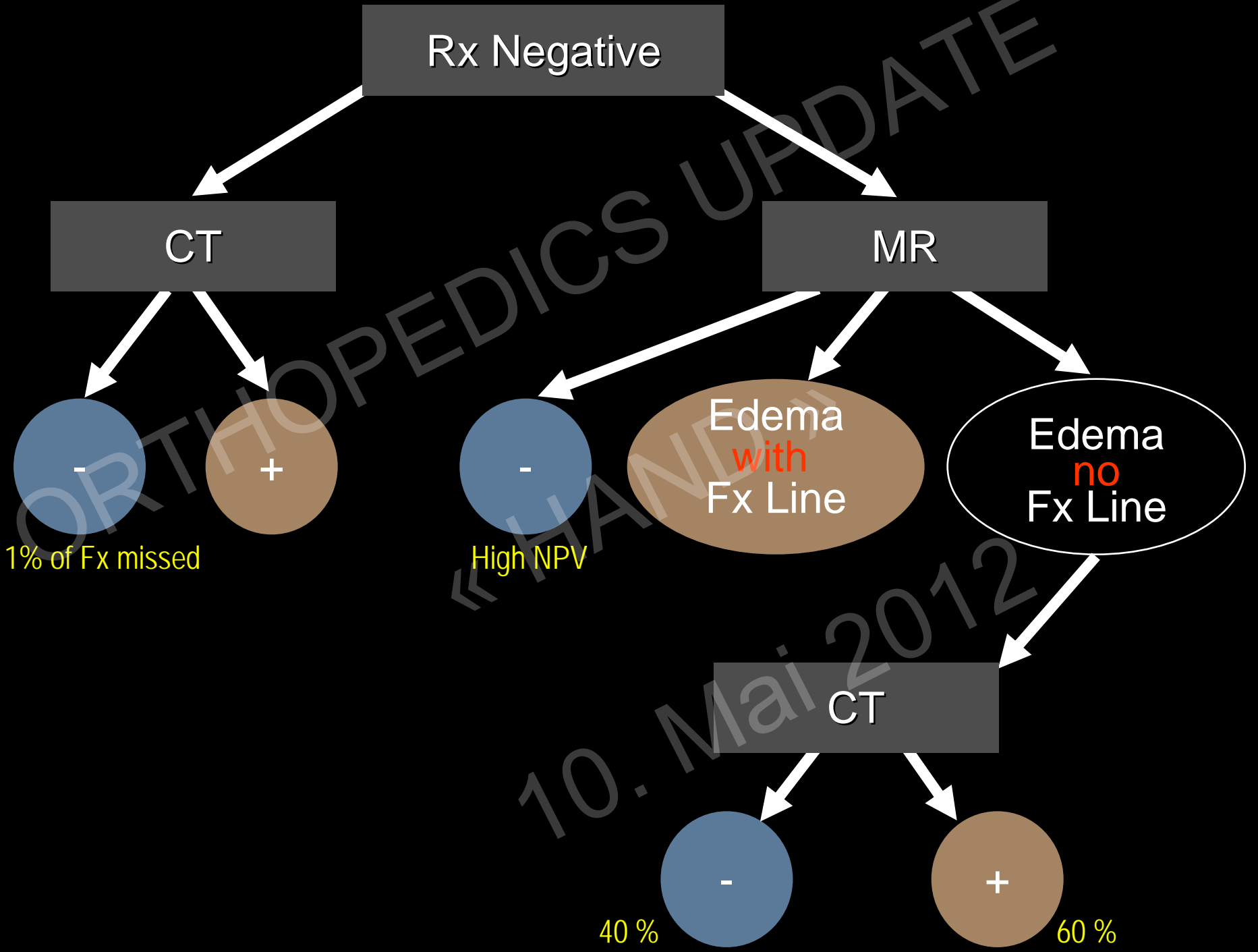
Negative radiograph, what is your next step?

A: Follow up

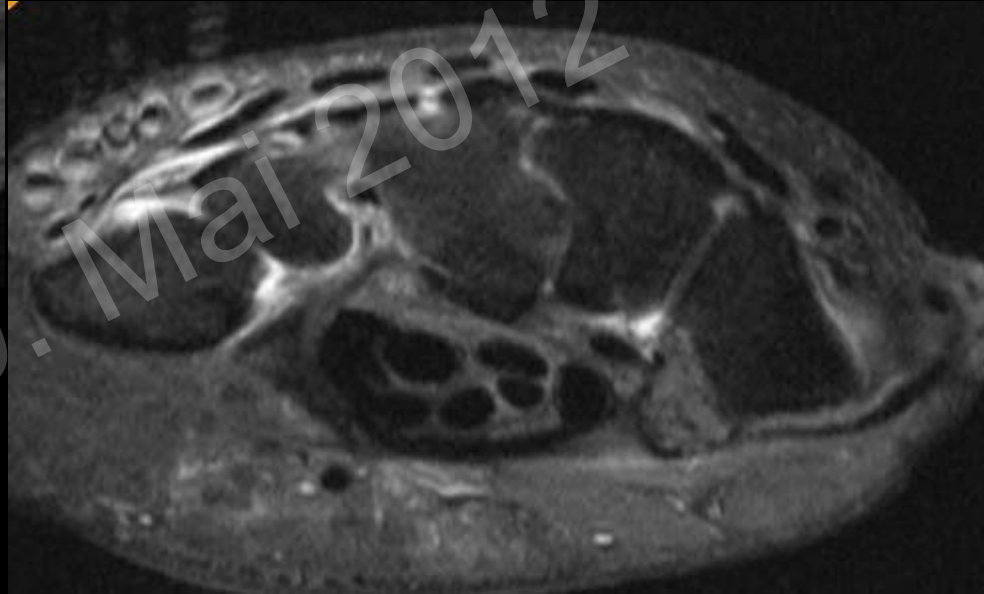
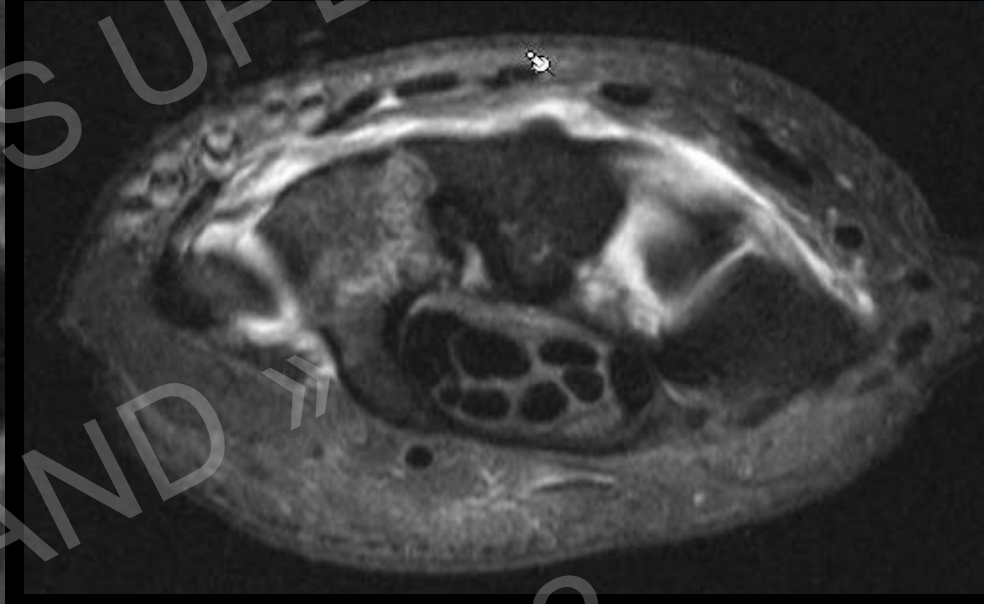
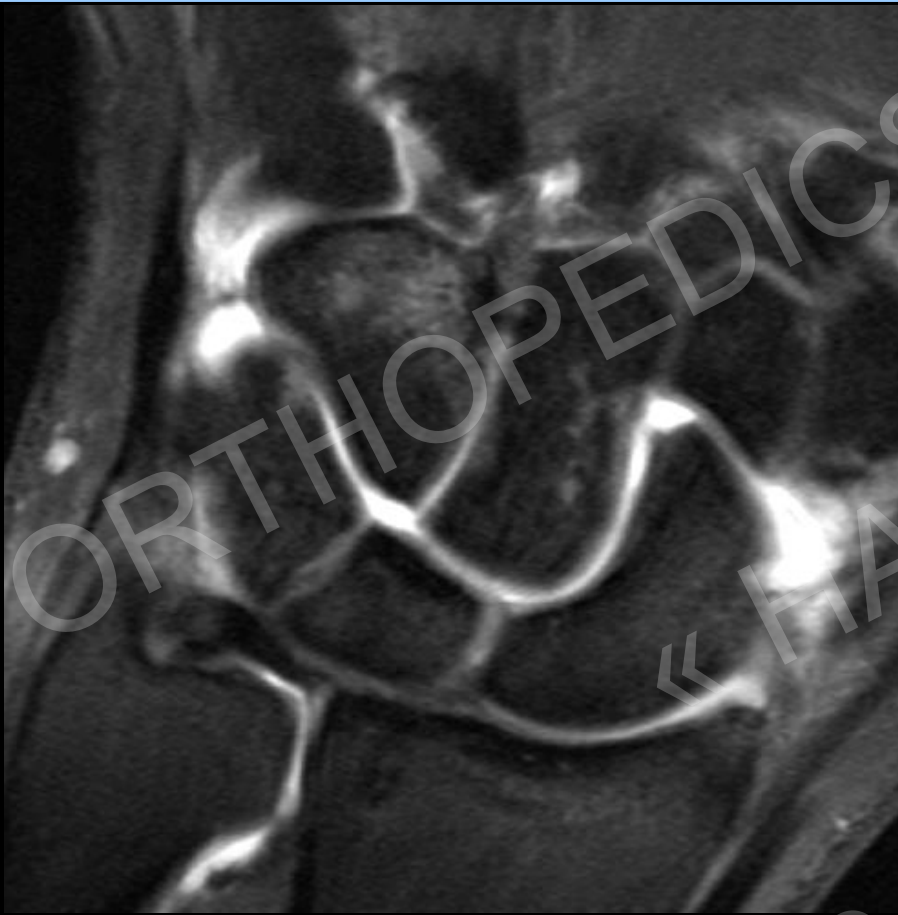B: MR

C: CT

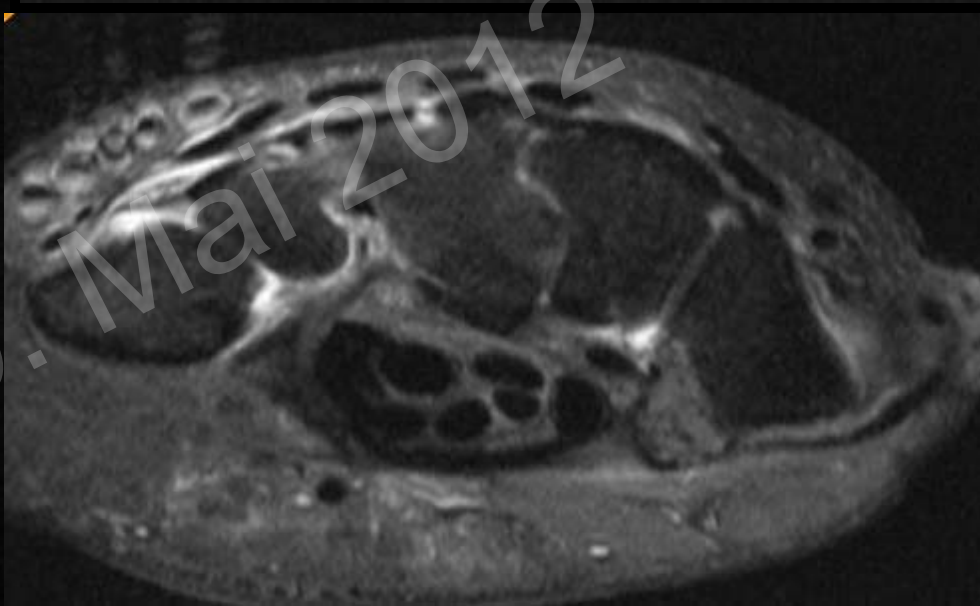
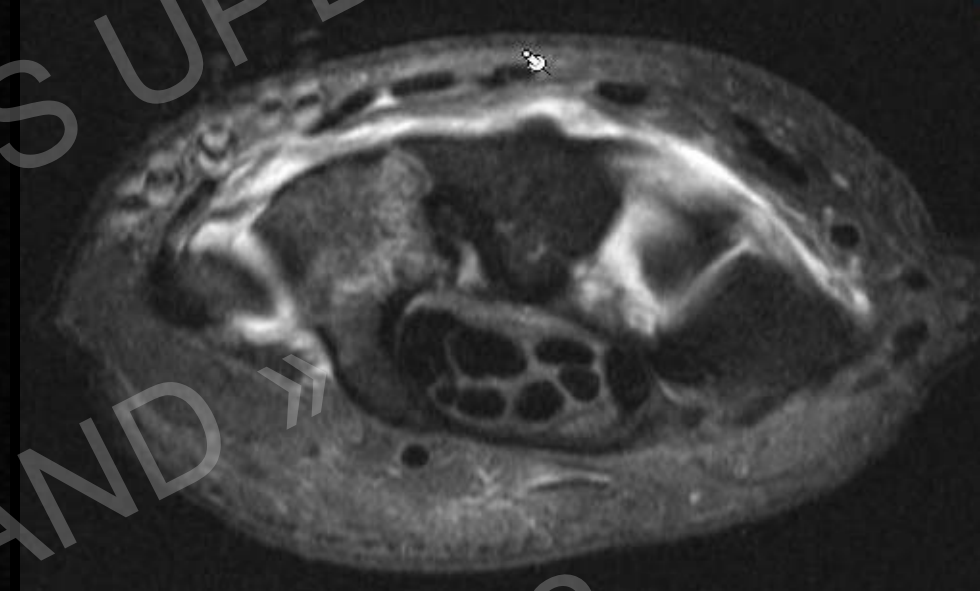
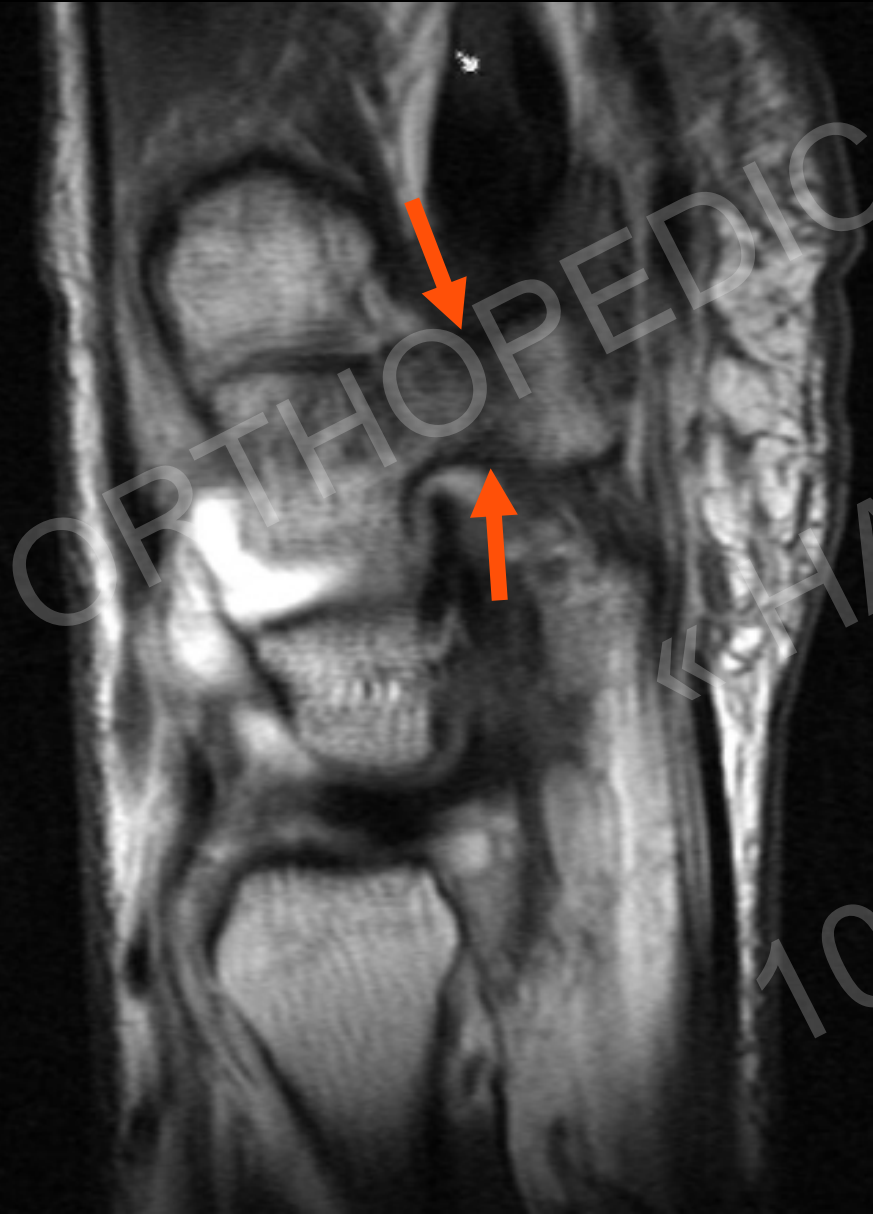



Trauma: Fracture?

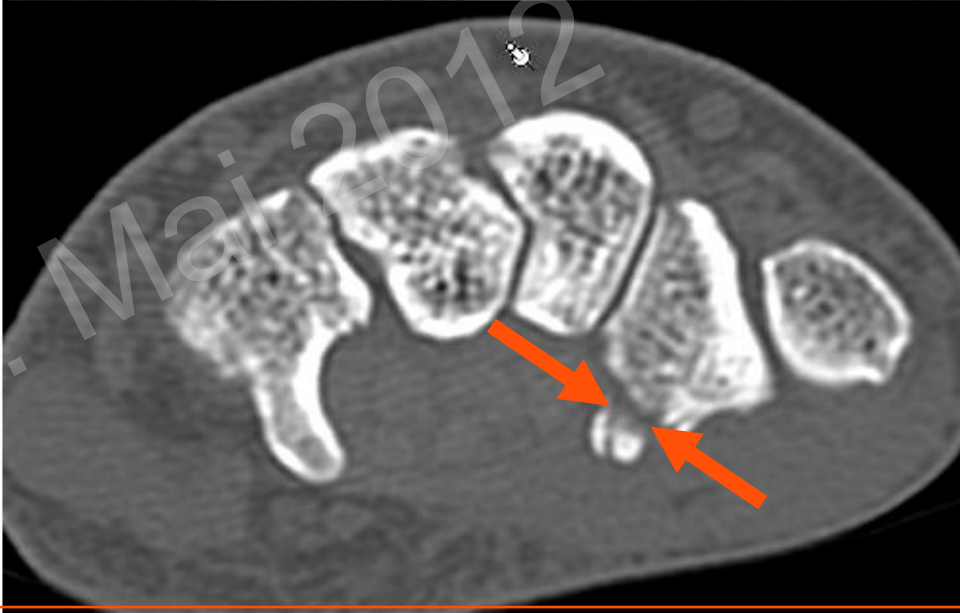
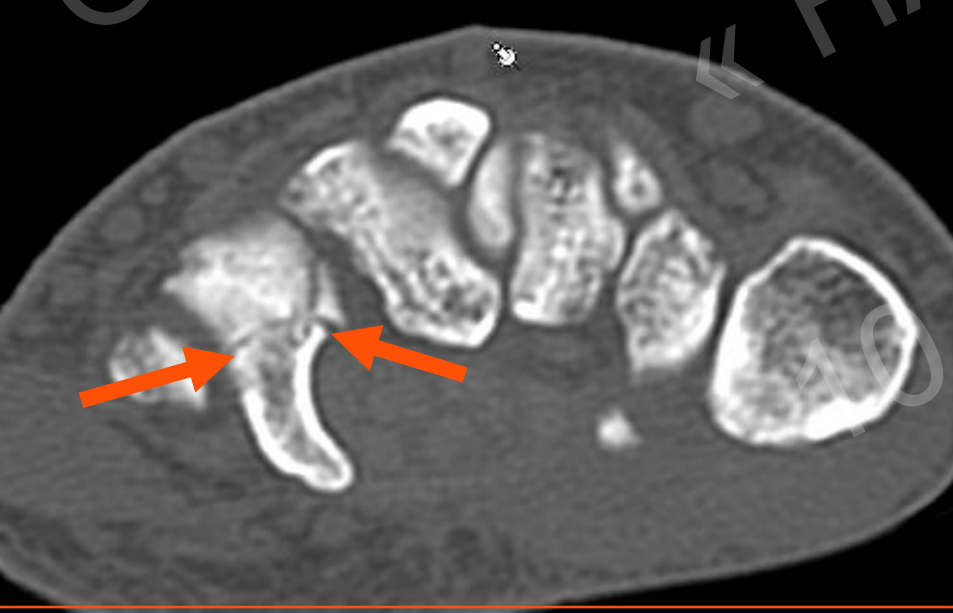
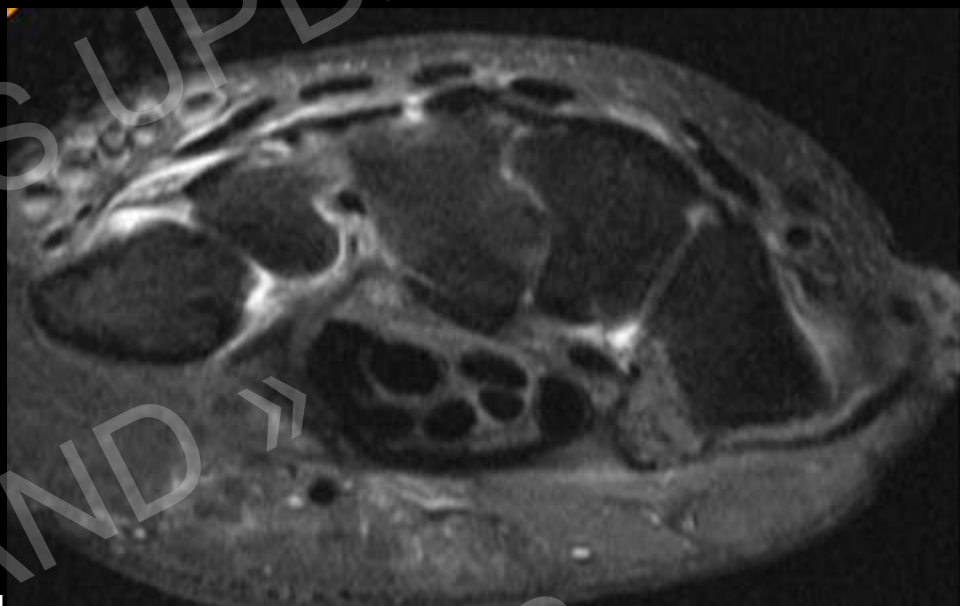
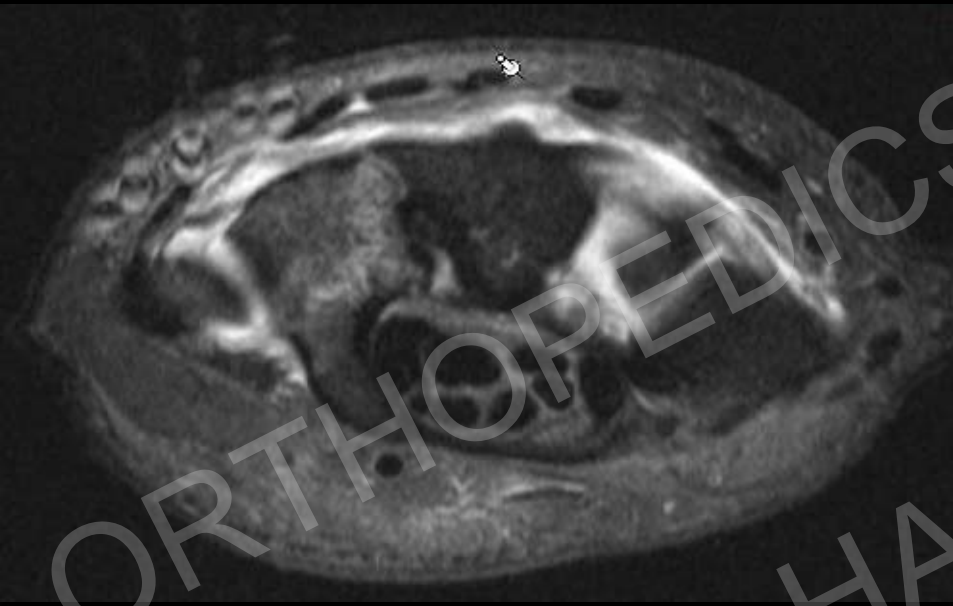


Trauma: Fracture?



ORTHOPEDICS UPDATE
«HAND»
10. Mai 2012

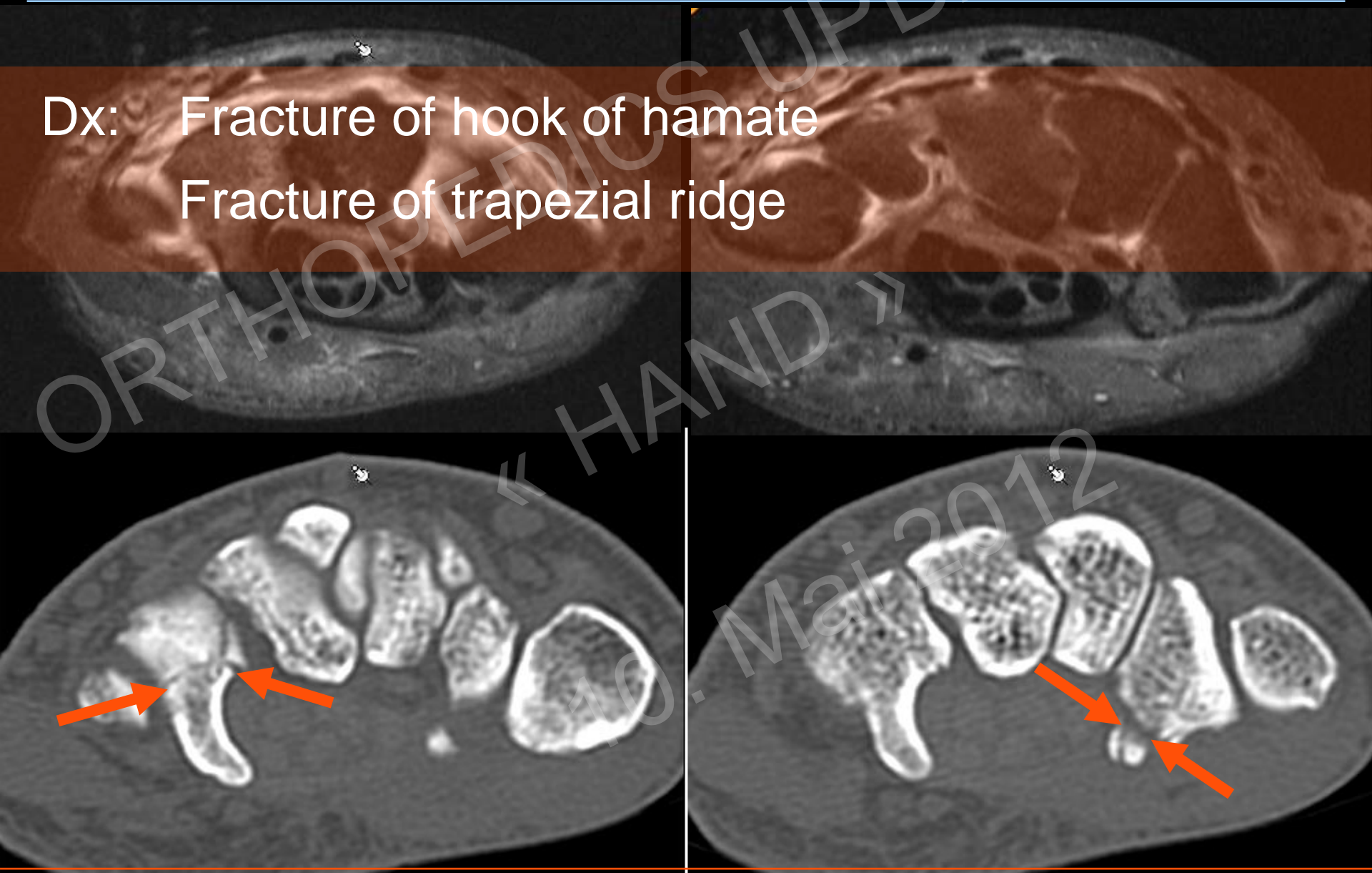
Trauma: Fracture?



ORTHOPEDICS UPDATE
« HAND »
10. Mai 2012

Trauma: Fracture?

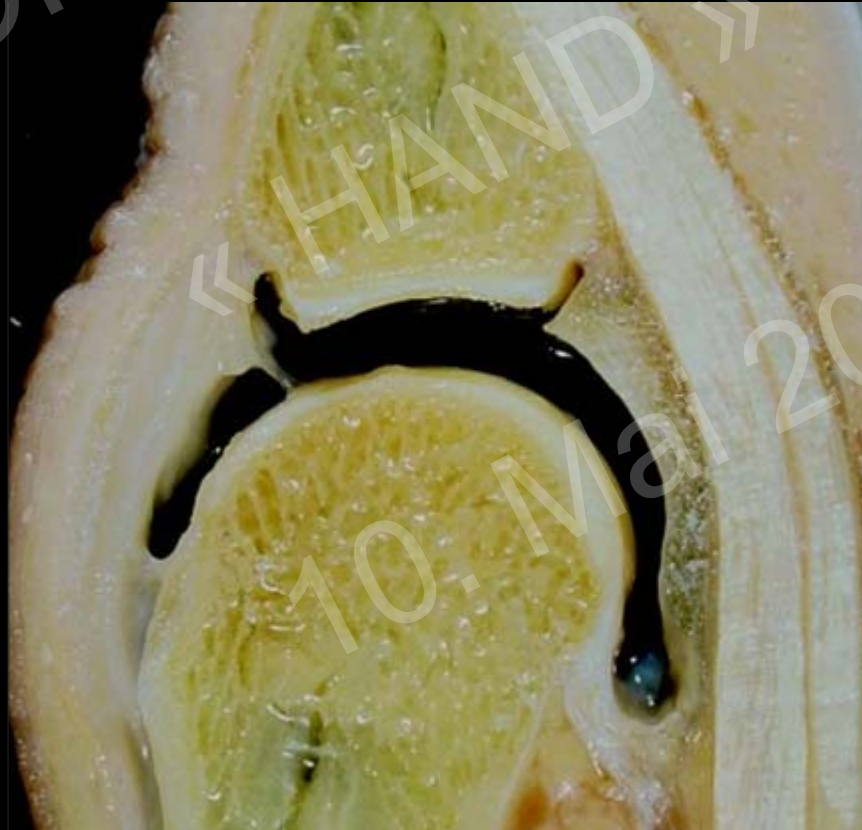
Dx: Fracture of hook of hamate
Fracture of trapezoidal ridge



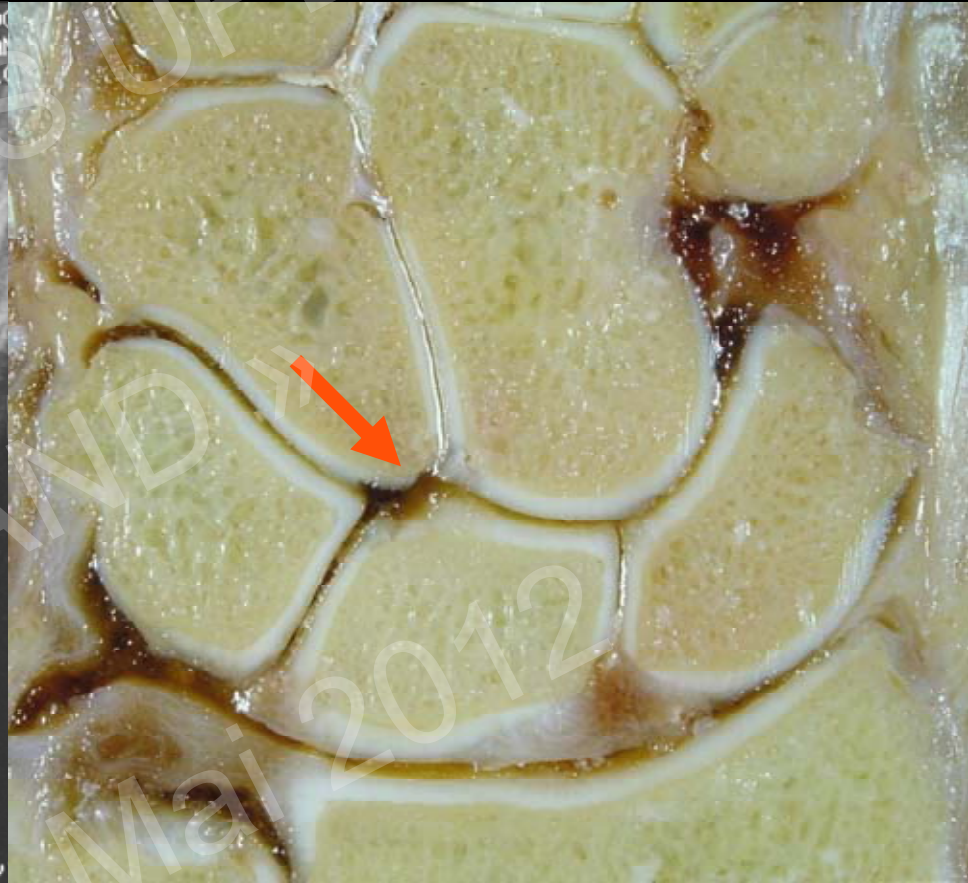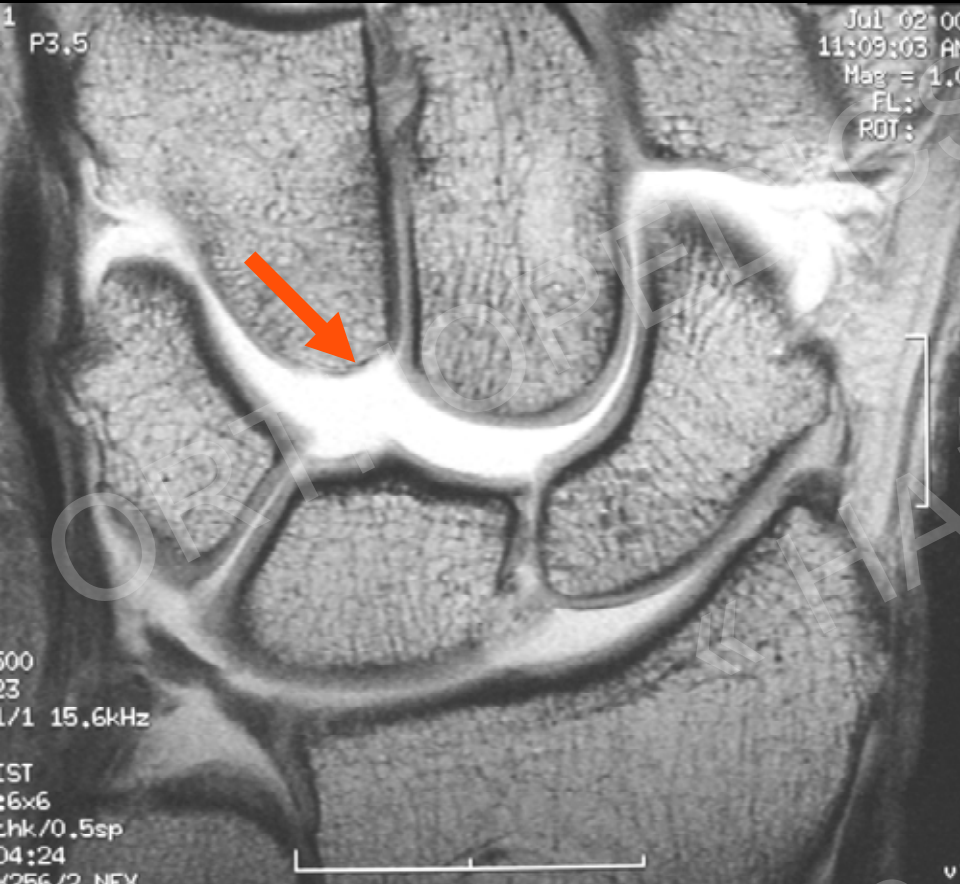
Cartilage

Imaging modality of choice:

1. CT Arthrography - MR Arthrography
2. MR

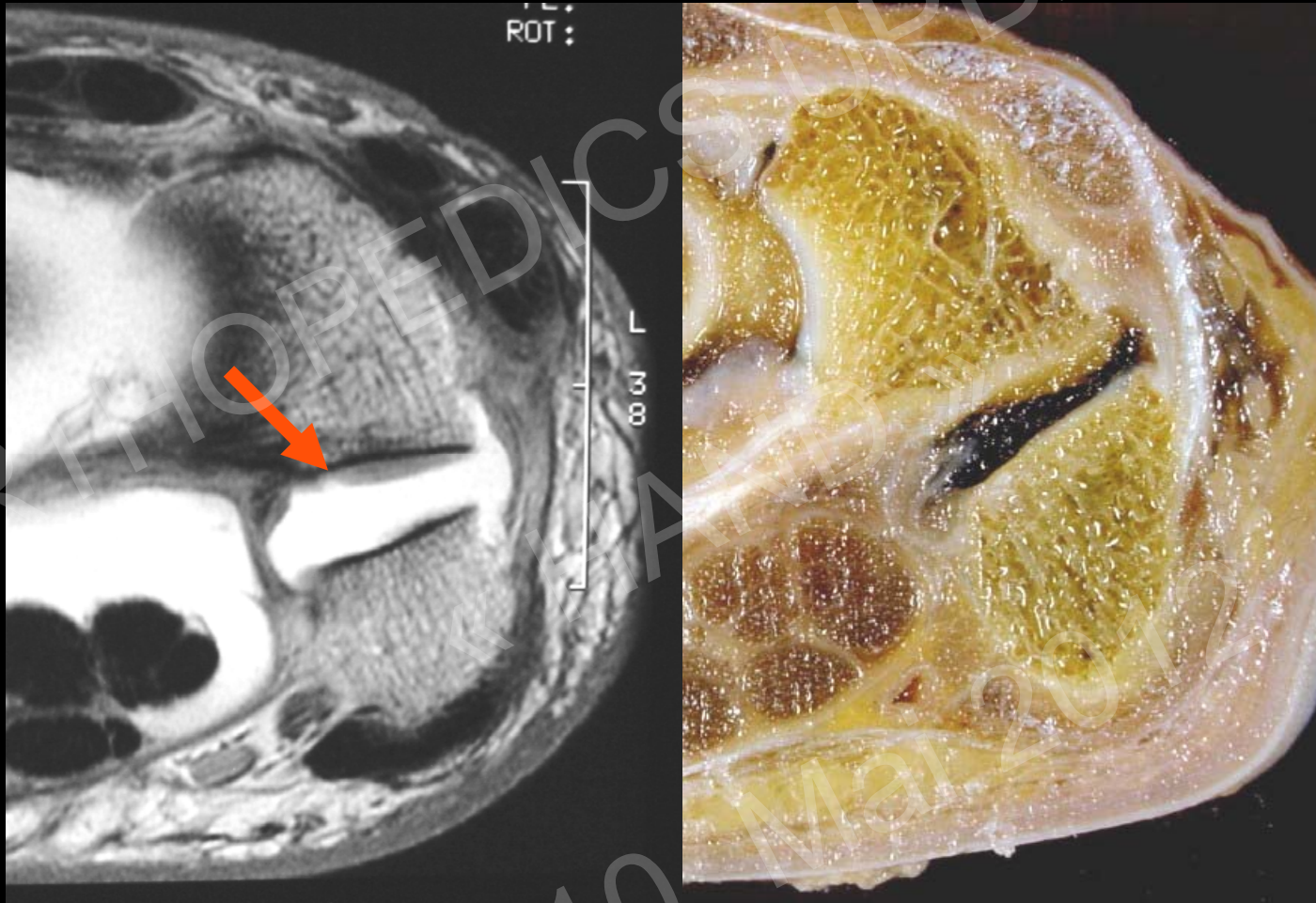


Osseous Anatomy : Typ II Lunate



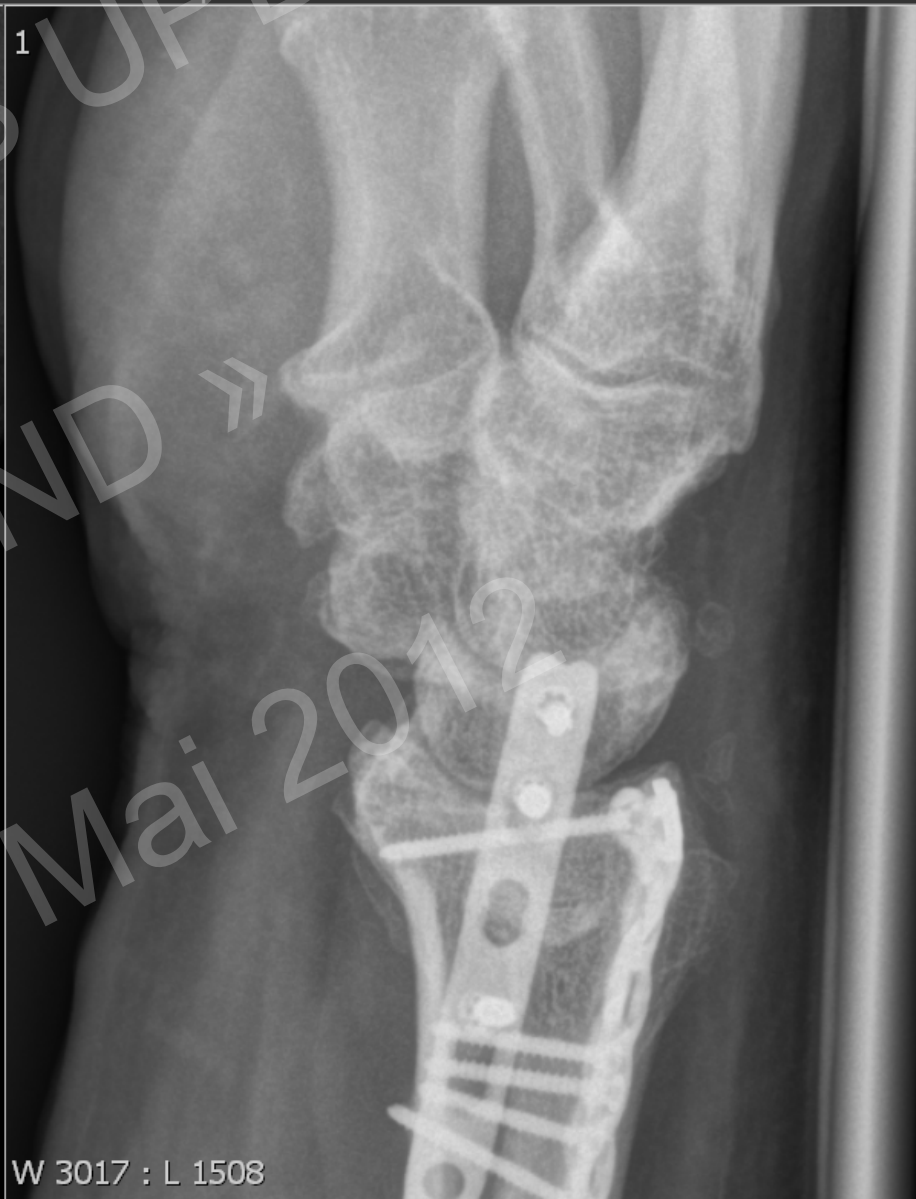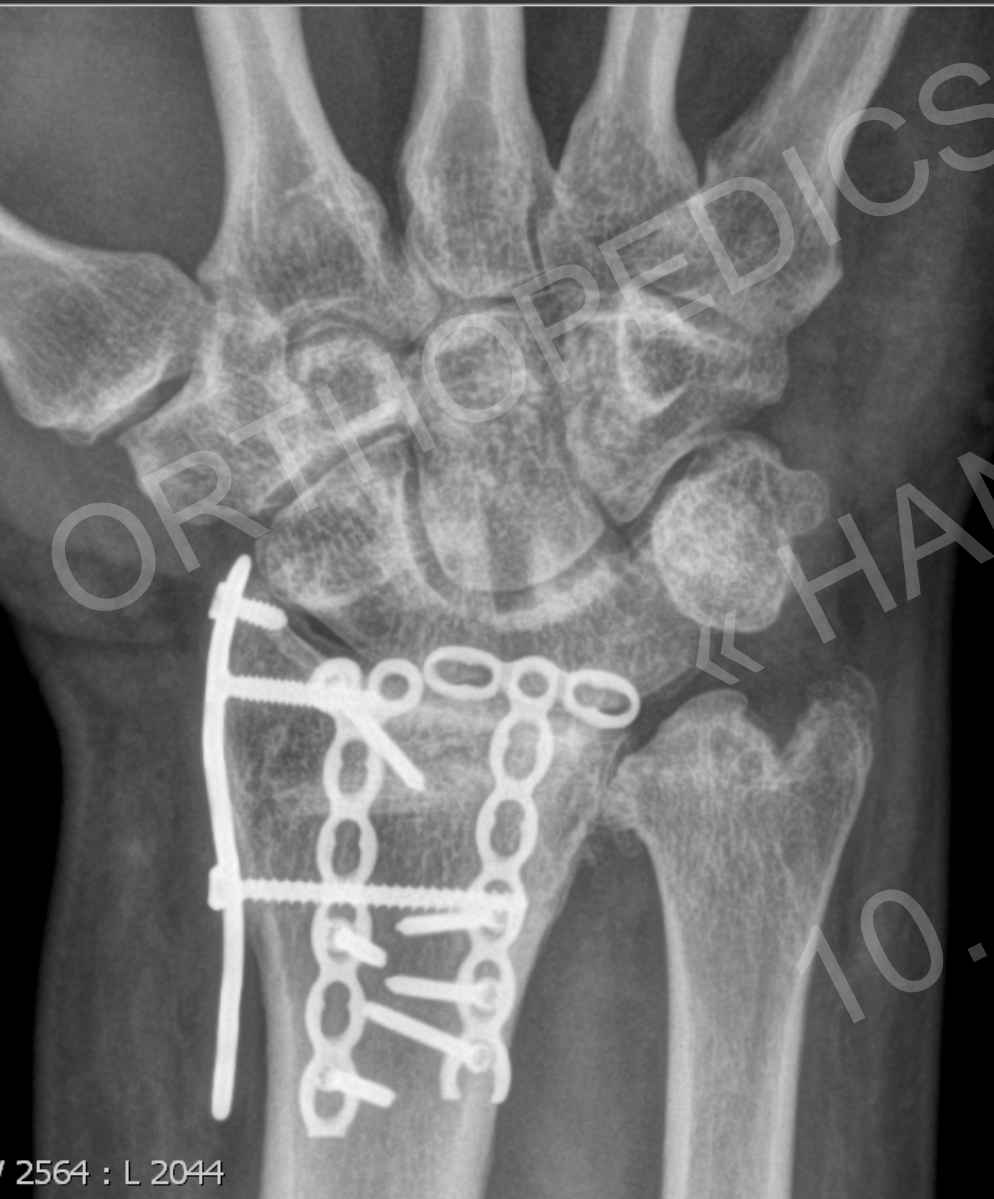Hamate-lunate facet / Type II lunatic

The PISO Triquetral Joint

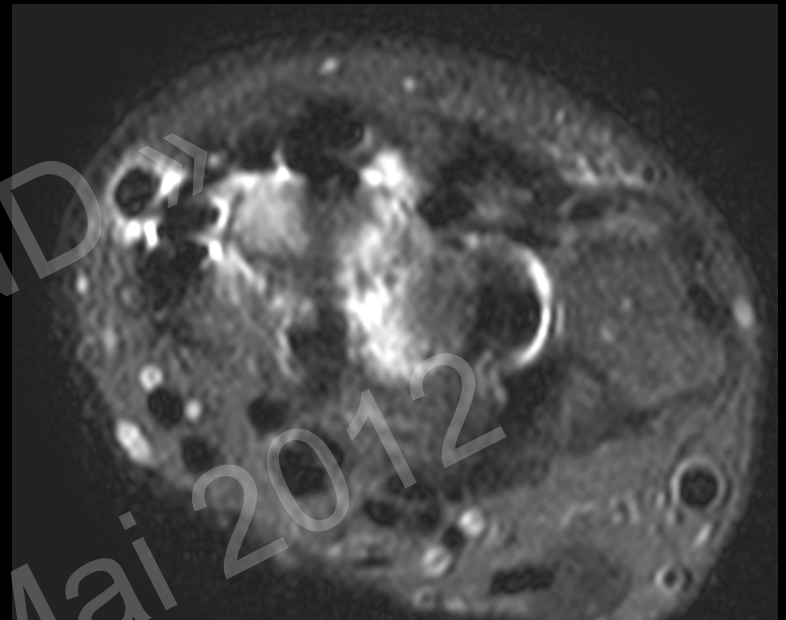
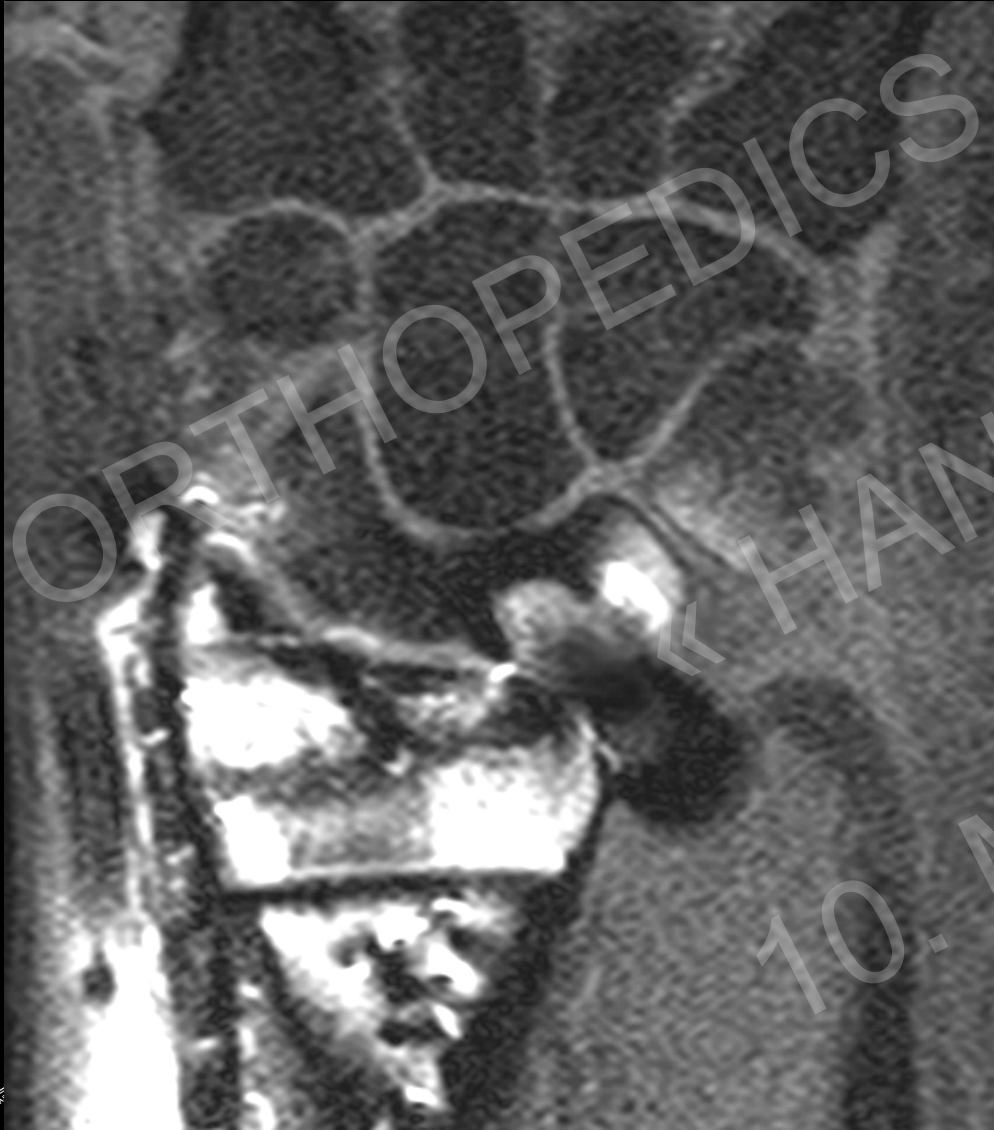

OA very common

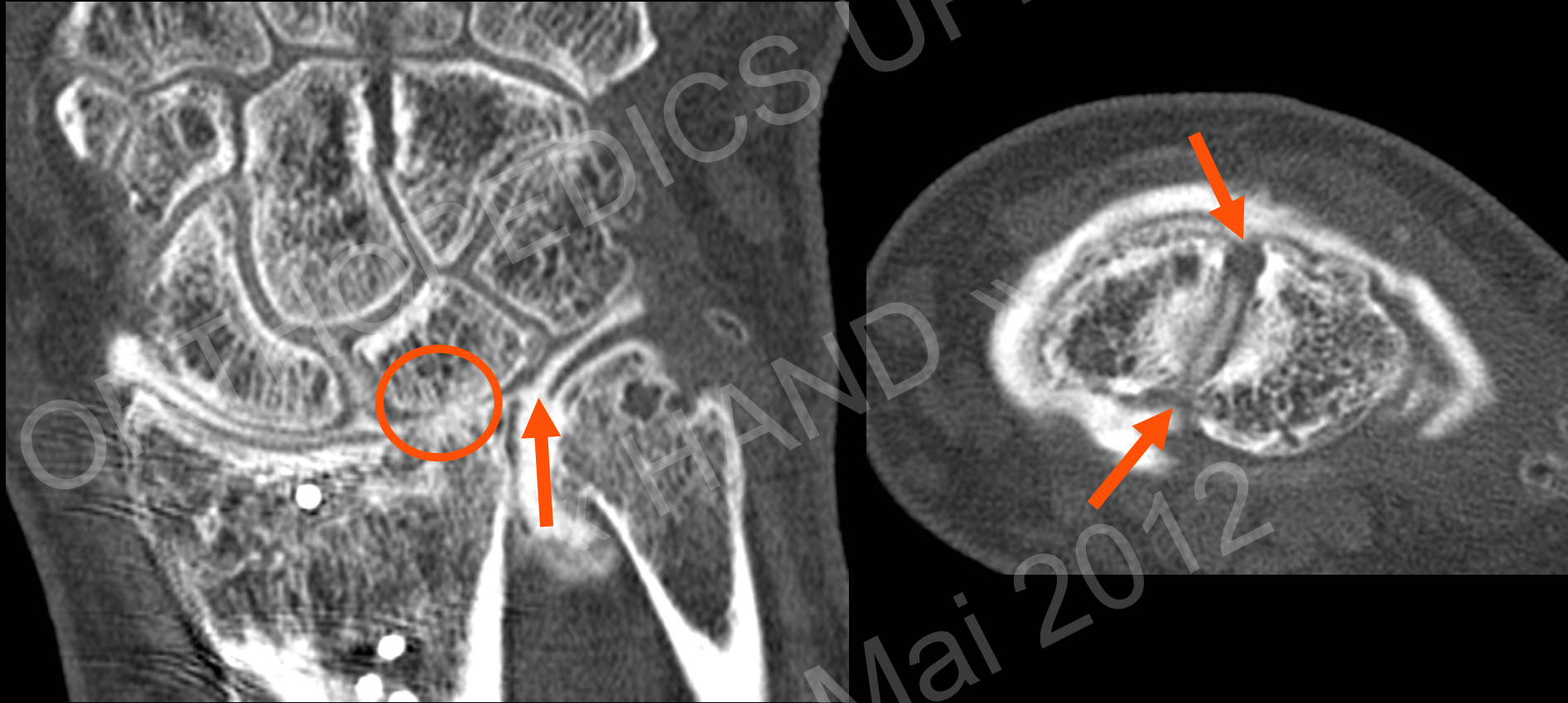TFC? Ligaments? Cartilage?



TFC? Ligaments? Cartilage?



TFC? Ligaments? Cartilage?

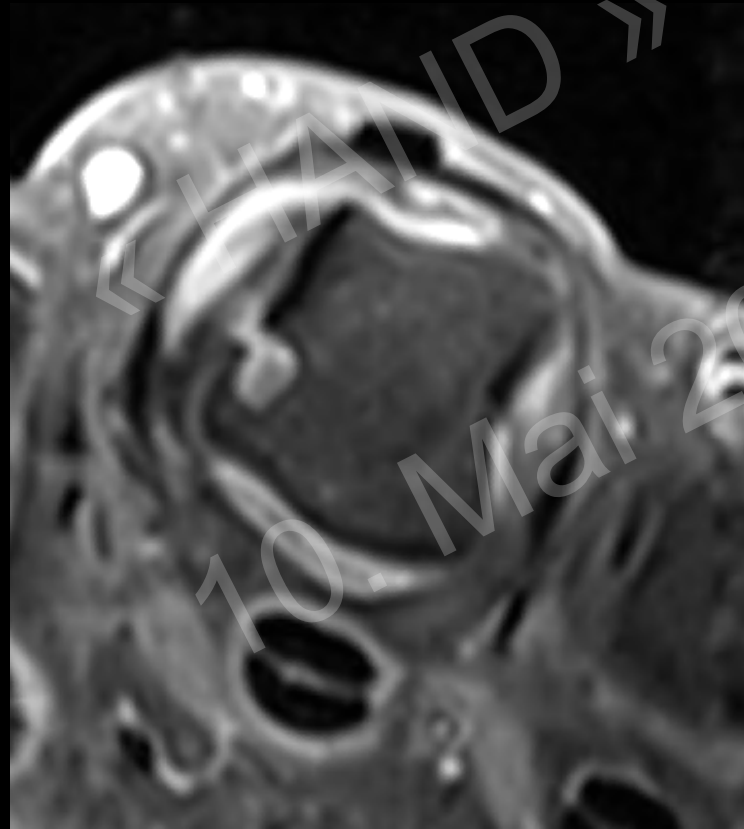


Cartilage damage lunate fossa, TFC tear, SL Ligament intact

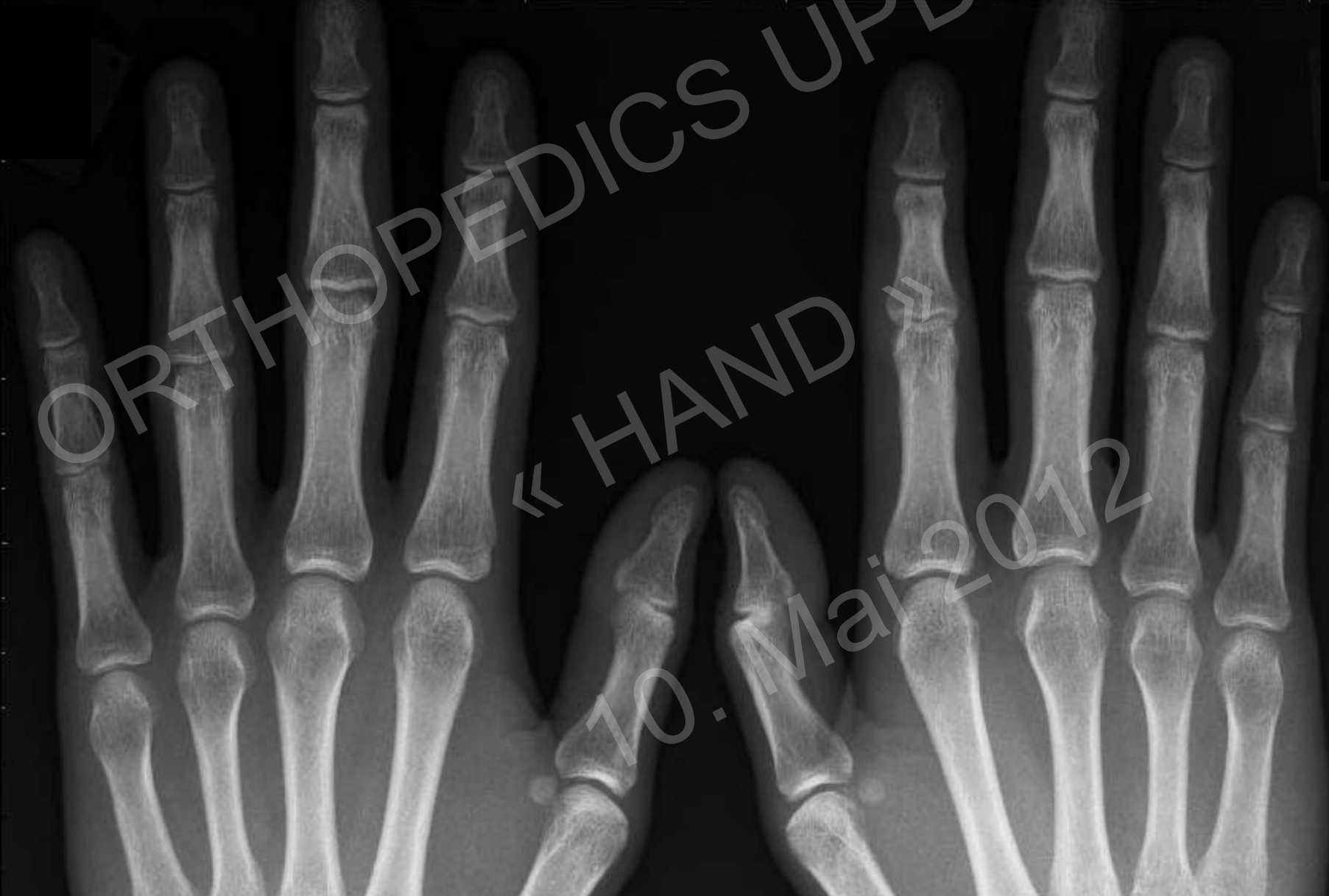Inflammatory Disease

Imaging modality of choice:

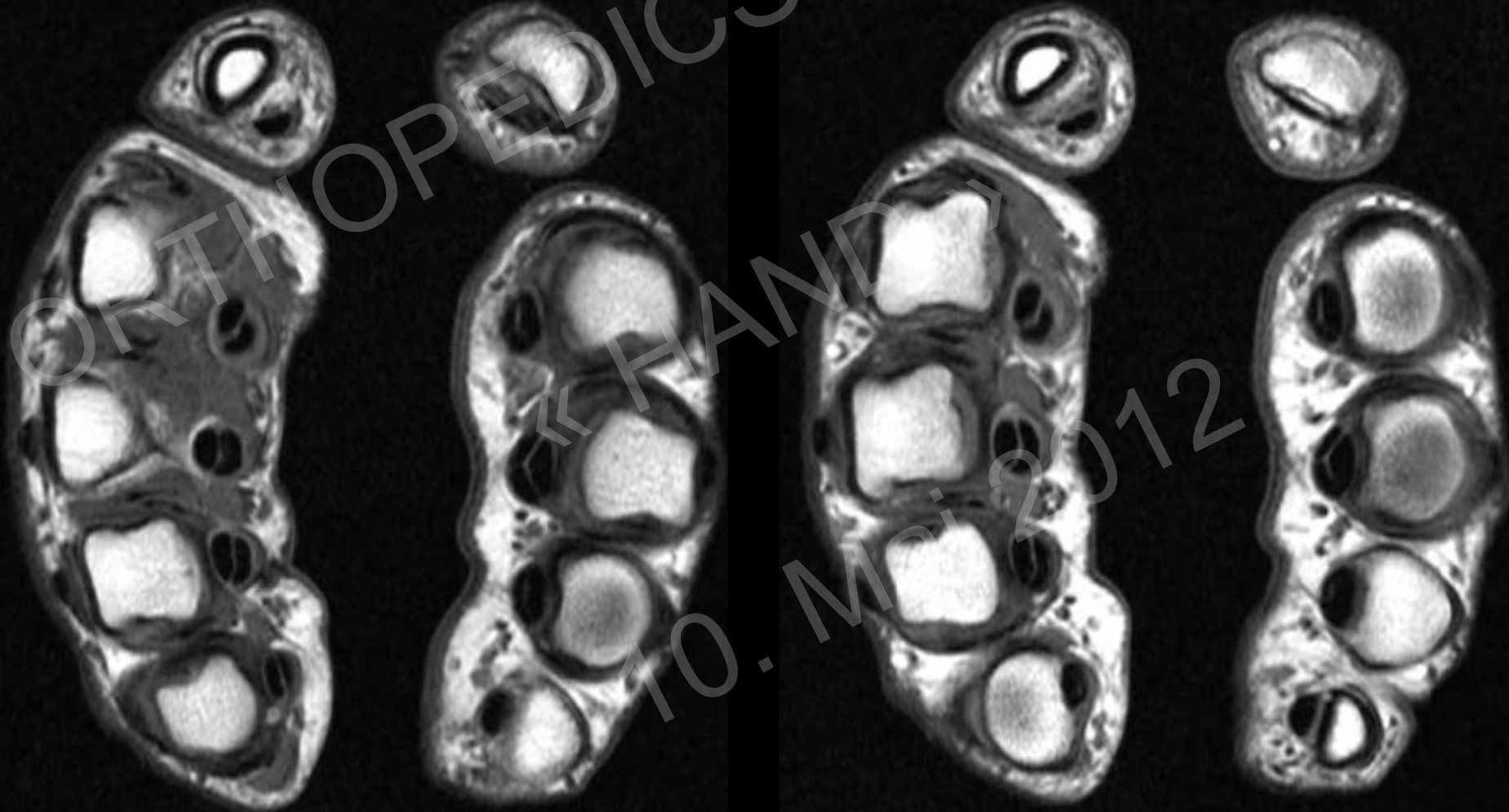1. Rx
2. US
3. MR with iv Gadolinium



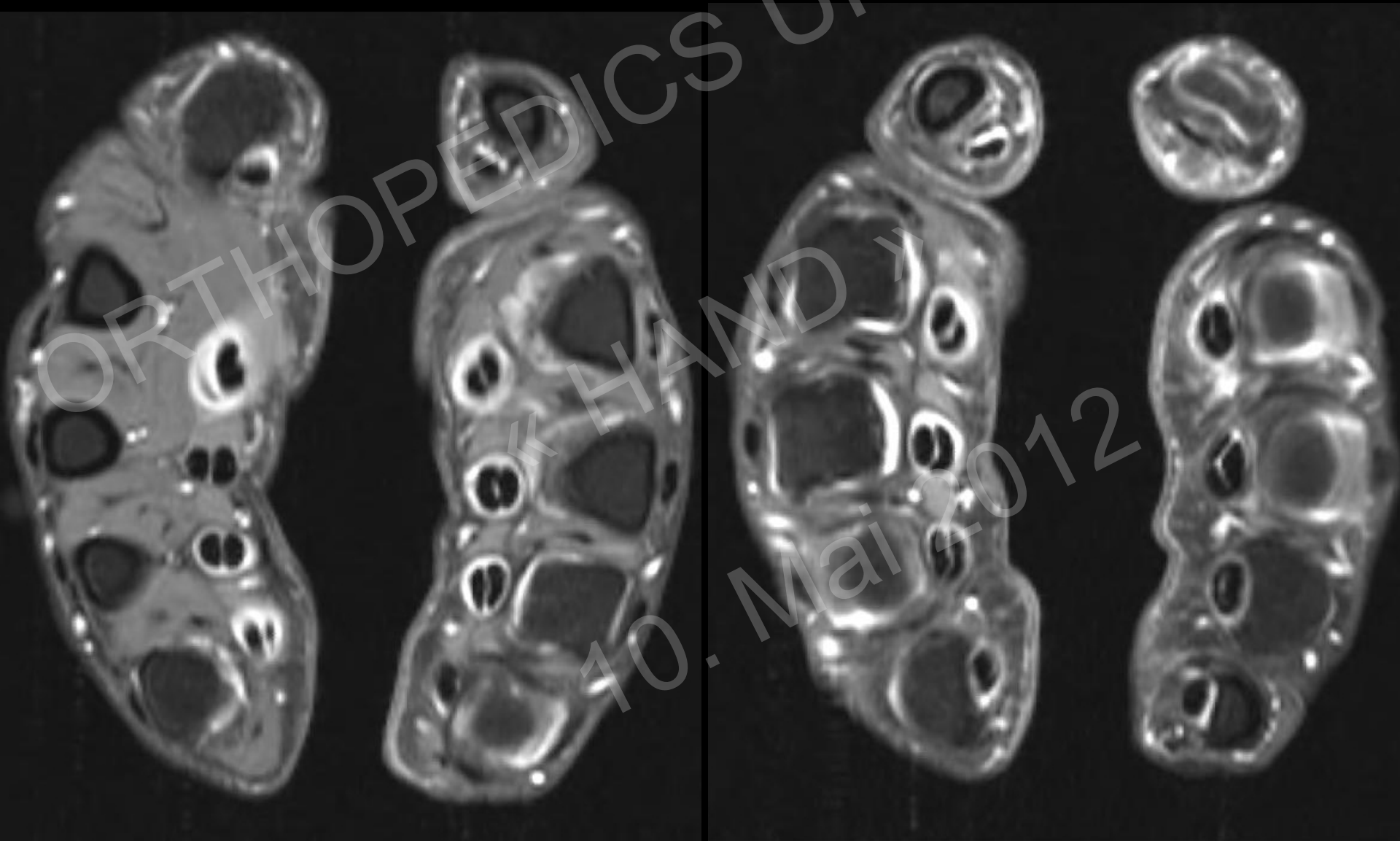RA: Synovitis? Erosion



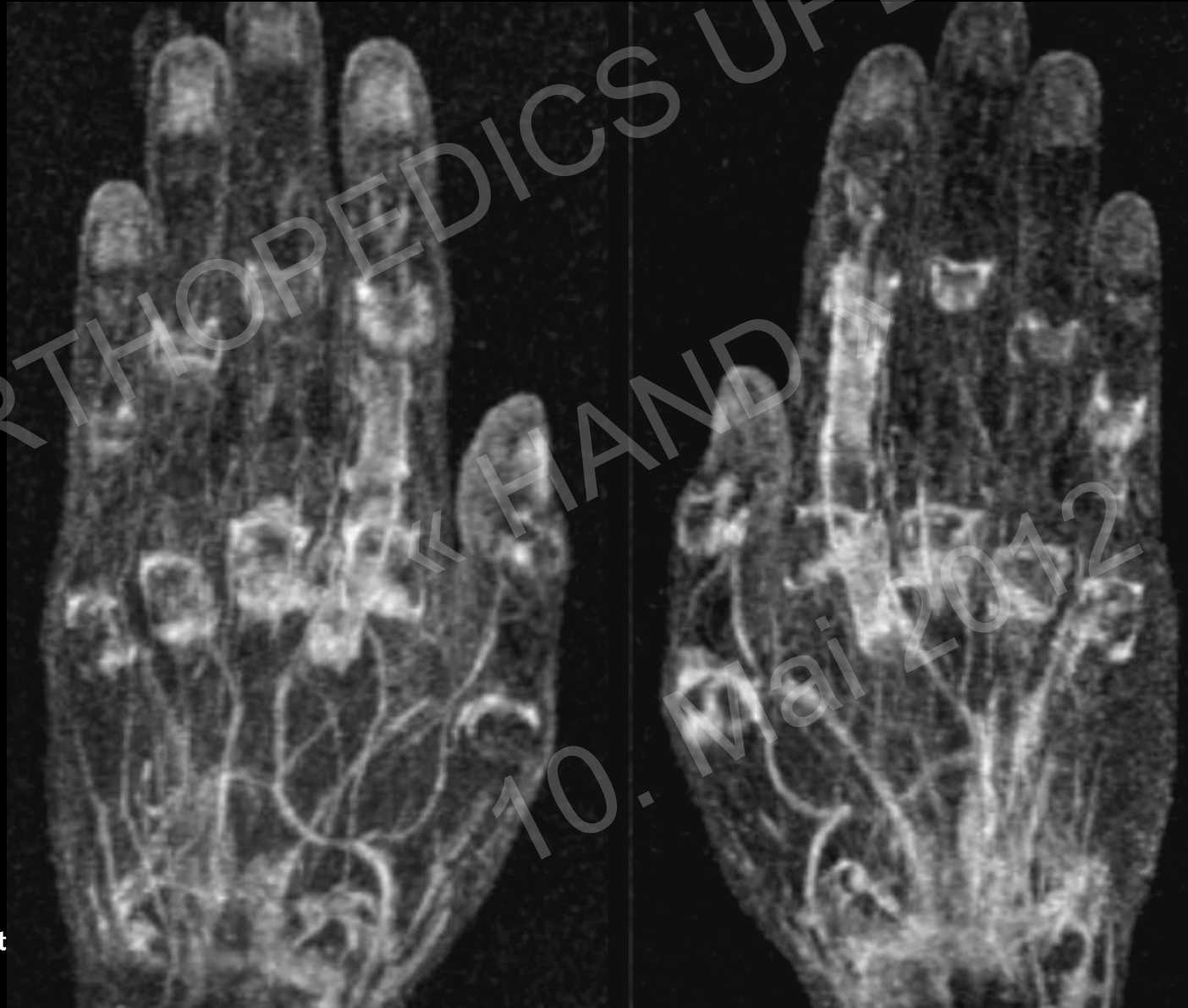T1w: Morphology



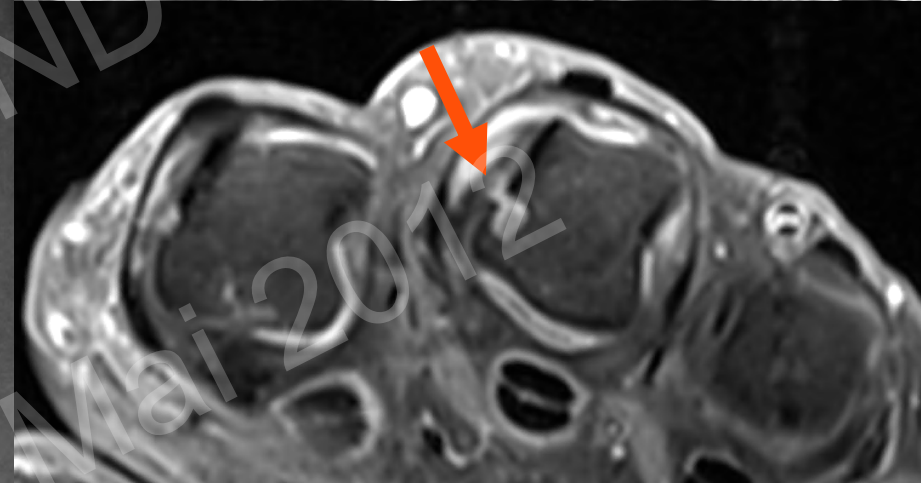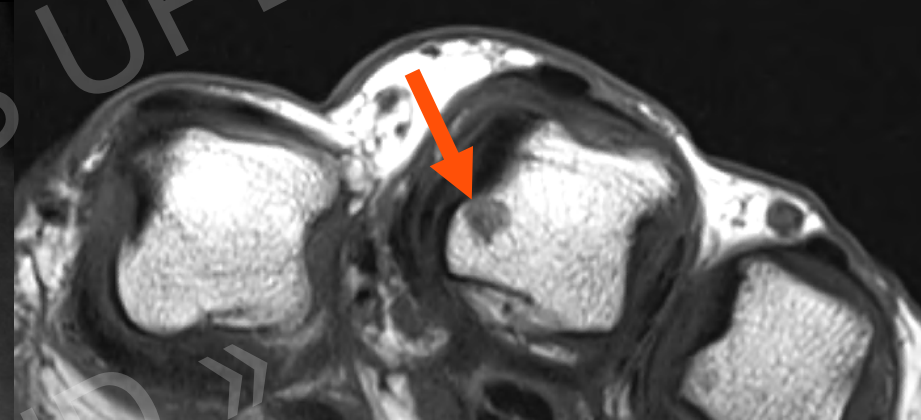
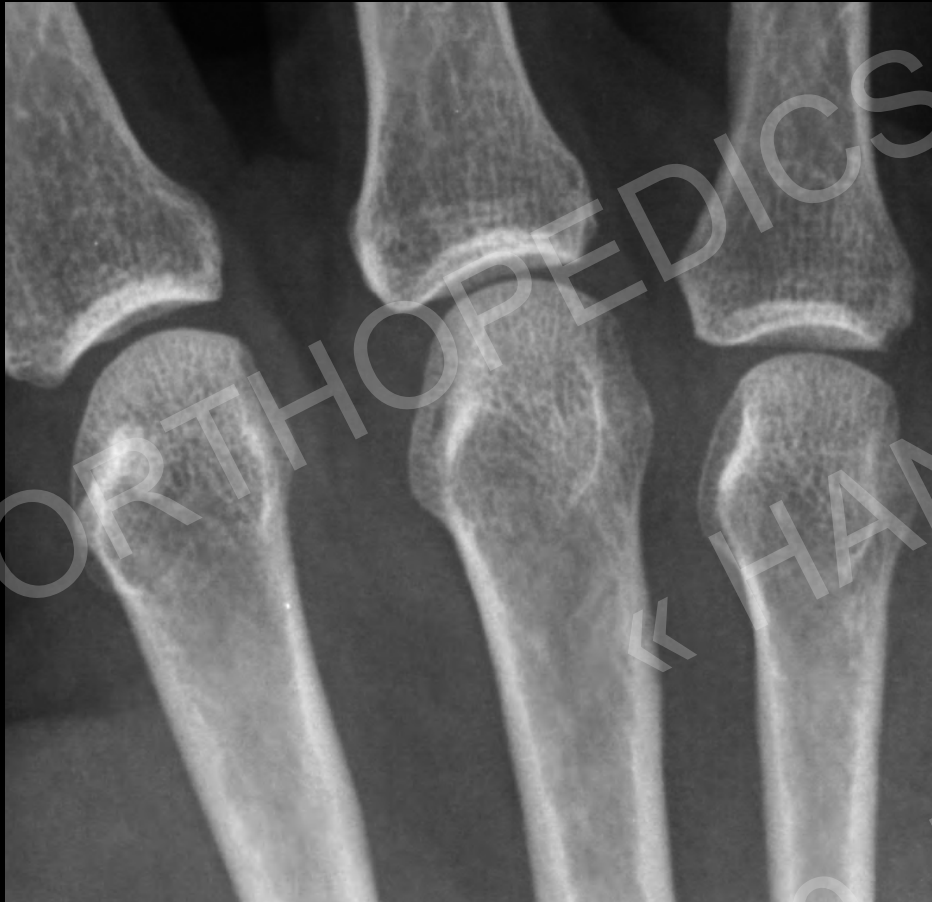Contrast: Synovitis



Synovitis Maps



Erosions: Early Detection



Strict criteria for the definition of bone erosions:

lesion observed in two imaging planes involving a cortical break in at least one

Imaging of the Hand & Wrist

	Rx	US	MR	MR Arthro	MR iv Gad	CT	CT Arthro
TFC			**	***	**		**
Ligaments		**	**	***	**		**
Cartilage			**	***	**		***
Bone Fracture	***		**			***	
Bone AVN	**				***		
Tendon		***	***				
Ganglion		***	***				
Inflammatory	**	***			***		
Tumors		*			***		
Nerves		***			**		

ORTHOPEDICS UPDATE

« HAND »

10. Mai 2012

