



**SSSR**

Swiss Society of  
Musculoskeletal Radiology

# Postoperative Imaging of the Shoulder

Christoph A. Agten

Radiology

Balgrist University Hospital  
University of Zurich Switzerland



University of  
Zurich <sup>UZH</sup>

**uniklinik**  
EXPERTISE IN MOTION  
**balgrist**

# Overview

Overview

Instability

Rotator cuff repair

Teaching Points

## Instability

- Bankart repair
- Glenoid bone loss
- Coracoid transfer

## Rotator cuff repair

- Postoperative Imaging
- Acromioplasty and AC-joint resection
- Deltoideus

---

SSSR

# Instability

Anterior shoulder instability

1. Nov. 2014

# Instability

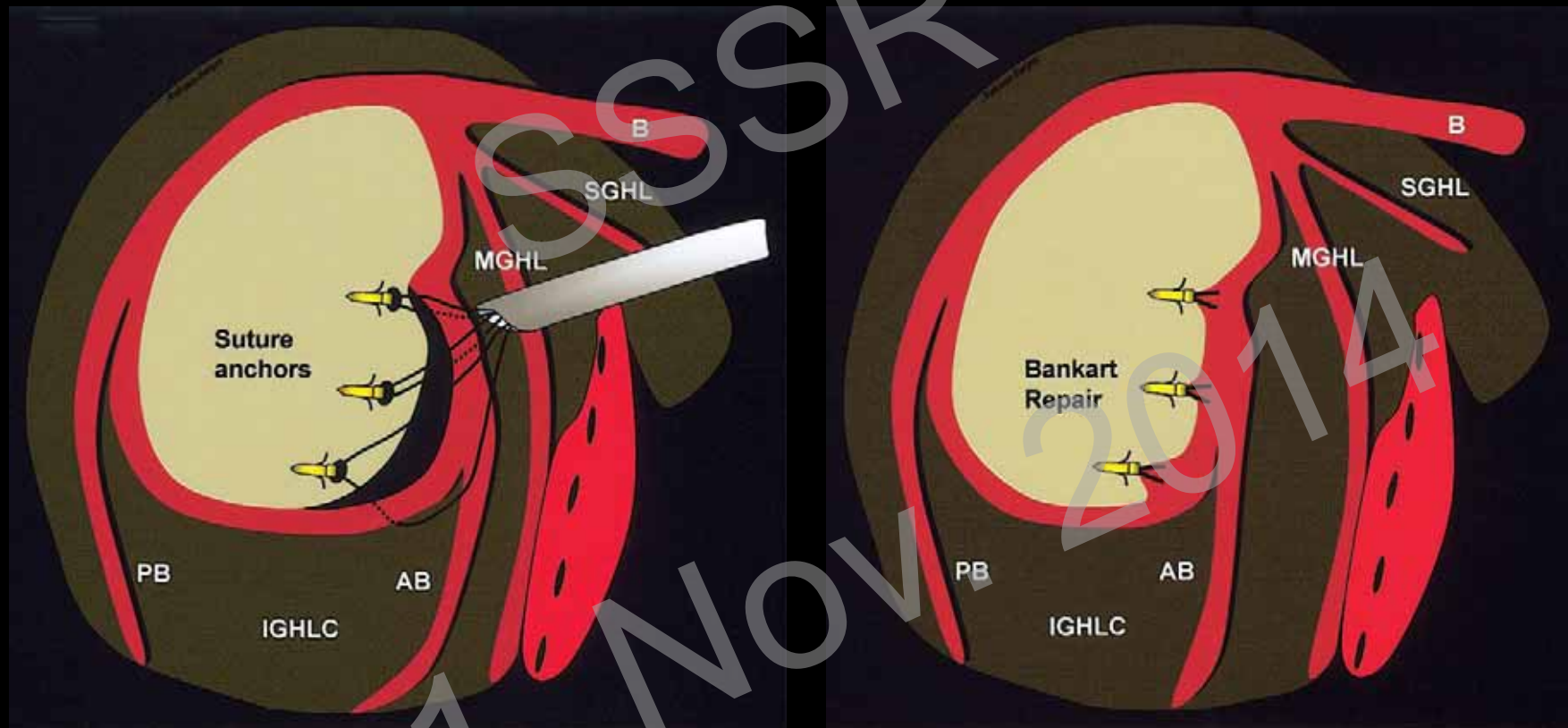
Overview

Instability

Rotator cuff repair

Teaching Points

## Bankart-Repair



Mohana-Borges AVR et al. RadioGraphics 2004

# Instability

Overview

Instability

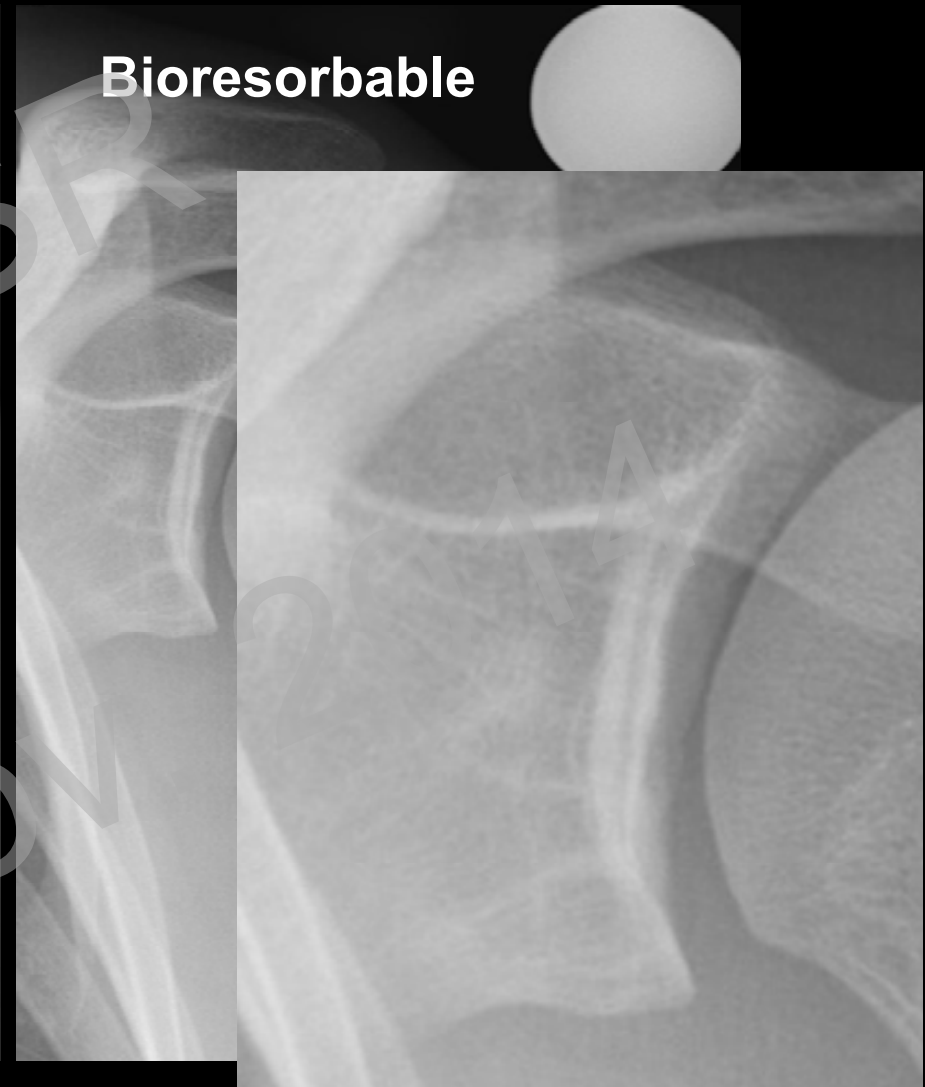
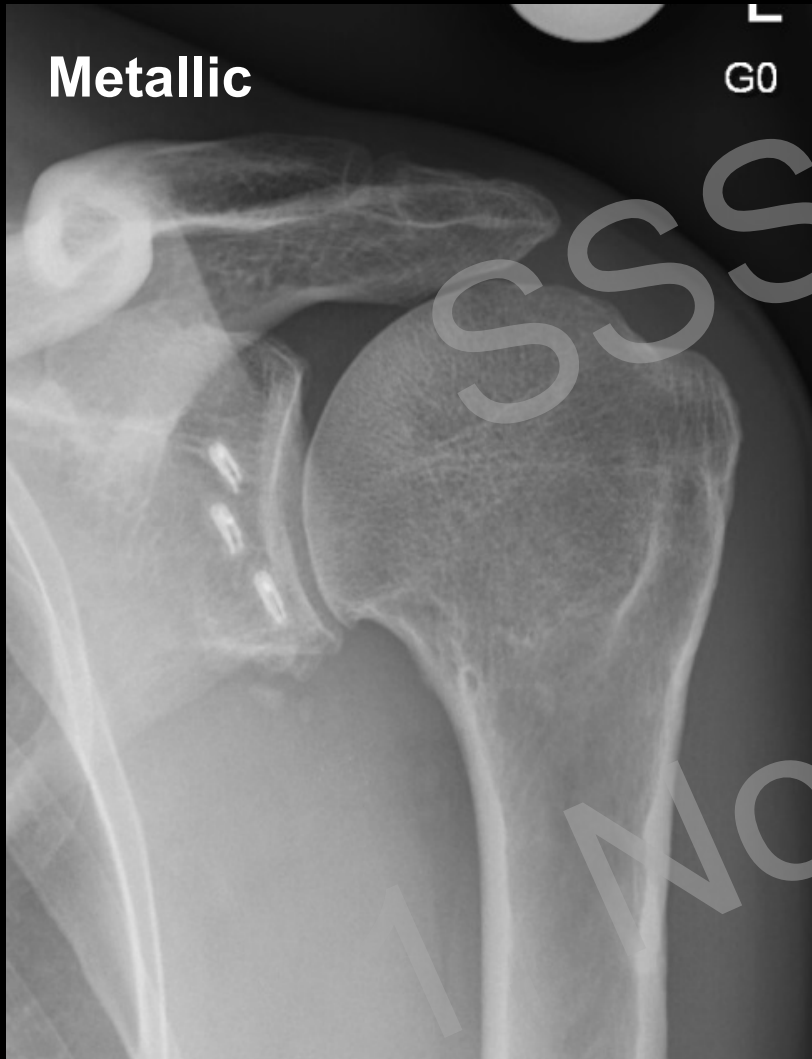Rotator cuff repair

Teaching Points

**Metallic**

G0

**Bioresorbable**



# Instability

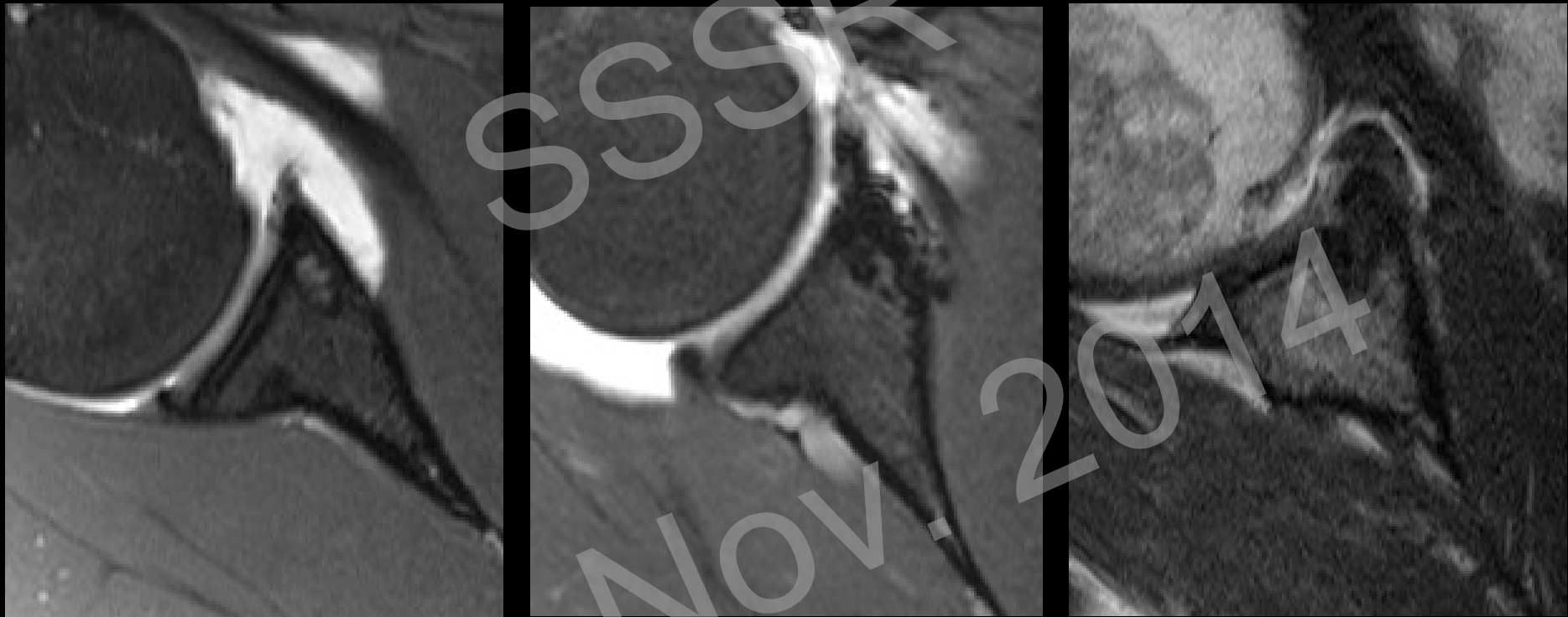
Overview

Instability

Rotator cuff repair

Teaching Points

## Postoperative appearance Arthro-MRI



# Instability

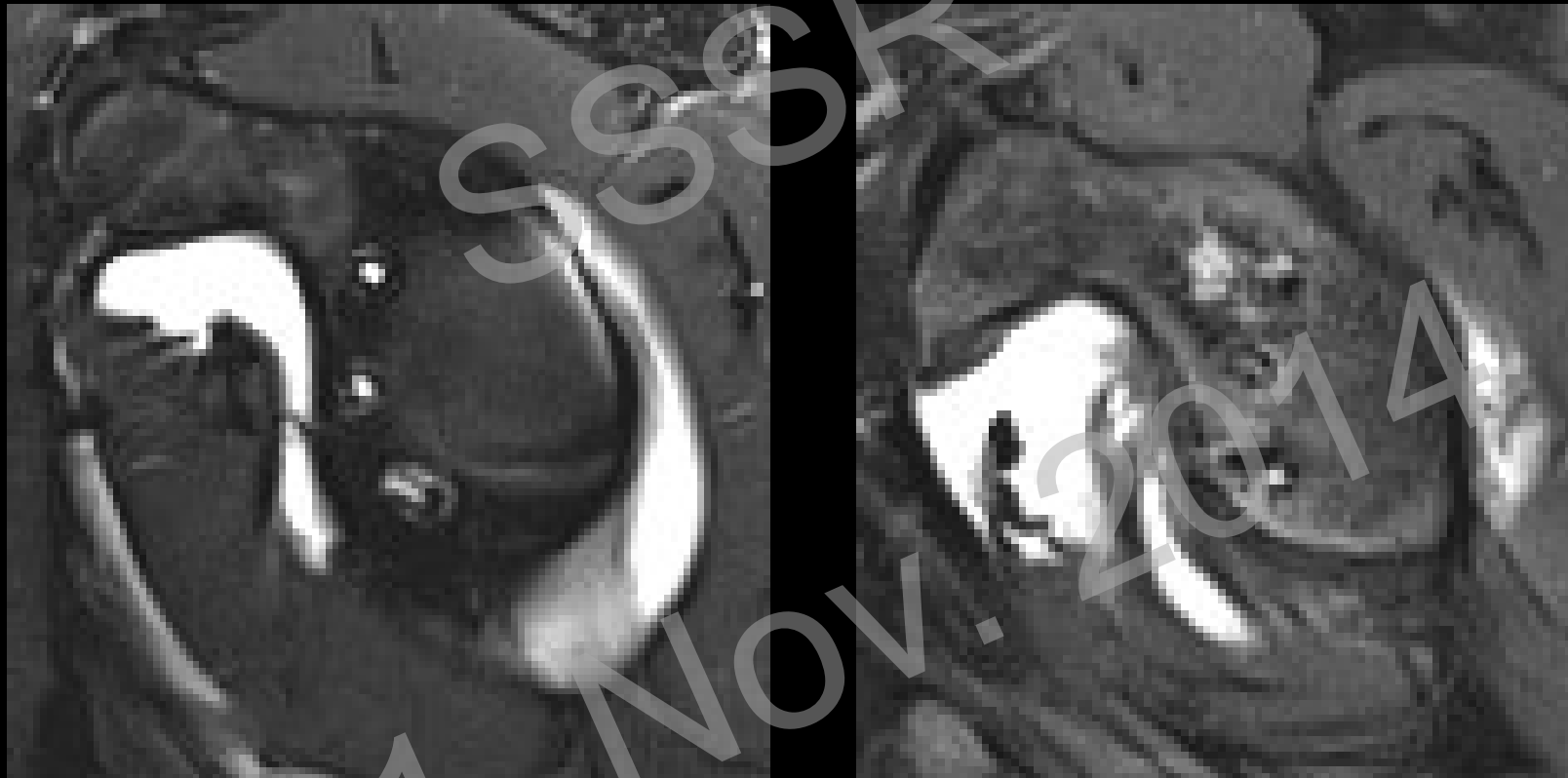Overview

Instability

Rotator cuff repair

Teaching Points

## Postoperative appearance Arthro-MRI



# Instability

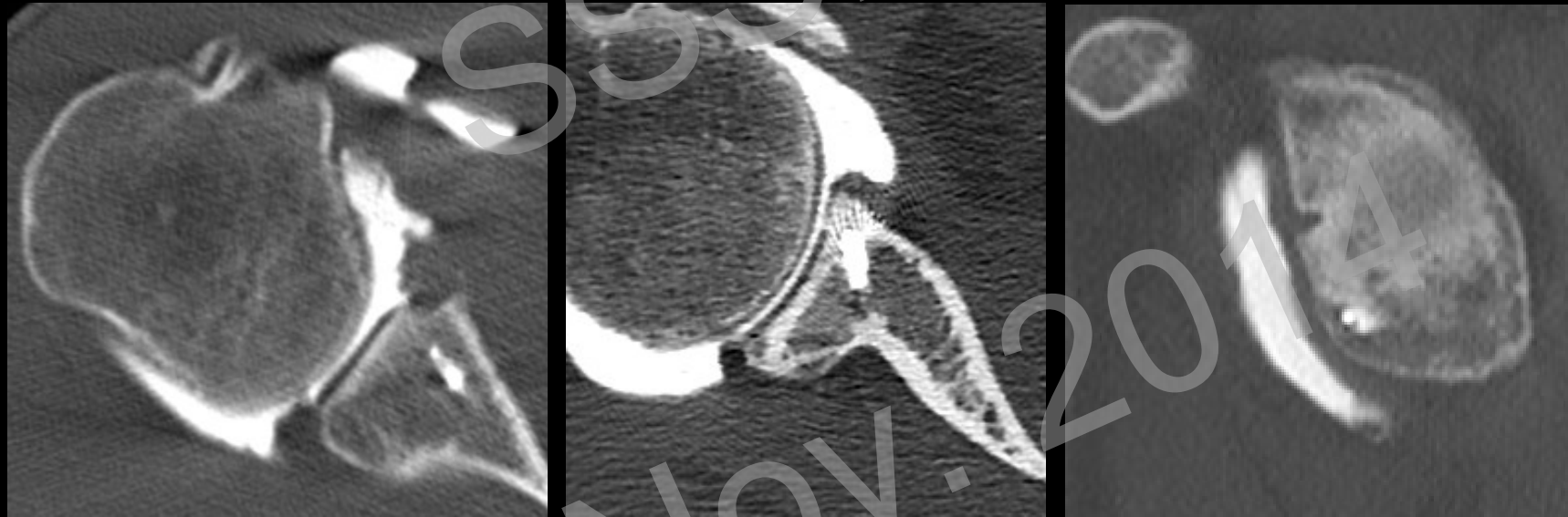
Overview

Instability

Rotator cuff repair

Teaching Points

## Postoperative appearance Arthro-CT





# Instability

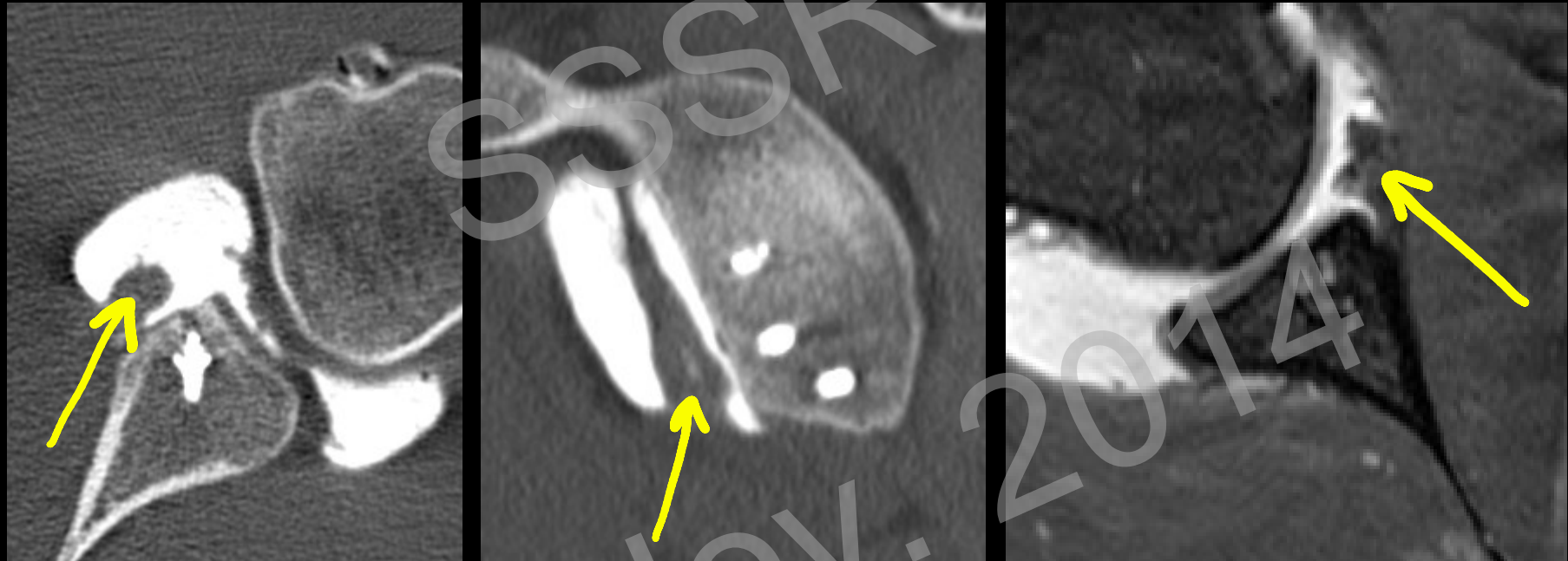
Overview

Instability

Rotator cuff repair

Teaching Points

## Labrum re-tears after Bankart-Repair



# Instability

Overview

Instability

Rotator cuff repair

Teaching Points

## Anchor complications:

- Breakage
- Migration
- Loosening
- Dislocation

## + Bioabsorbable anchors (resorption within 3-30 months<sup>1</sup>)

- Fragmentation
- Synovitis
- Granuloma/Osteolysis

1) Nho SJ et al., Arthroscopy 2009

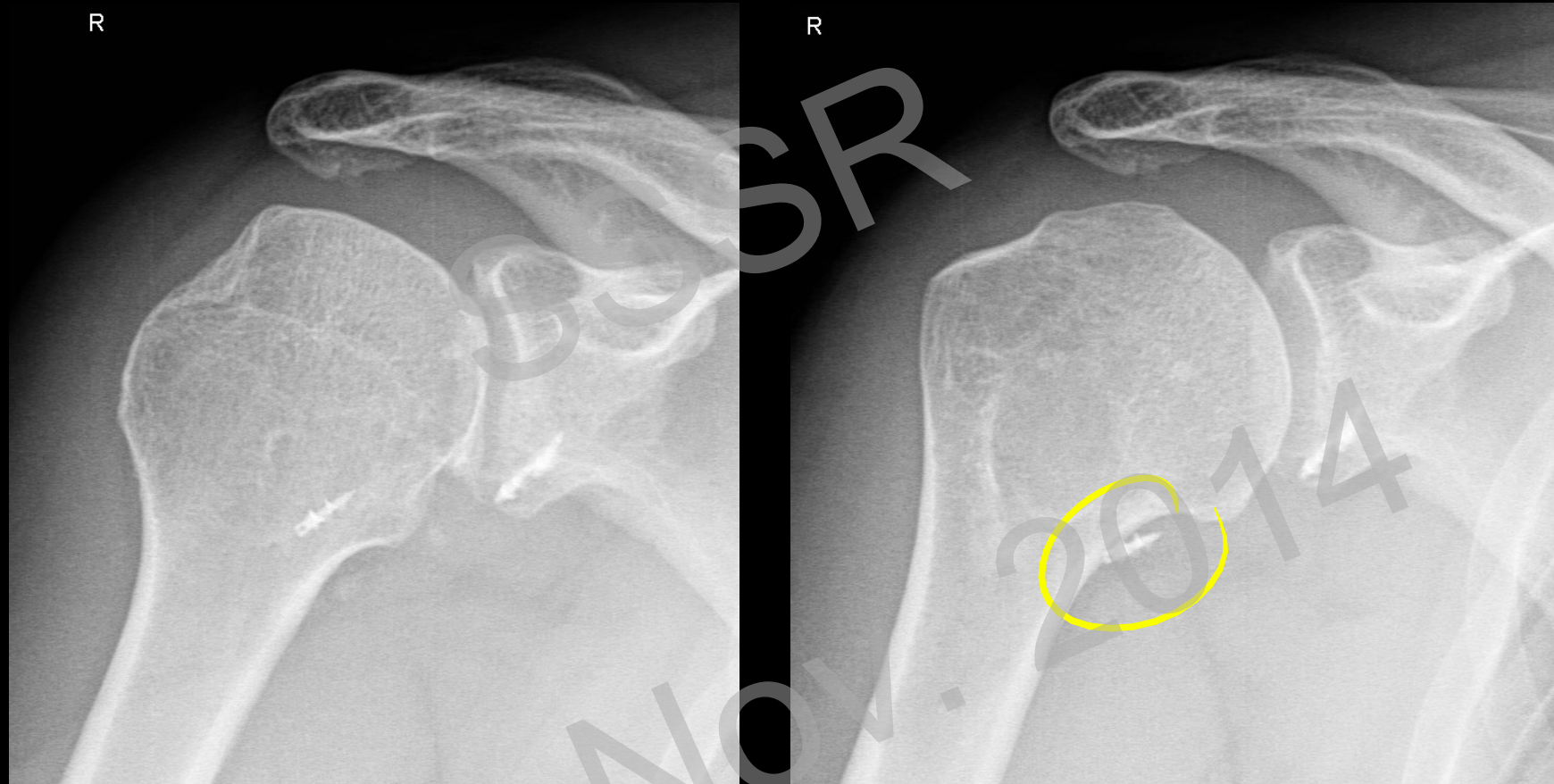
# Instability

Overview

Instability

Rotator cuff repair

Teaching Points



Anchor dislocation

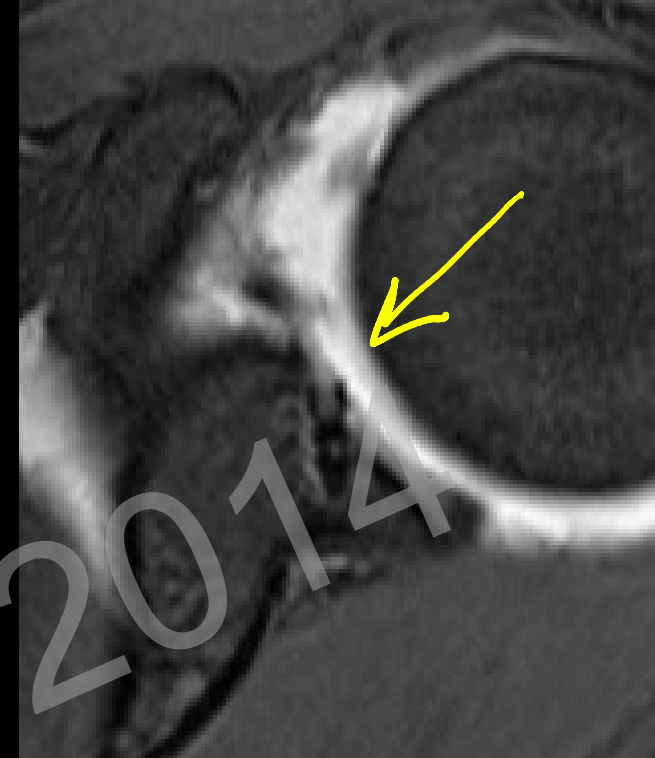
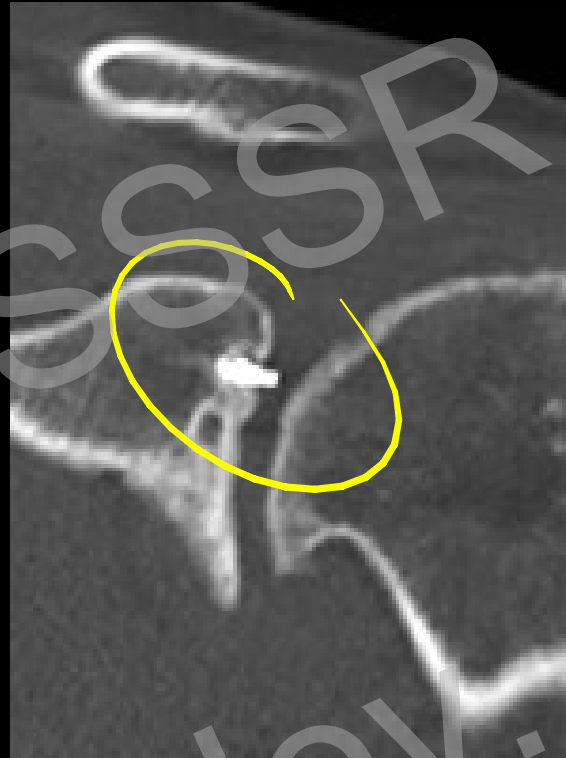
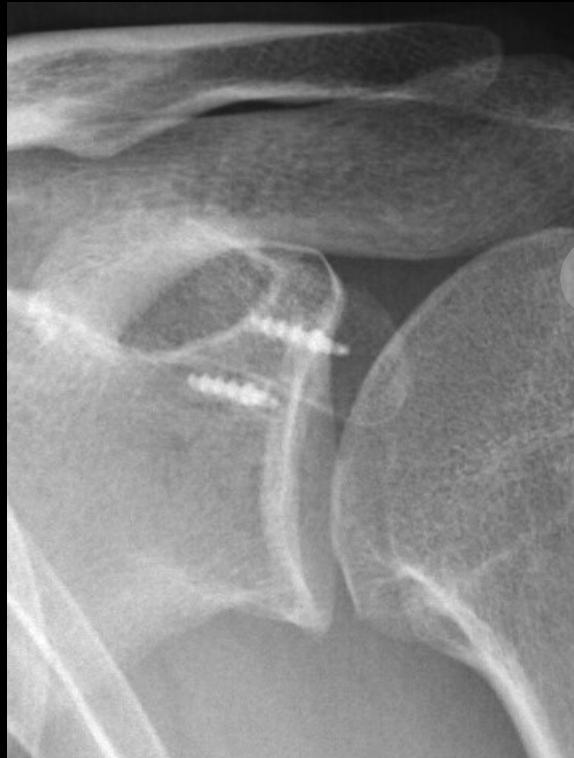# Instability

Overview

Instability

Rotator cuff repair

Teaching Points



1. Nov. 2014  
Cartilage break-through

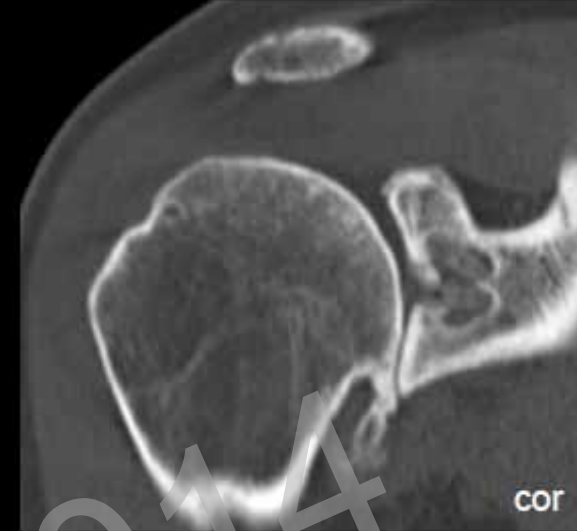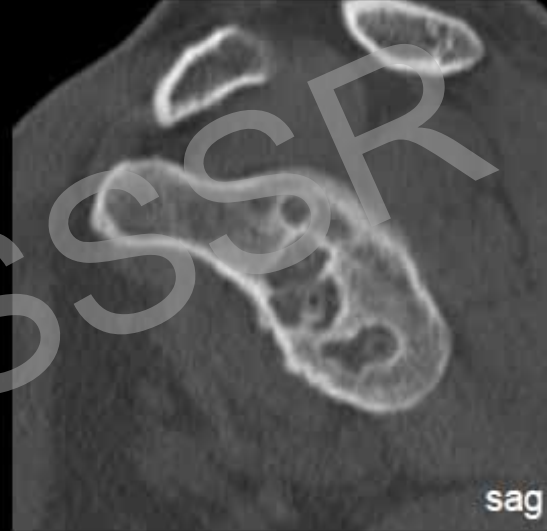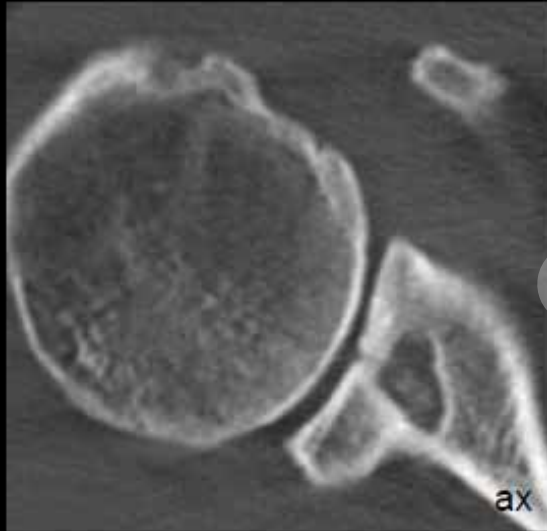
# Instability

Overview

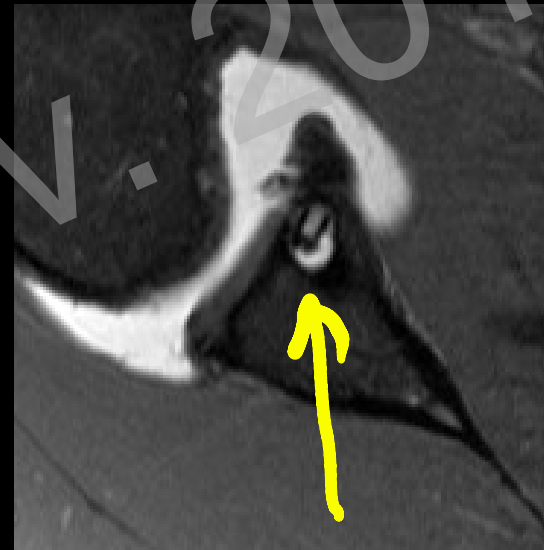Instability

Rotator cuff repair

Teaching Points



Osteolysis around  
bioabsorbable anchors



# Instability

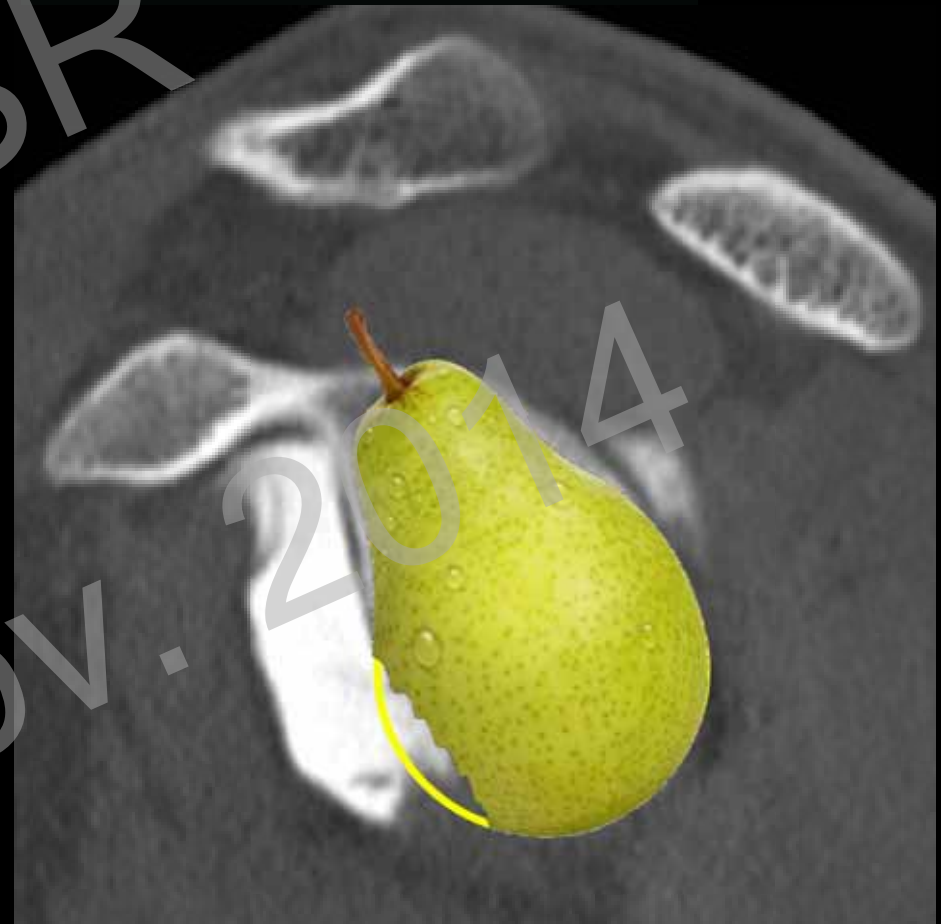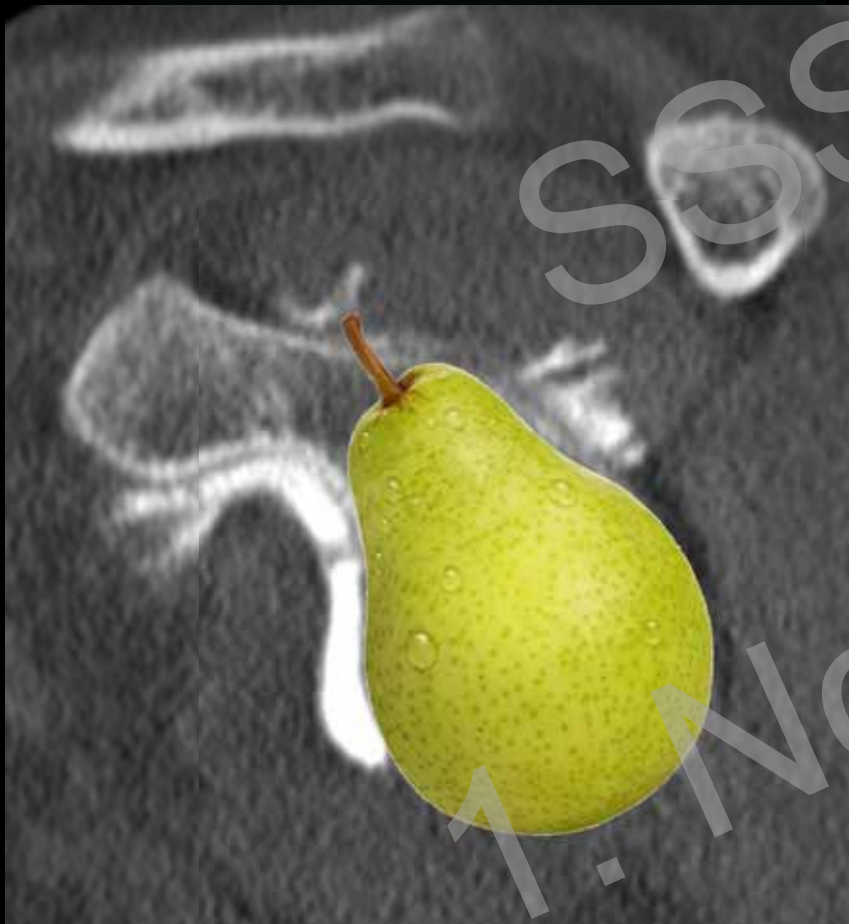Overview

Instability

Rotator cuff repair

Teaching Points

- Anterior glenoid bone loss



# Instability

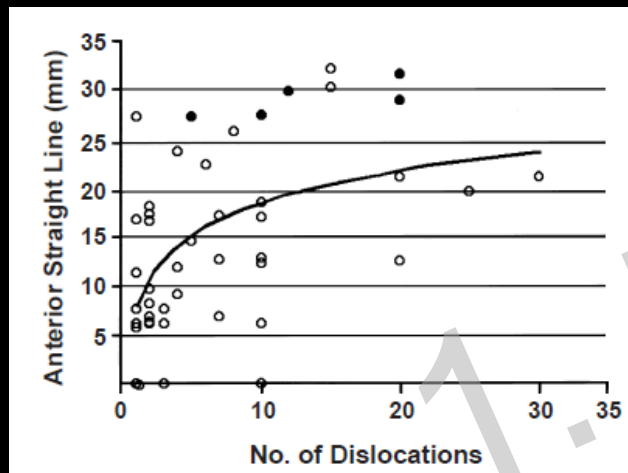
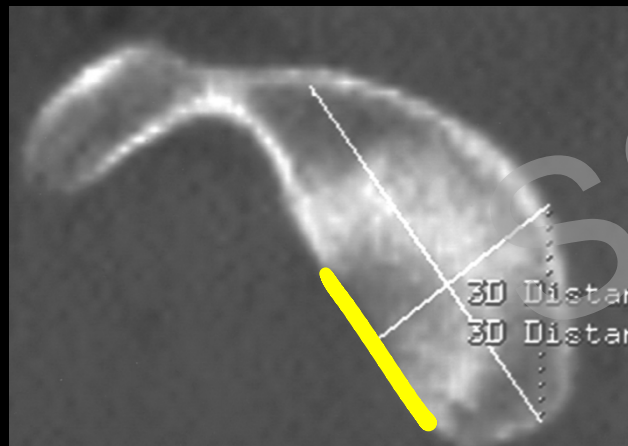
Overview

Instability

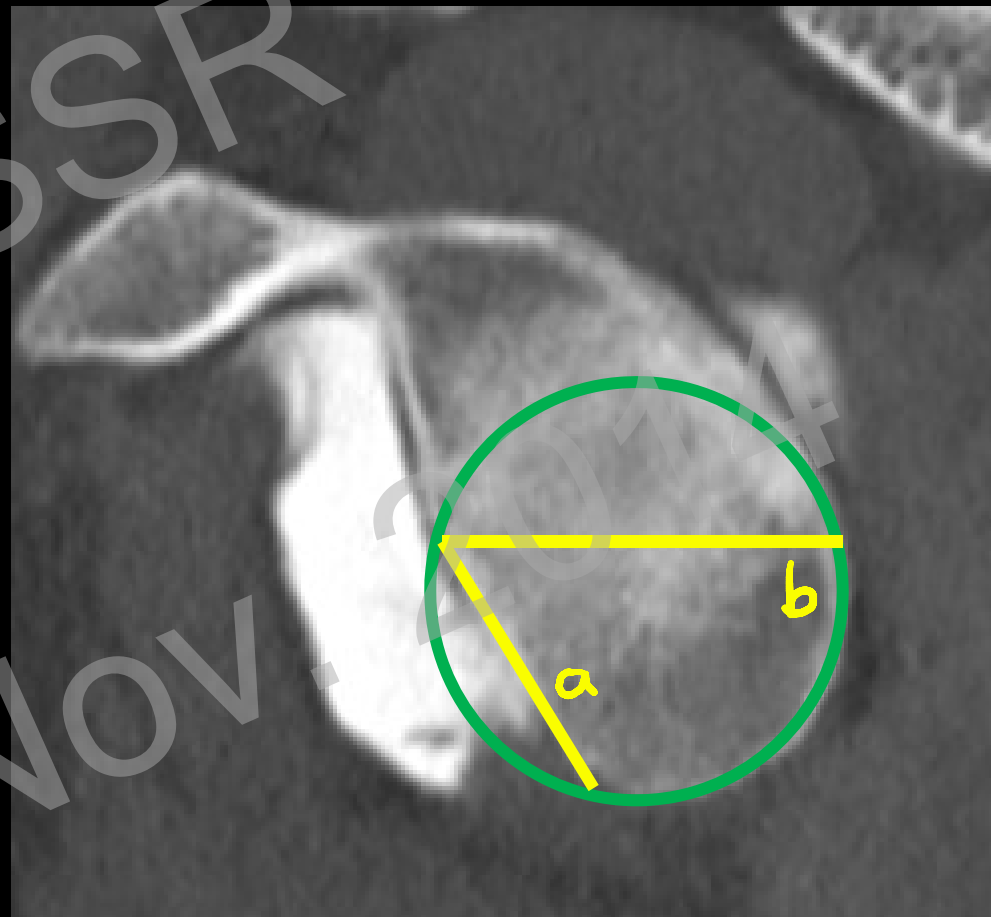
Rotator cuff repair

Teaching Points

- How to measure?



Griffith JF et al. AJR 2003



Gerber C et al. CORR 2002

# Instability

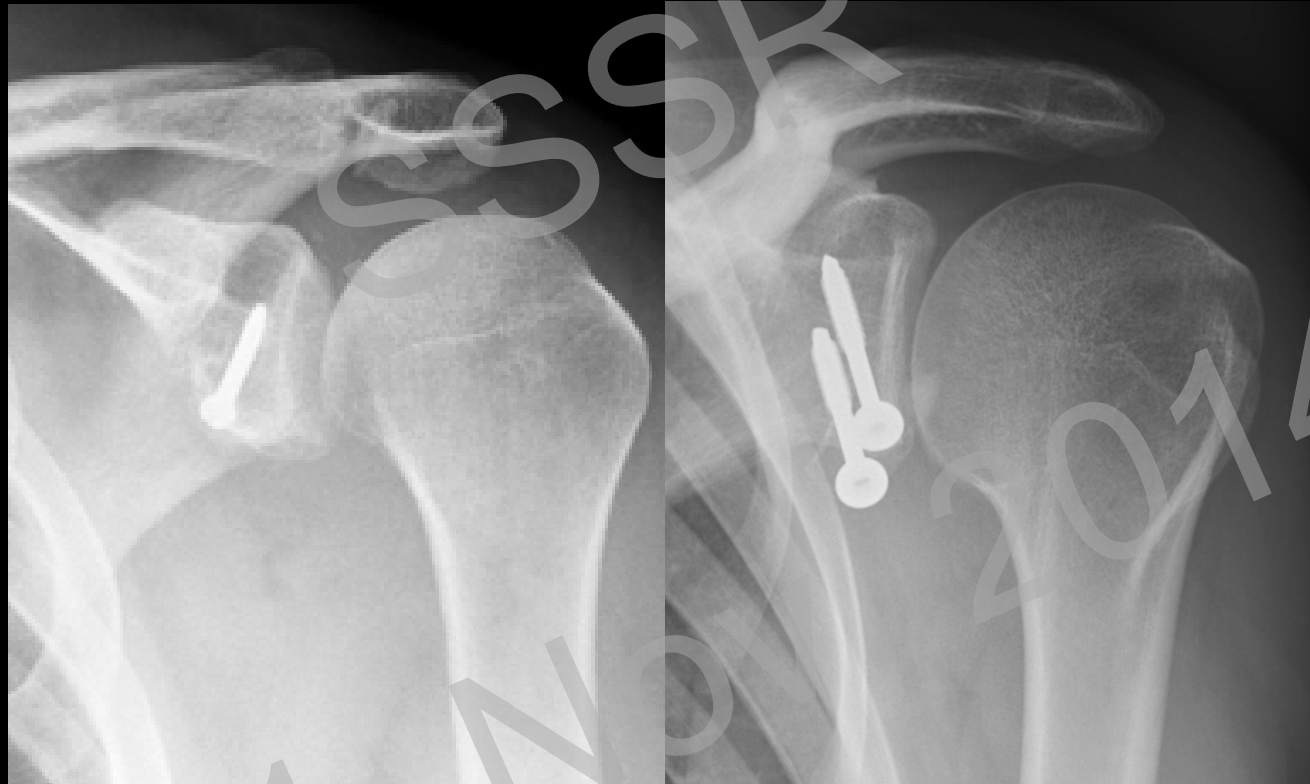
Overview

Instability

Rotator cuff repair

Teaching Points

## Coracoid-Transfer



Bristow

Latarjet



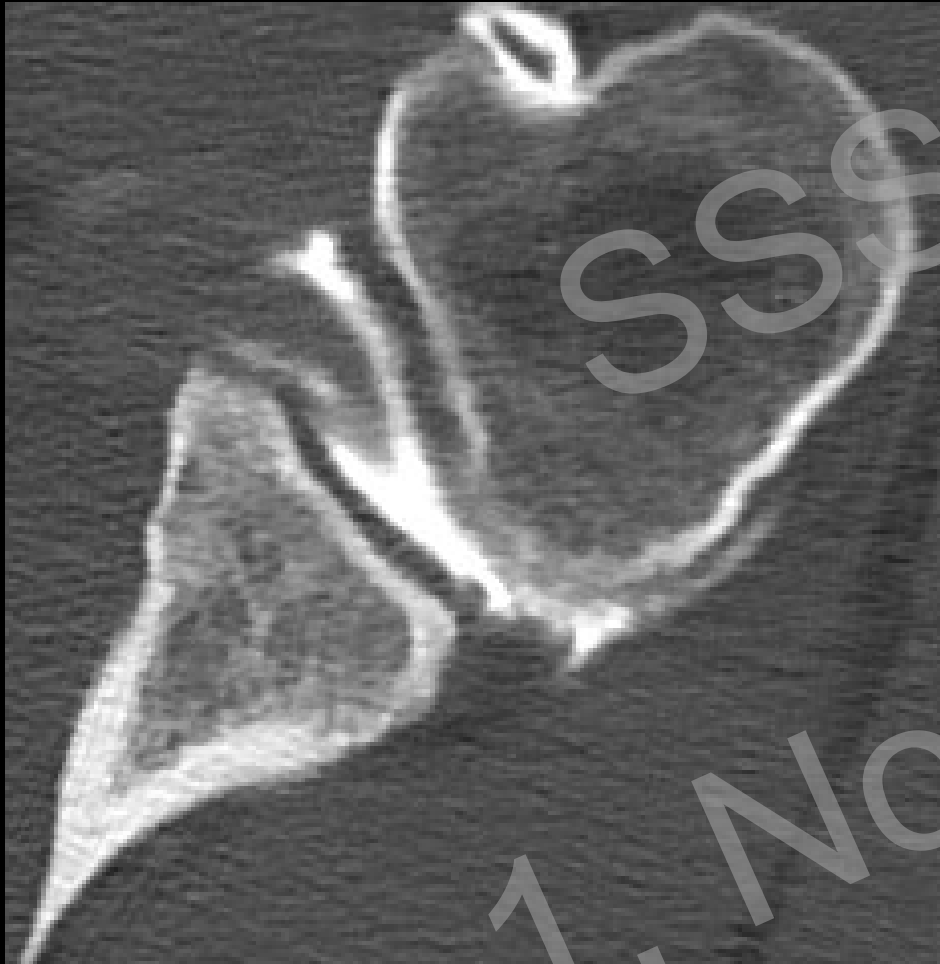# Instability

Overview

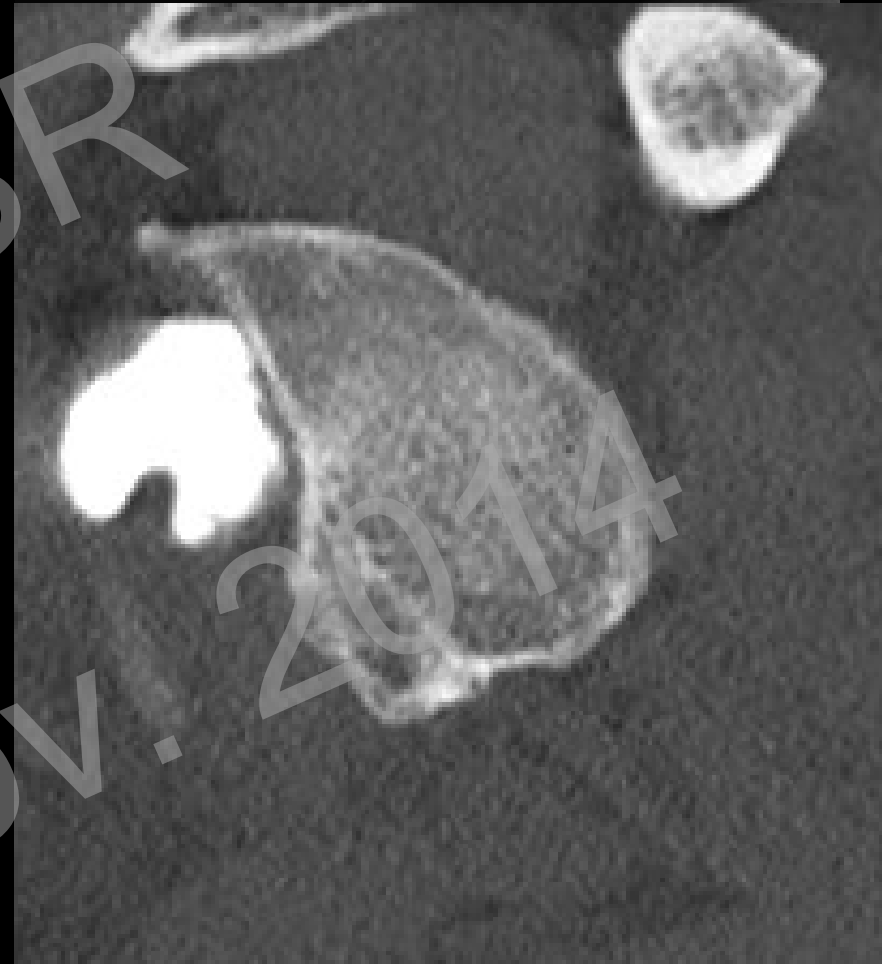
Instability

Rotator cuff repair

Teaching Points



Normal



# Instability

Overview

Instability

Rotator cuff repair

Teaching Points

## Complications after coracoid transfer

- Dislocation of the transferred coracoid
- Hardware failure
- Malunion
- Non-union
- Bone resorption

SSSR  
1. Nov. 2014

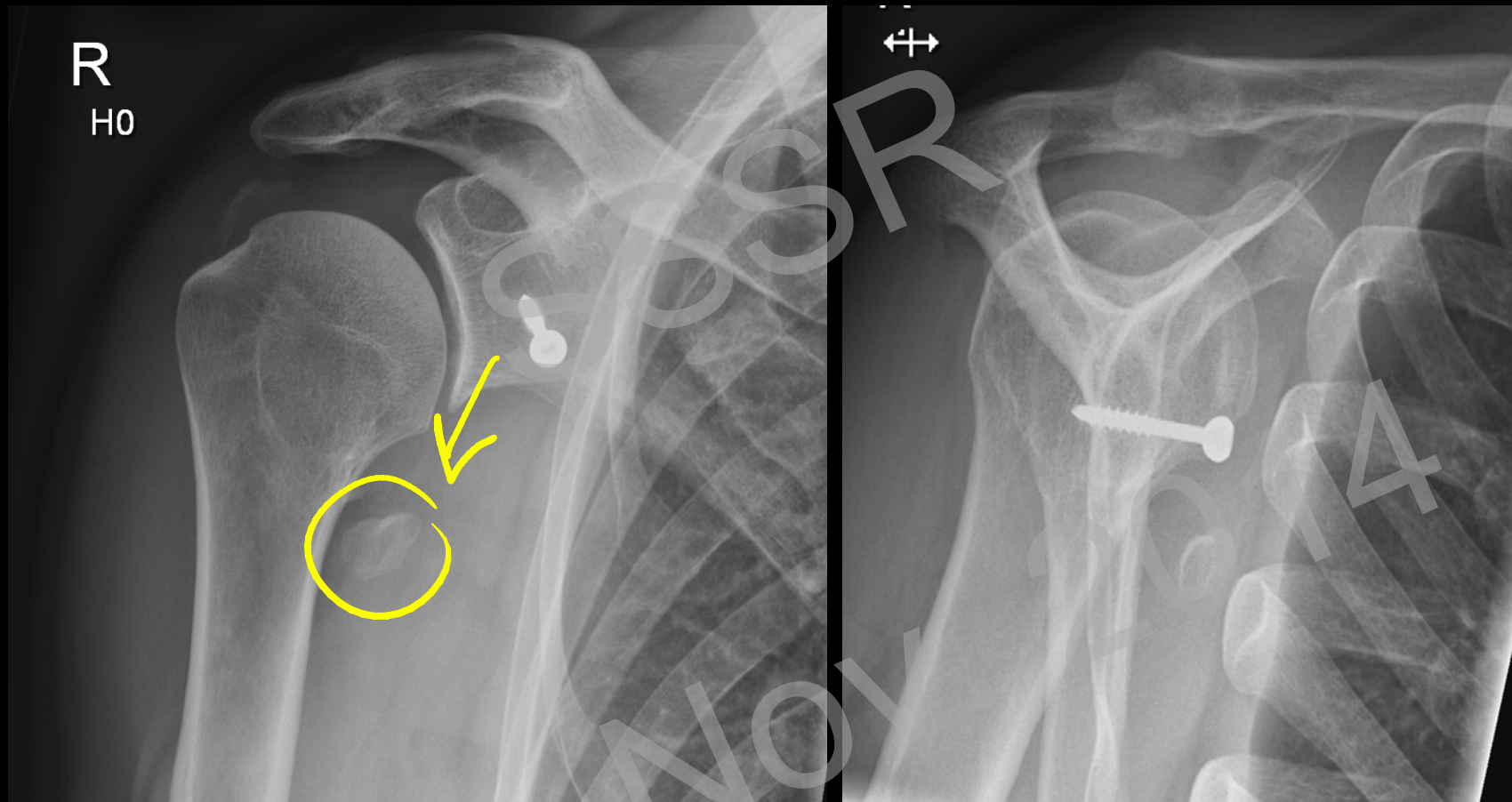# Instability

Overview

Instability

Rotator cuff repair

Teaching Points



# Instability

Overview

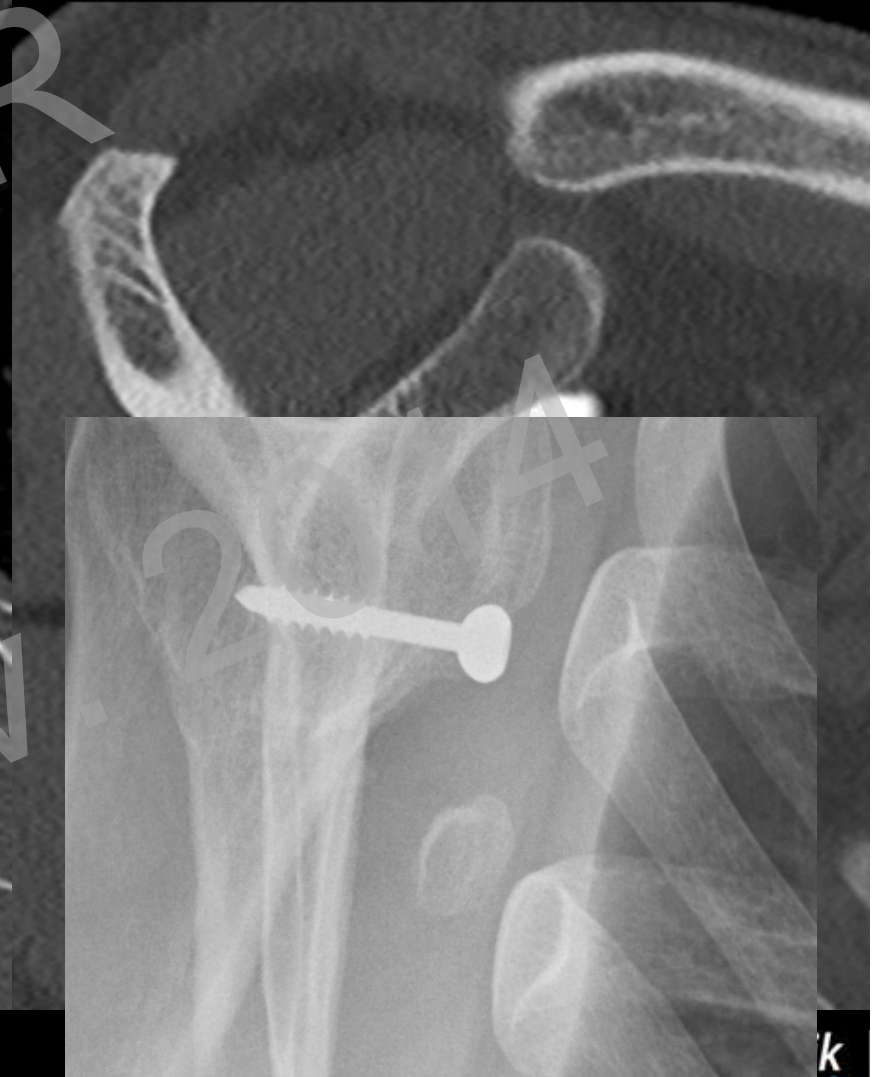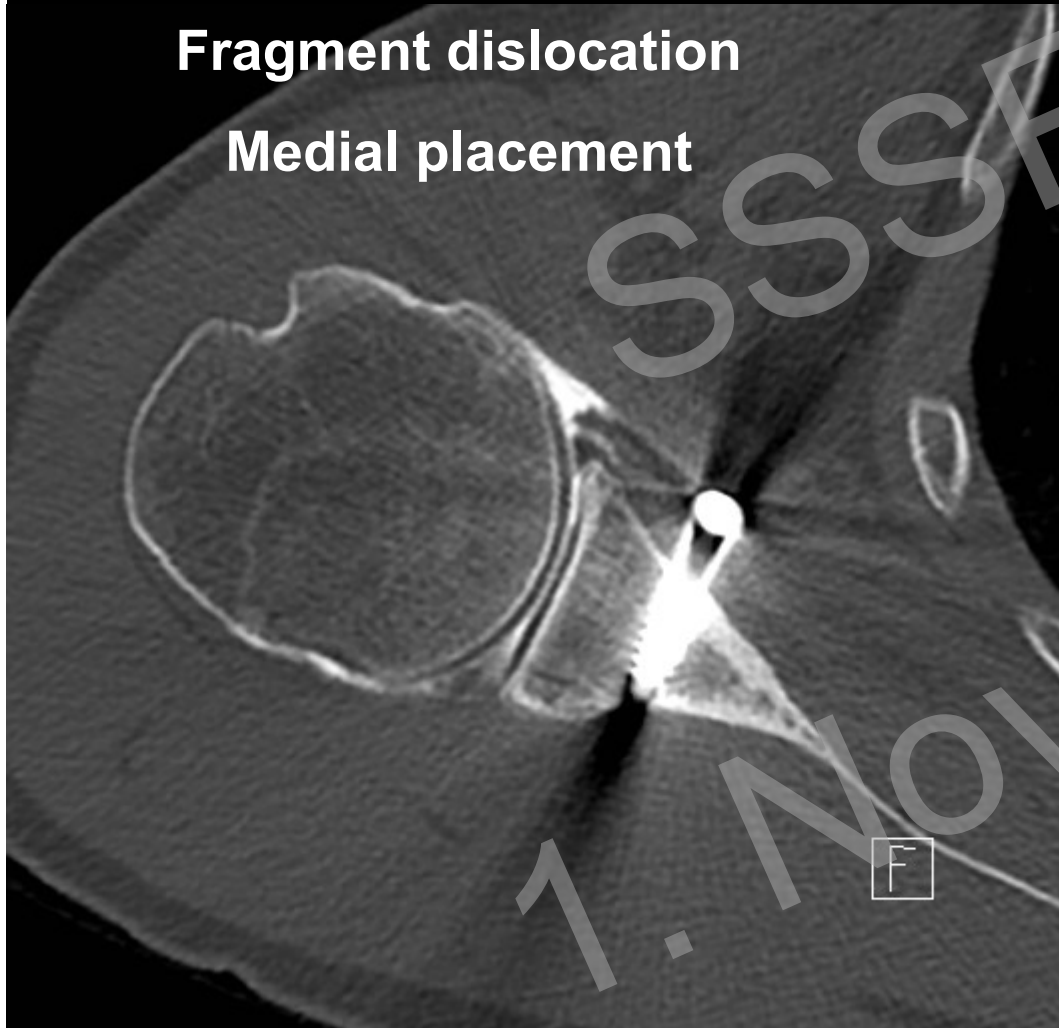
Instability

Rotator cuff repair

Teaching Points

Fragment dislocation

Medial placement



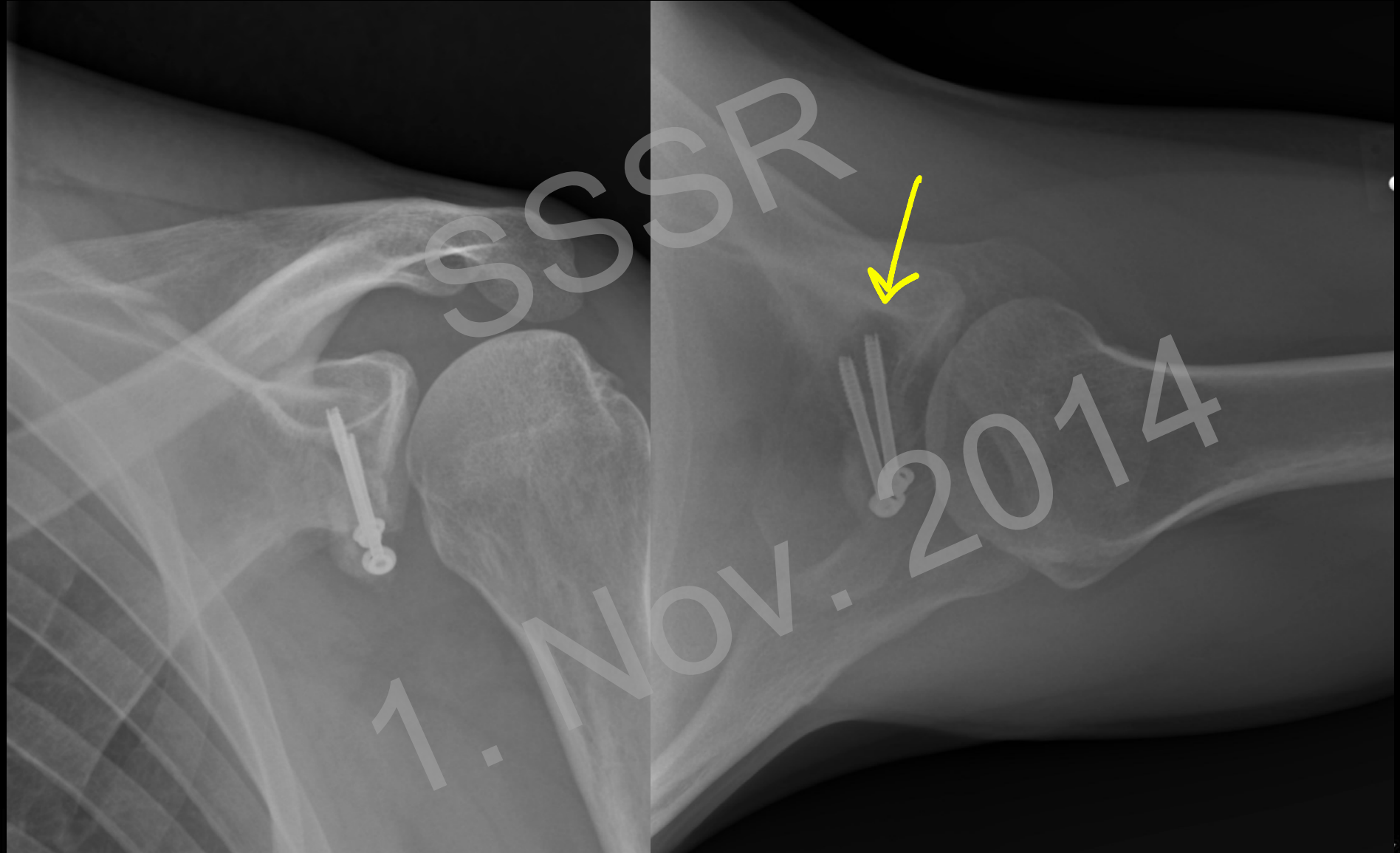# Instability

Overview

Instability

Rotator cuff repair

Teaching Points



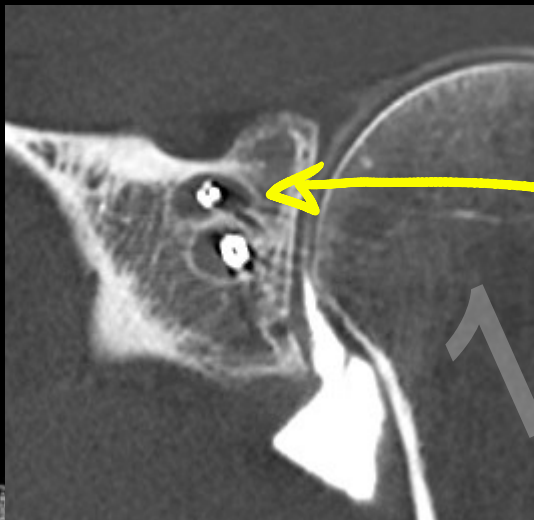
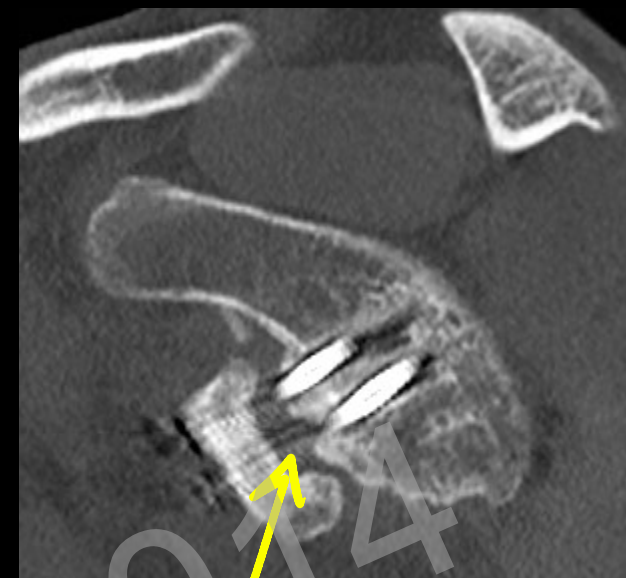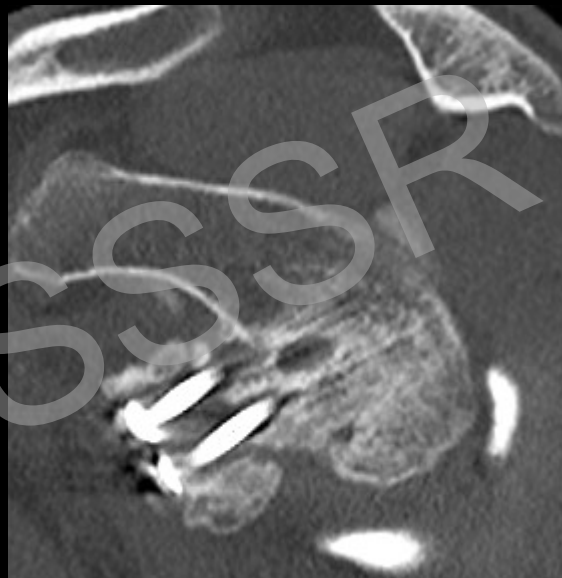
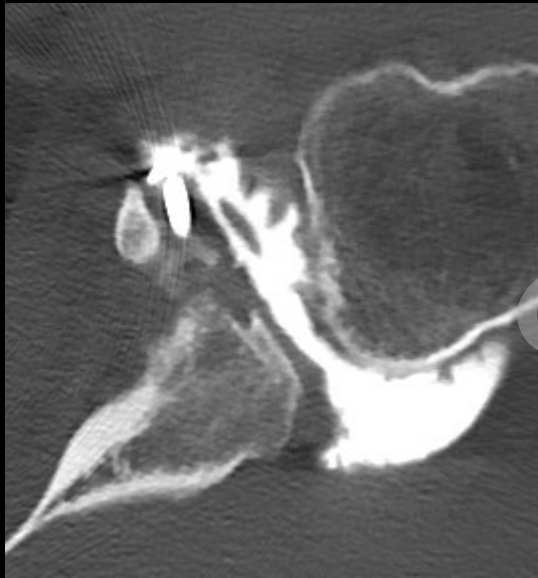# Instability

Overview

Instability

Rotator cuff repair

Teaching Points



Non-union

Screw loosening

Overview

Instability

Rotator cuff repair

Teaching Points

# Rotator Cuff Repair

1. Nov. 2014

# Rotator Cuff Repair

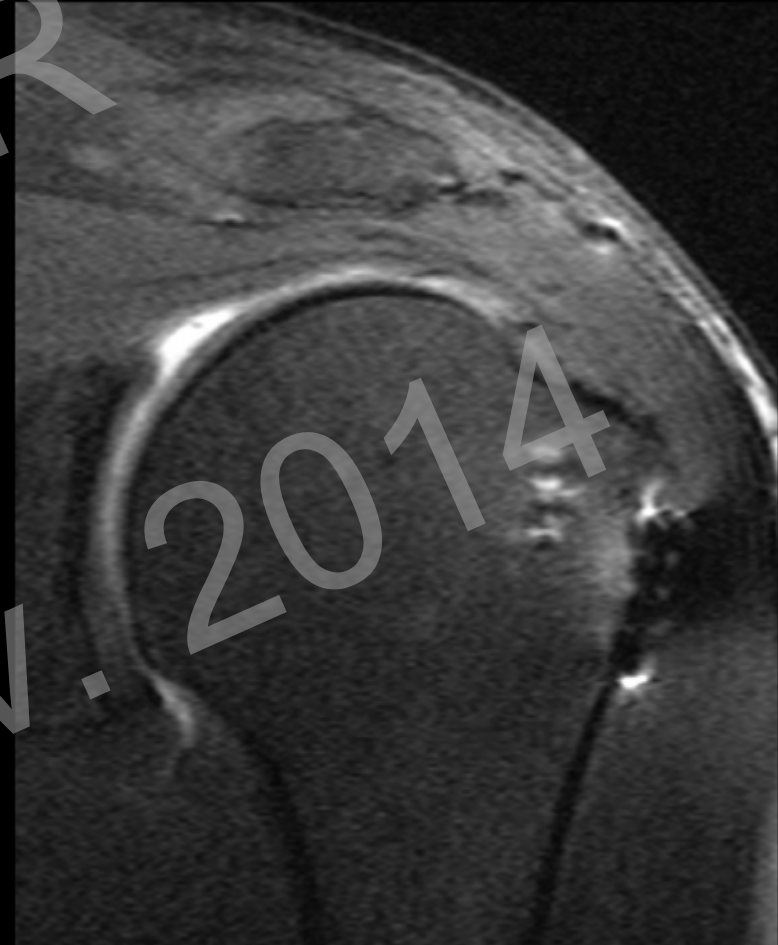
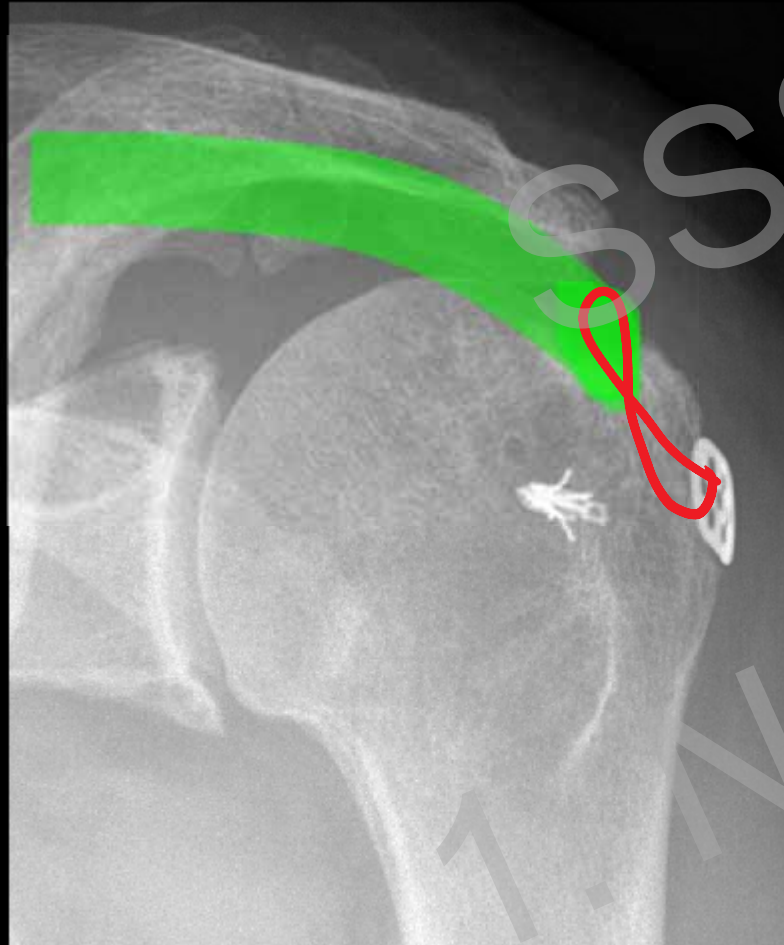
Overview

Instability

Rotator cuff repair

Teaching Points

## Transosseous suture





# Rotator Cuff Repair

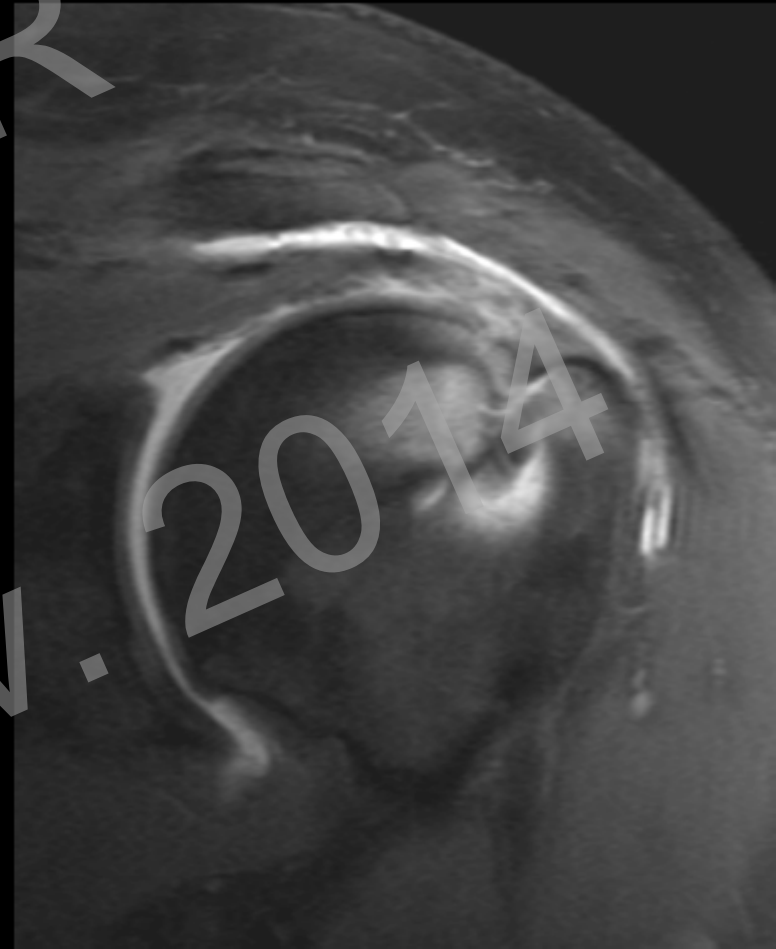
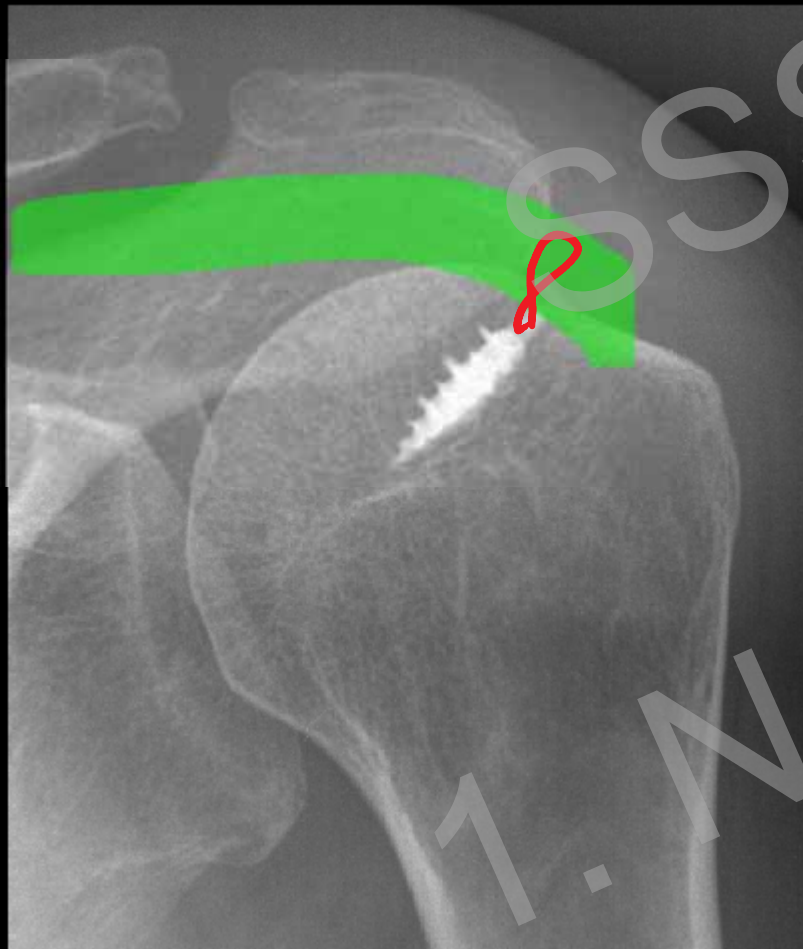
Overview

Instability

Rotator cuff repair

Teaching Points

## Anchor fixation



# Rotator Cuff Repair

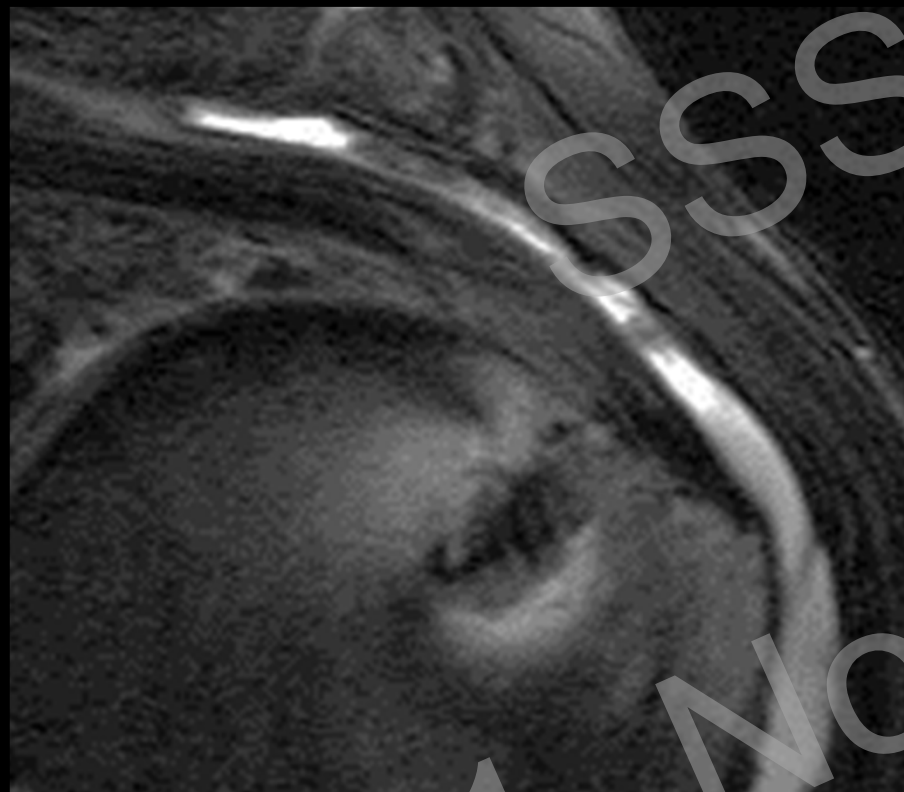Overview

Instability

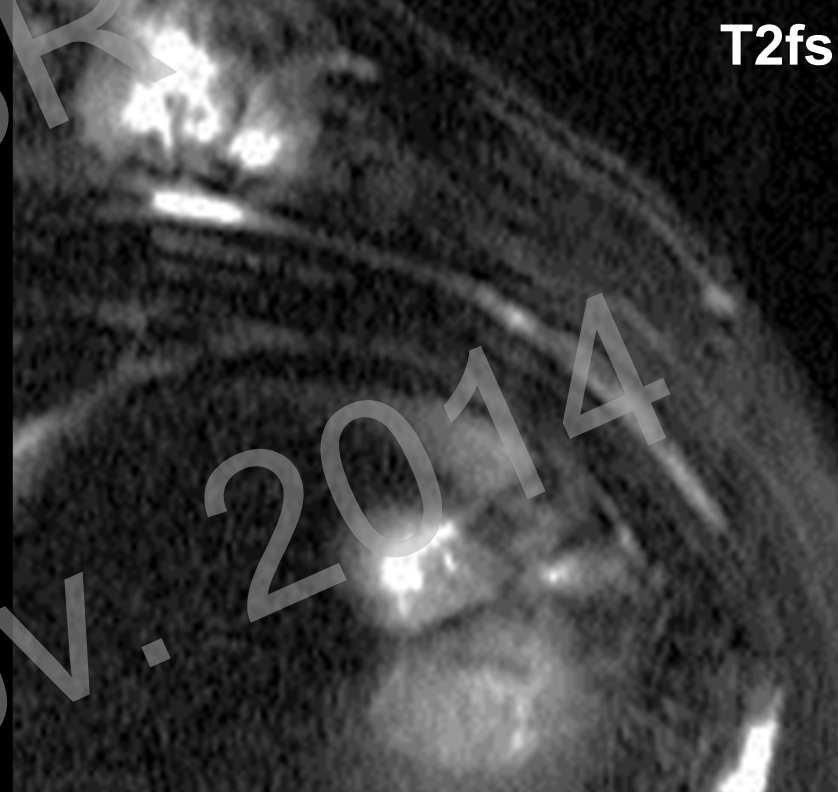
Rotator cuff repair

Teaching Points

How does a tendon look like after surgery?



3 months post-op



2 years post-op

# Rotator Cuff Repair

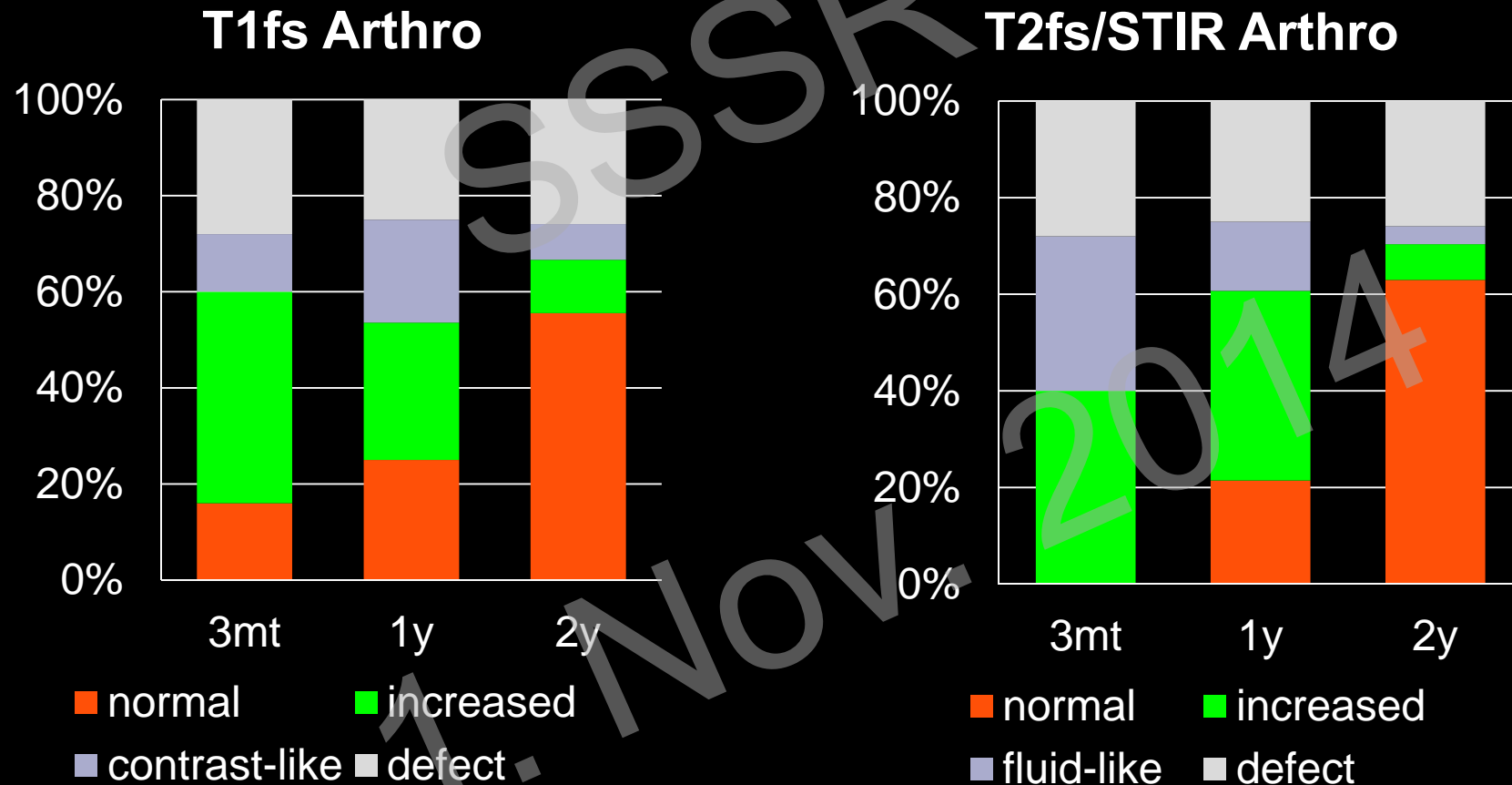
Overview

Instability

Rotator cuff repair

Teaching Points

## Normal tendon signal intensity in MRI after Surgery



# Rotator Cuff Repair



Overview

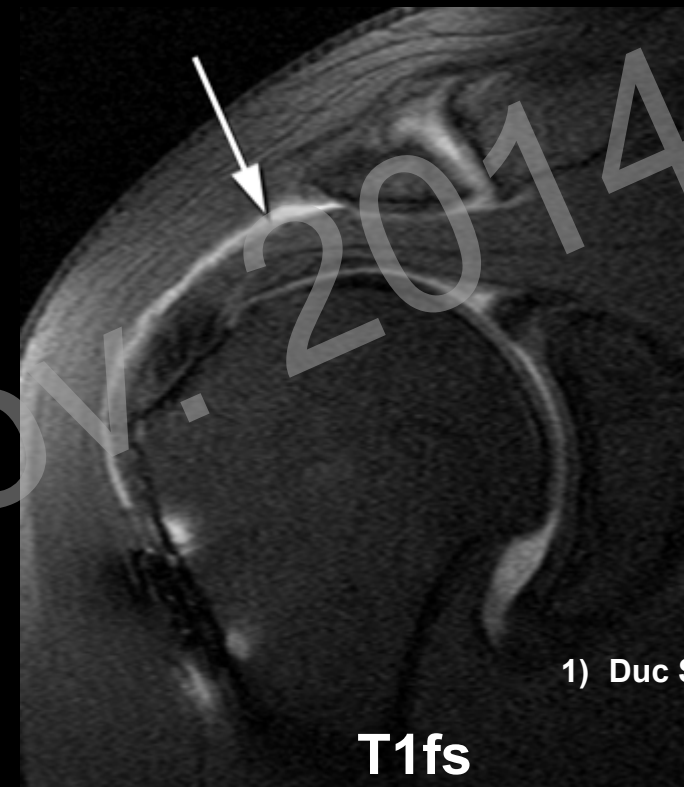
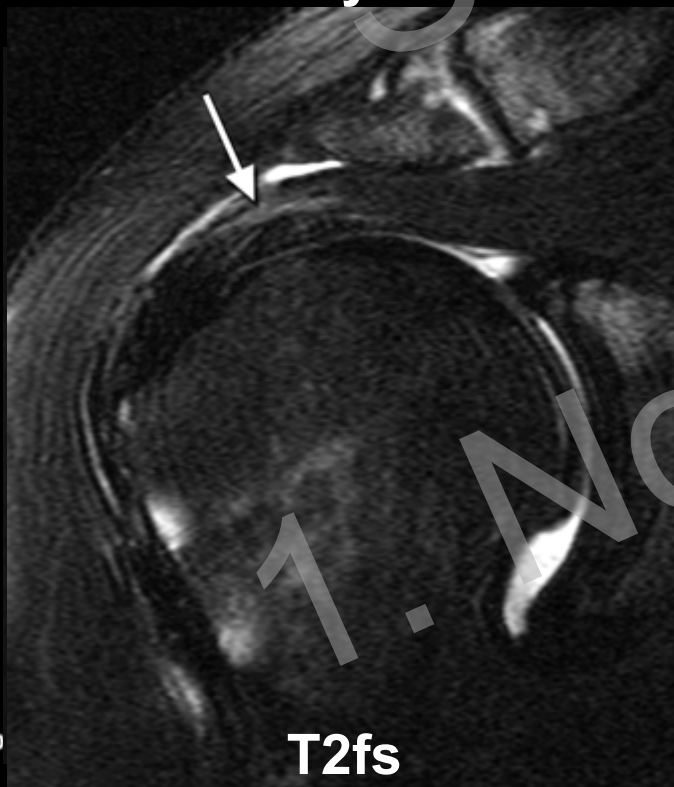
Instability

Rotator cuff repair

Teaching Points

## Re-Tear after Rotator Cuff Repair <sup>1</sup>

- Full-thickness re-tears 
- Partial re-tears 
  - often clinically silent



1) Duc SR, AJR 2006

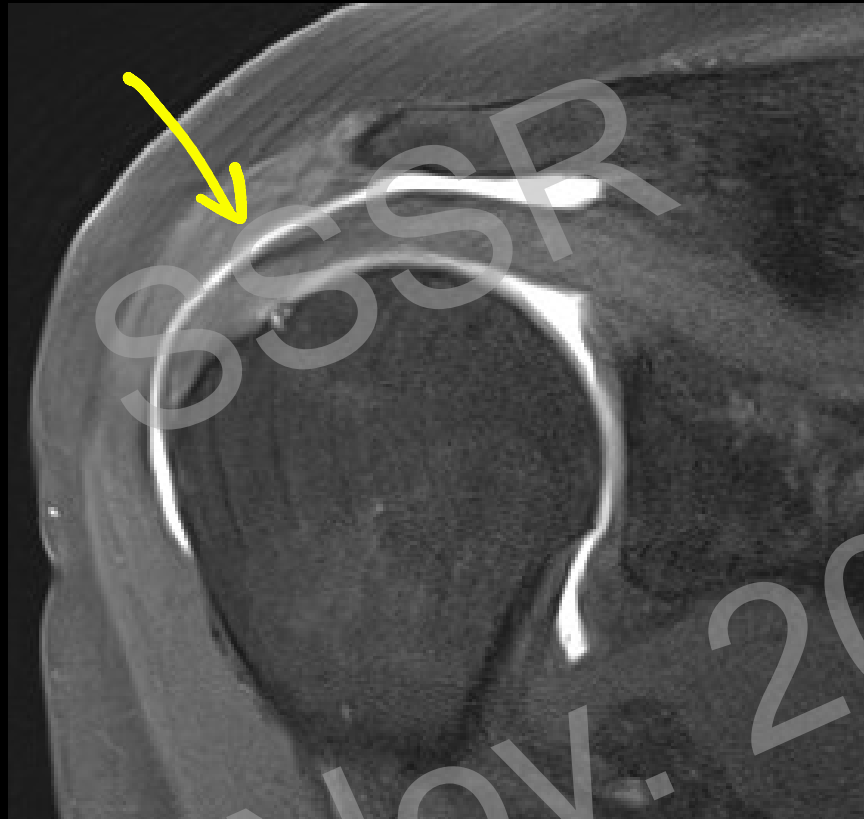
# Rotator Cuff Repair

Overview

Instability

Rotator cuff repair

Teaching Points



- **Contrast subacromial  $\neq$  full-thickness re-tear**
- **Postoperatively rotator cuff is not waterproof**

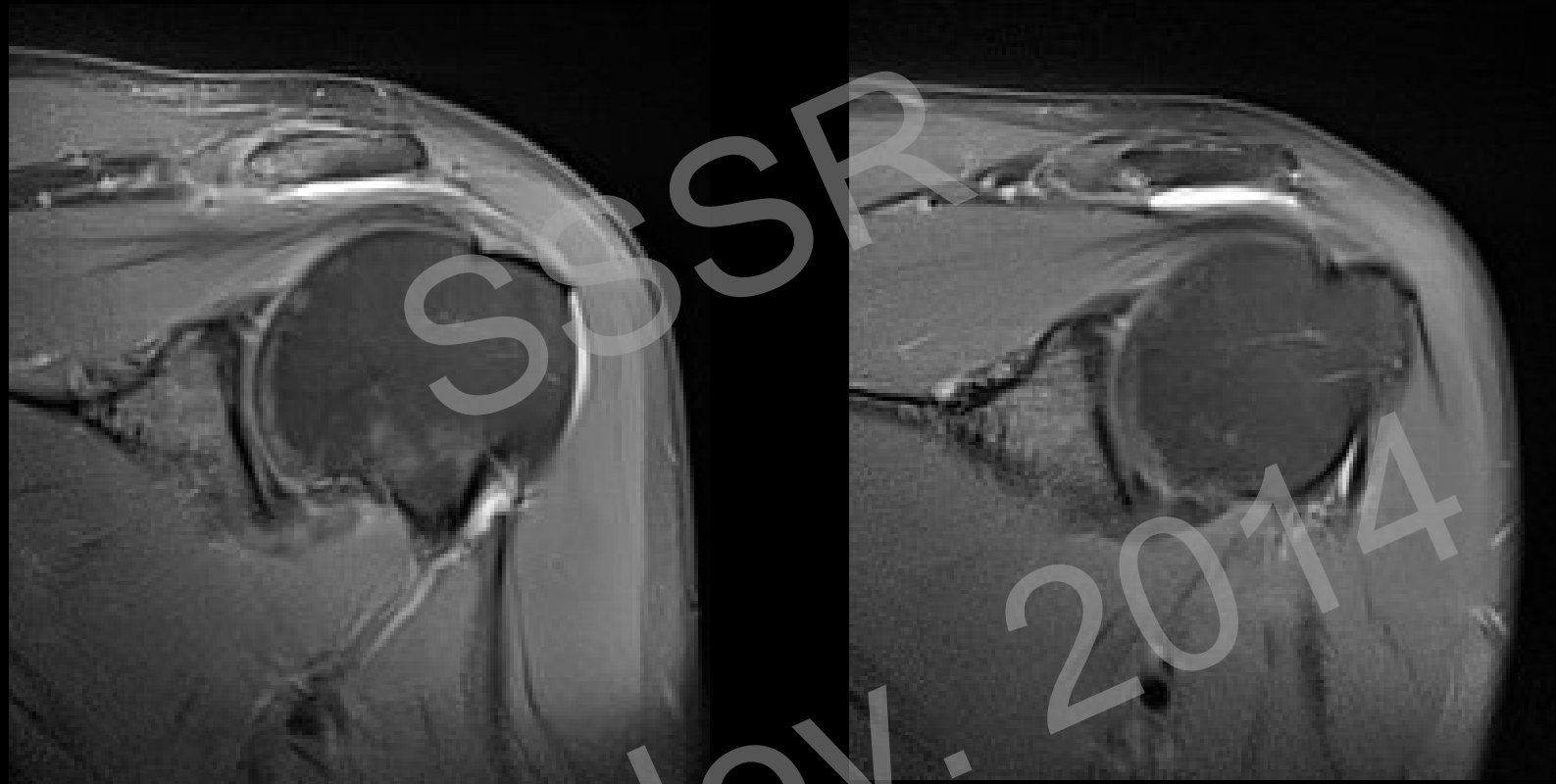
# Rotator Cuff Repair

Overview

Instability

Rotator cuff repair

Teaching Points



Postop

1 year later

- Fluid subacromial = normal postoperative finding
- Persists for years!

# Rotator Cuff Repair

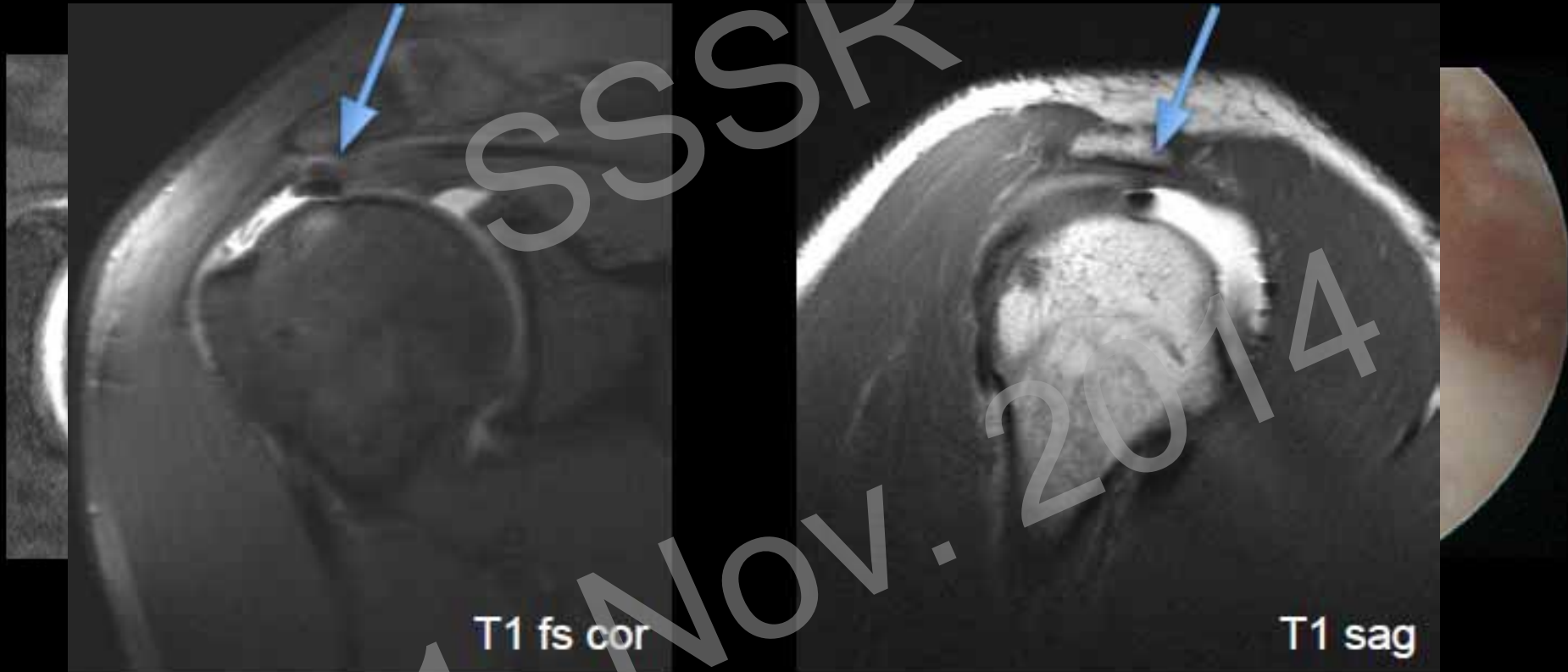
Overview

Instability

Rotator cuff repair

Teaching Points

## Anchor Dislocation



# Rotator Cuff Repair

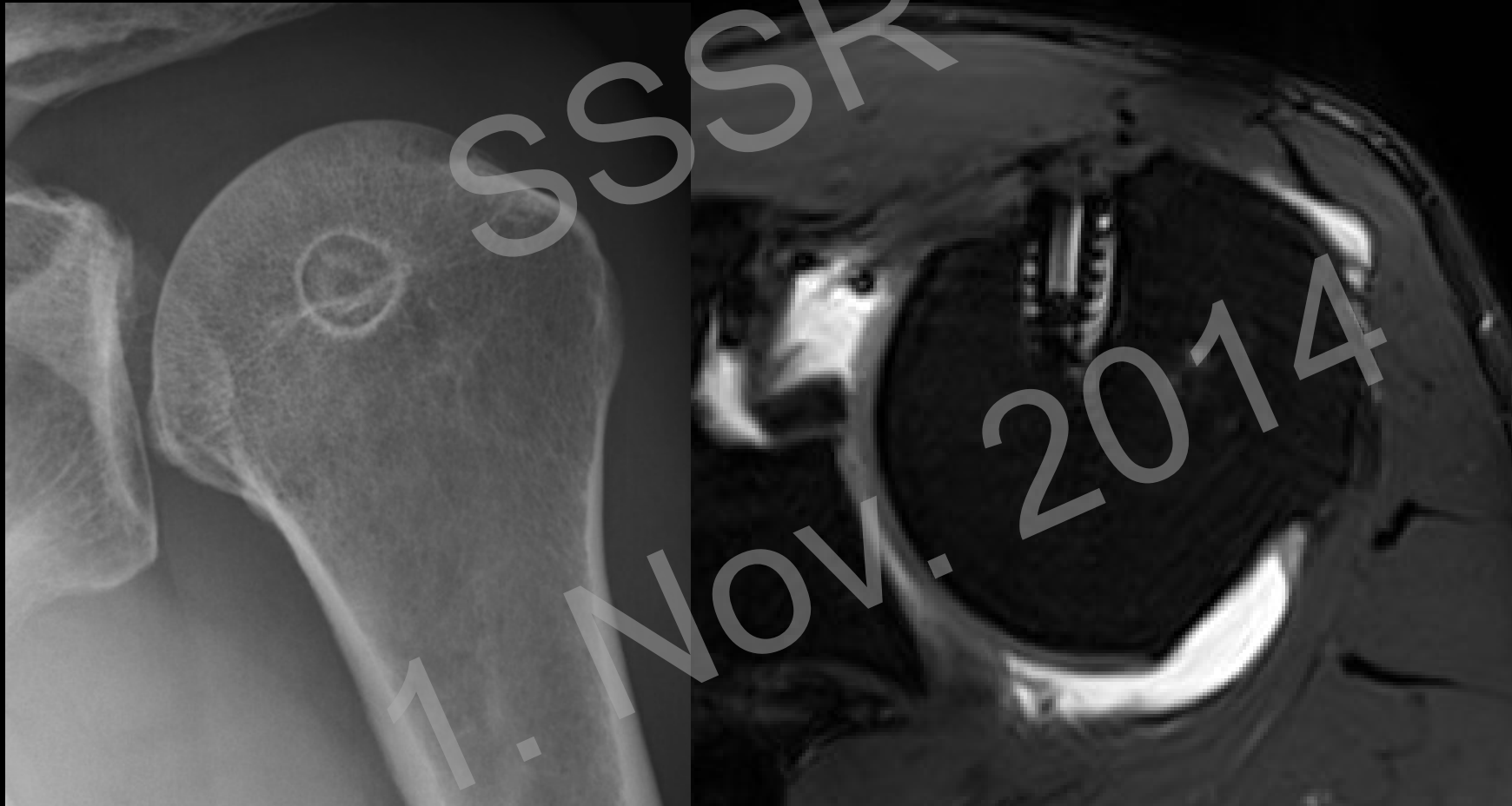Overview

Instability

Rotator cuff repair

Teaching Points

## Anchor Loosening





# Rotator Cuff Repair

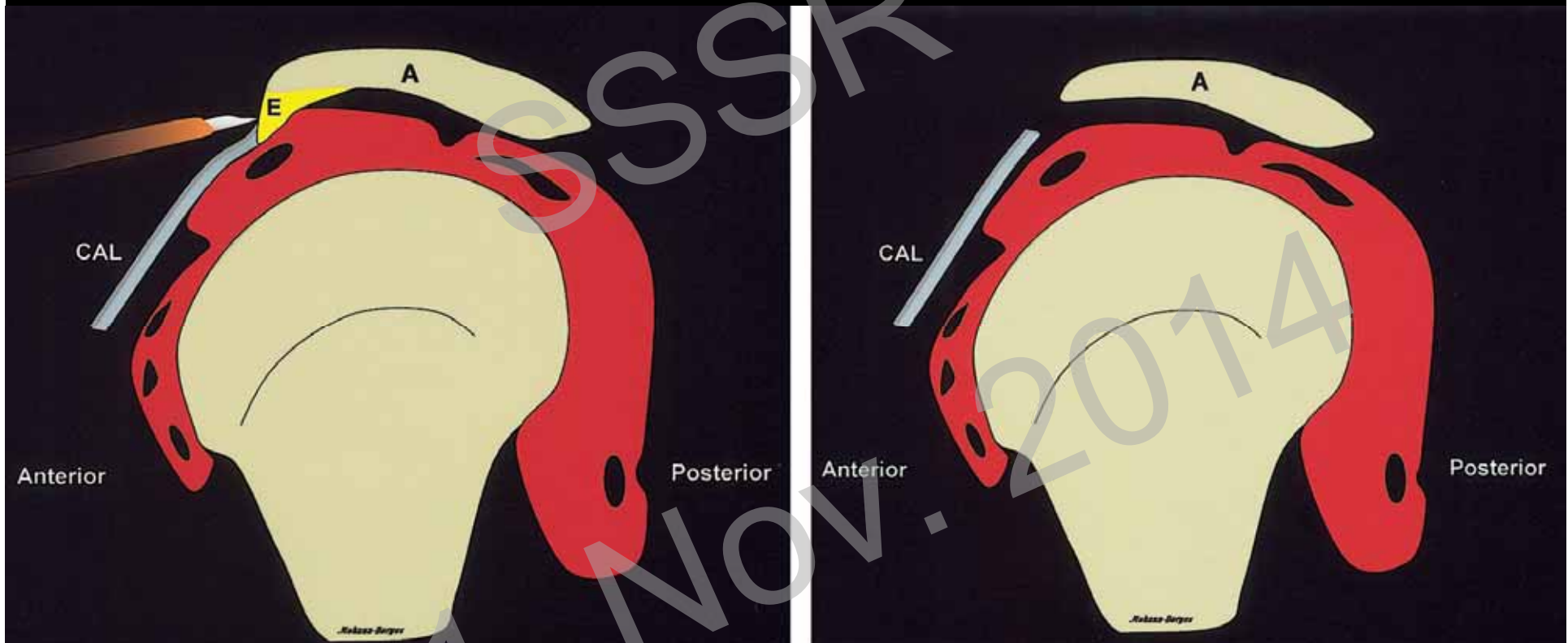
Overview

Instability

Rotator cuff repair

Teaching Points

## Acromioplasty



Mohana-Borges AVR et al. RadioGraphics 2004

# Rotator Cuff Repair

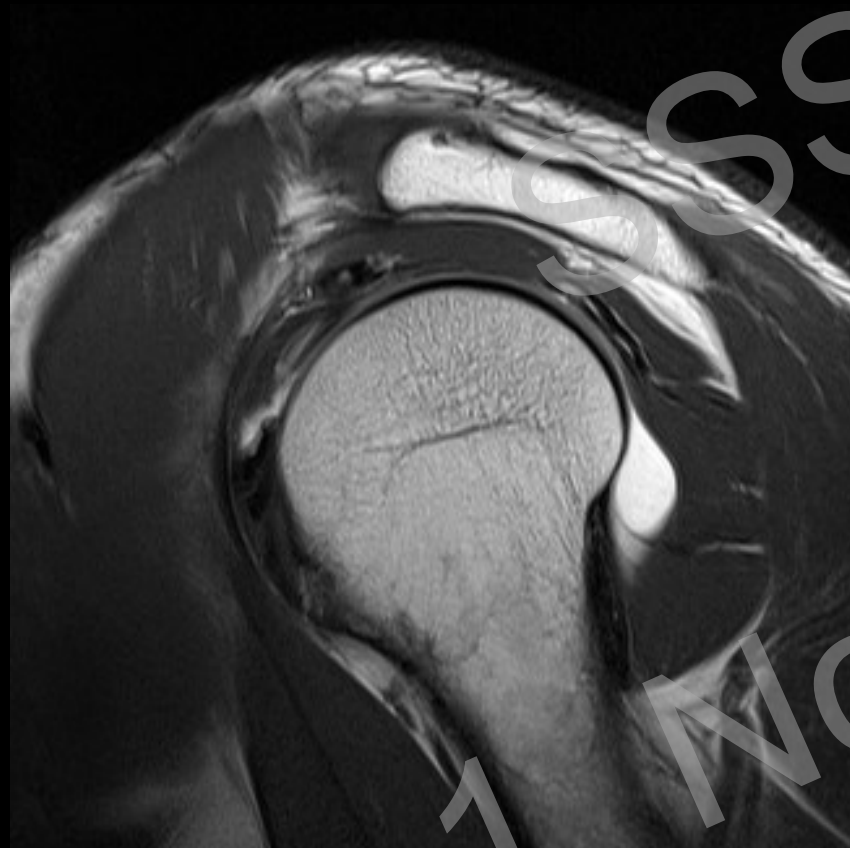Overview

Instability

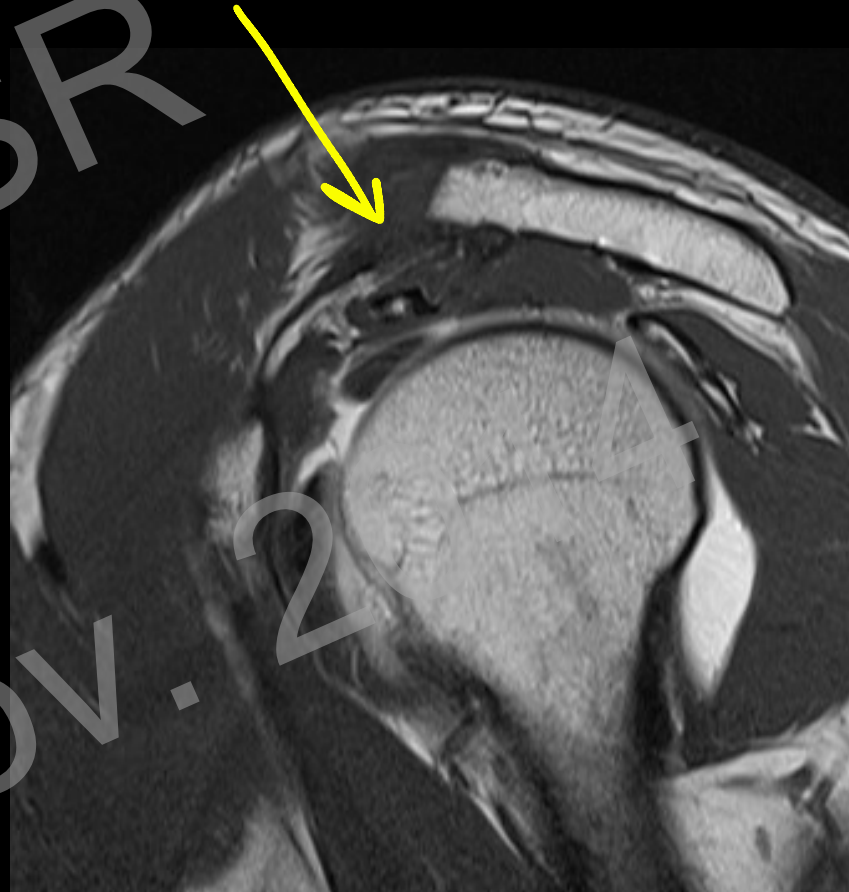Rotator cuff repair

Teaching Points

## Acromioplasty



Preoperative



Postoperative

# Rotator Cuff Repair

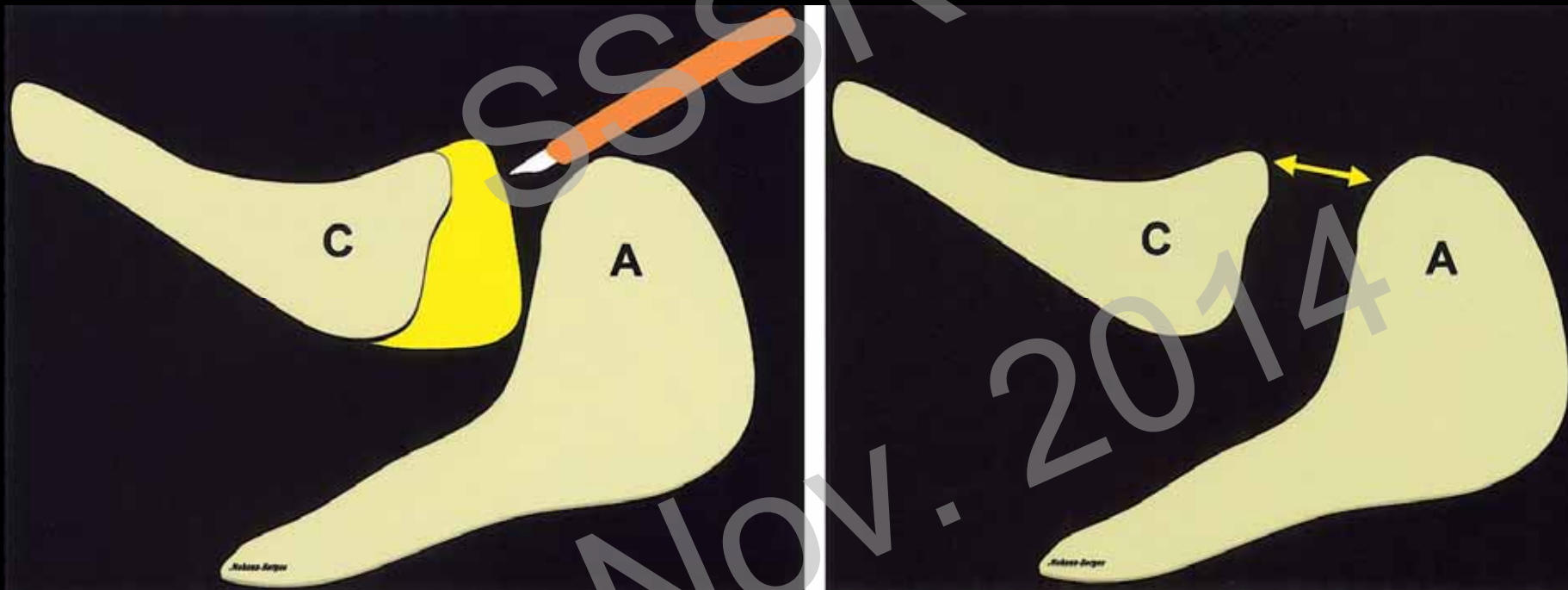
Overview

Instability

Rotator cuff repair

Teaching Points

## Acromioclavicular joint resection



Mohana-Borges AVR et al. RadioGraphics 2004

# Rotator Cuff Repair

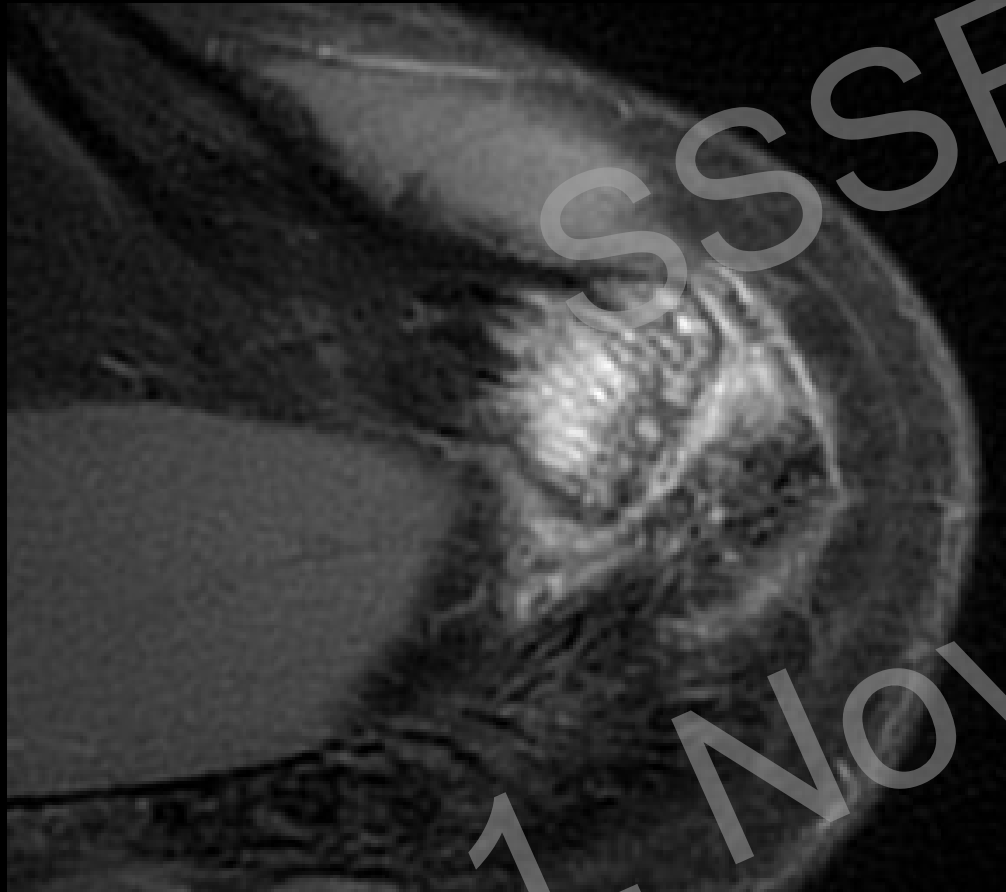
Overview

Instability

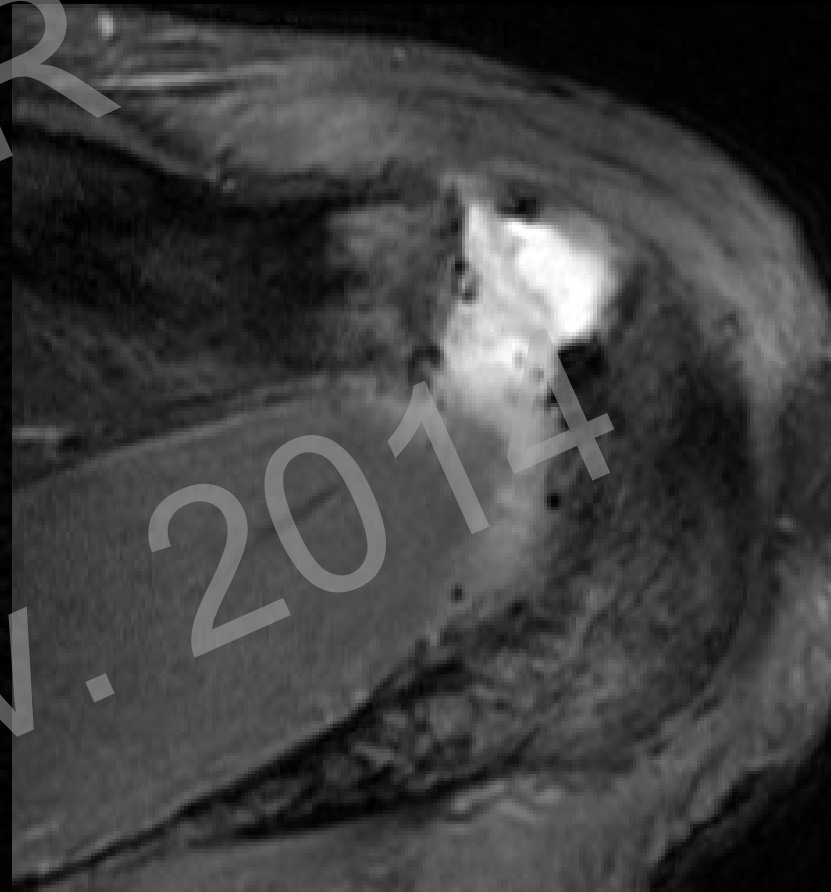
Rotator cuff repair

Teaching Points

## Acromioclavicular joint resection



Preoperative



Postoperative

# Rotator Cuff Repair

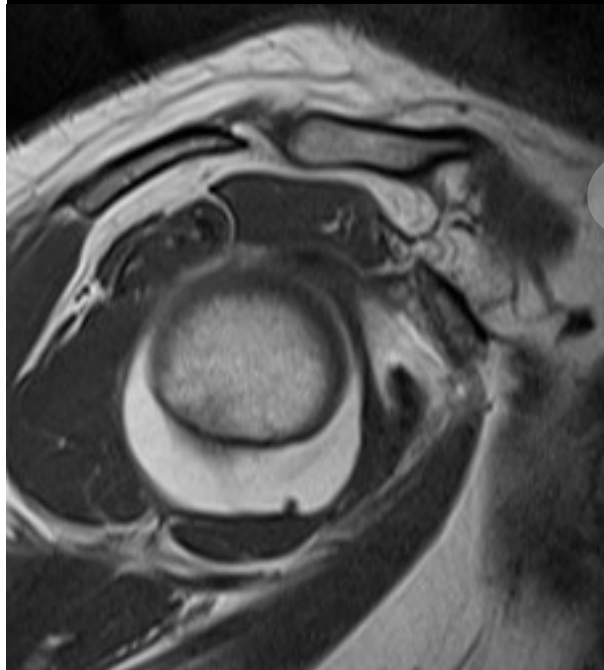
Overview

Instability

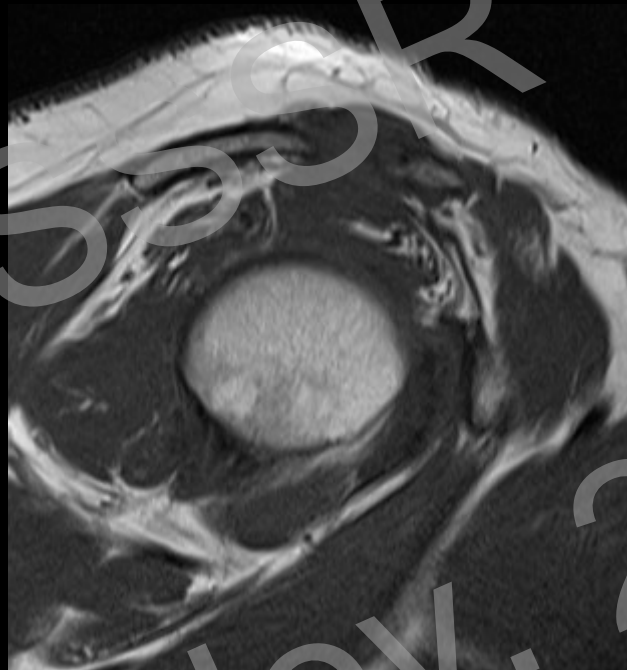
Rotator cuff repair

Teaching Points

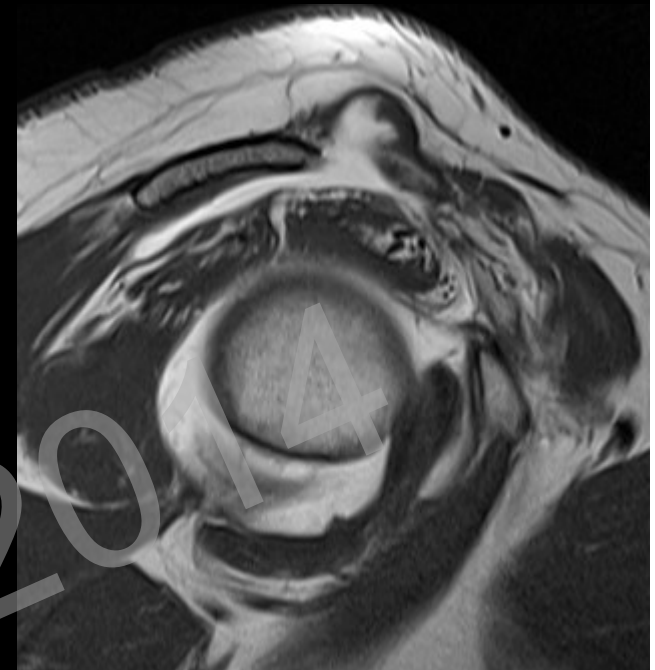
## Cuff capture – captured shoulder<sup>1</sup>



Preoperative



Adhesions  
after AC-joint resection



After release

# Rotator Cuff Repair

Overview

Instability

Rotator cuff repair

Teaching Points

## Deltoid muscle

→ DON'T FORGET!

- Important for reverse shoulder prosthesis
- 3 parts (clavicular, acromial, spinal)
- Innervated by axillary nerve

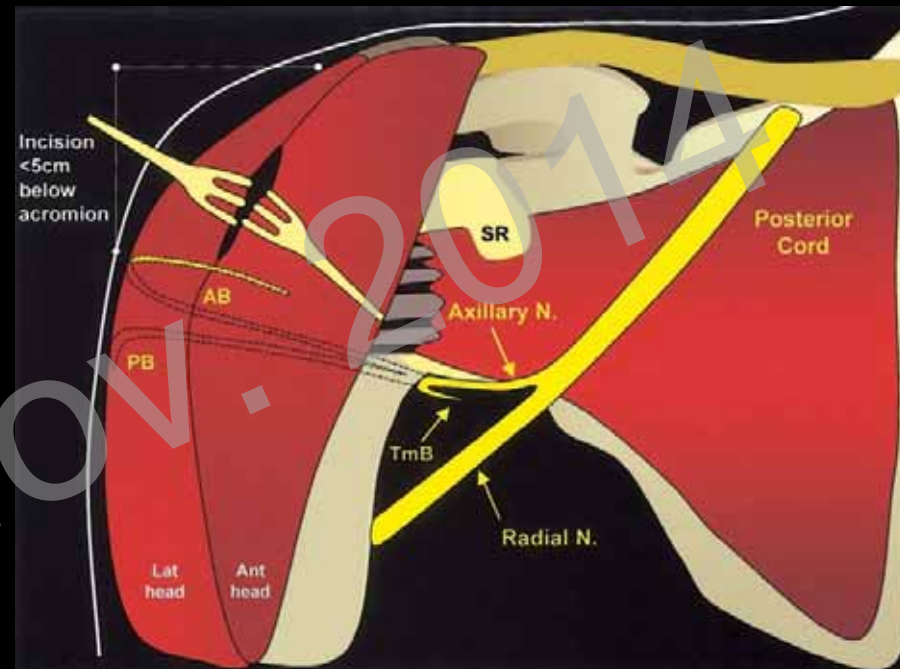


Image from Mohana-Borges AVR et al. RadioGraphics 2004

# Rotator Cuff Repair

Overview

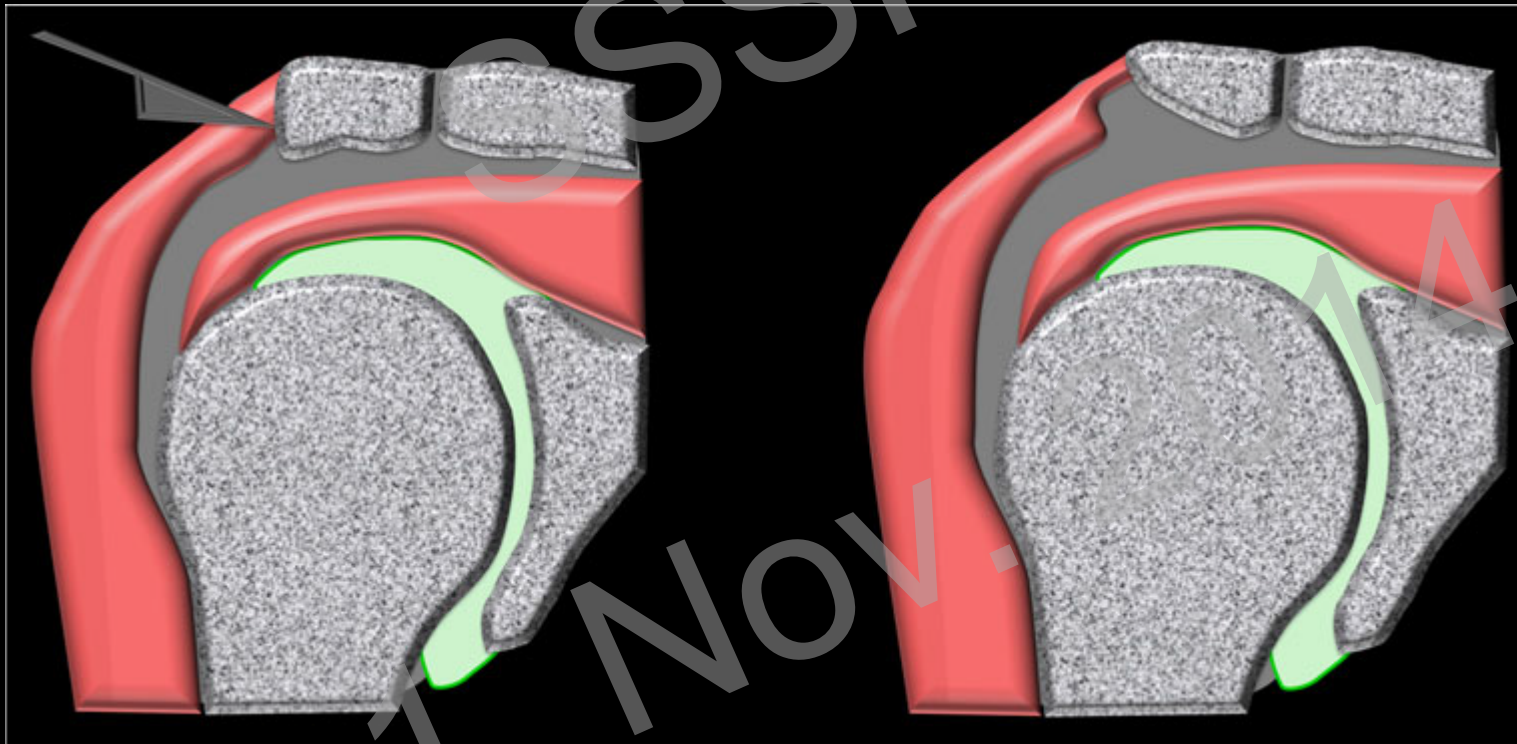
Instability

Rotator cuff repair

Teaching Points

## Postoperative deltoid detachment

- **Complication of shoulder surgery and acromioplasty**



Moser T, Skeletal Radiol 2013

# Rotator Cuff Repair

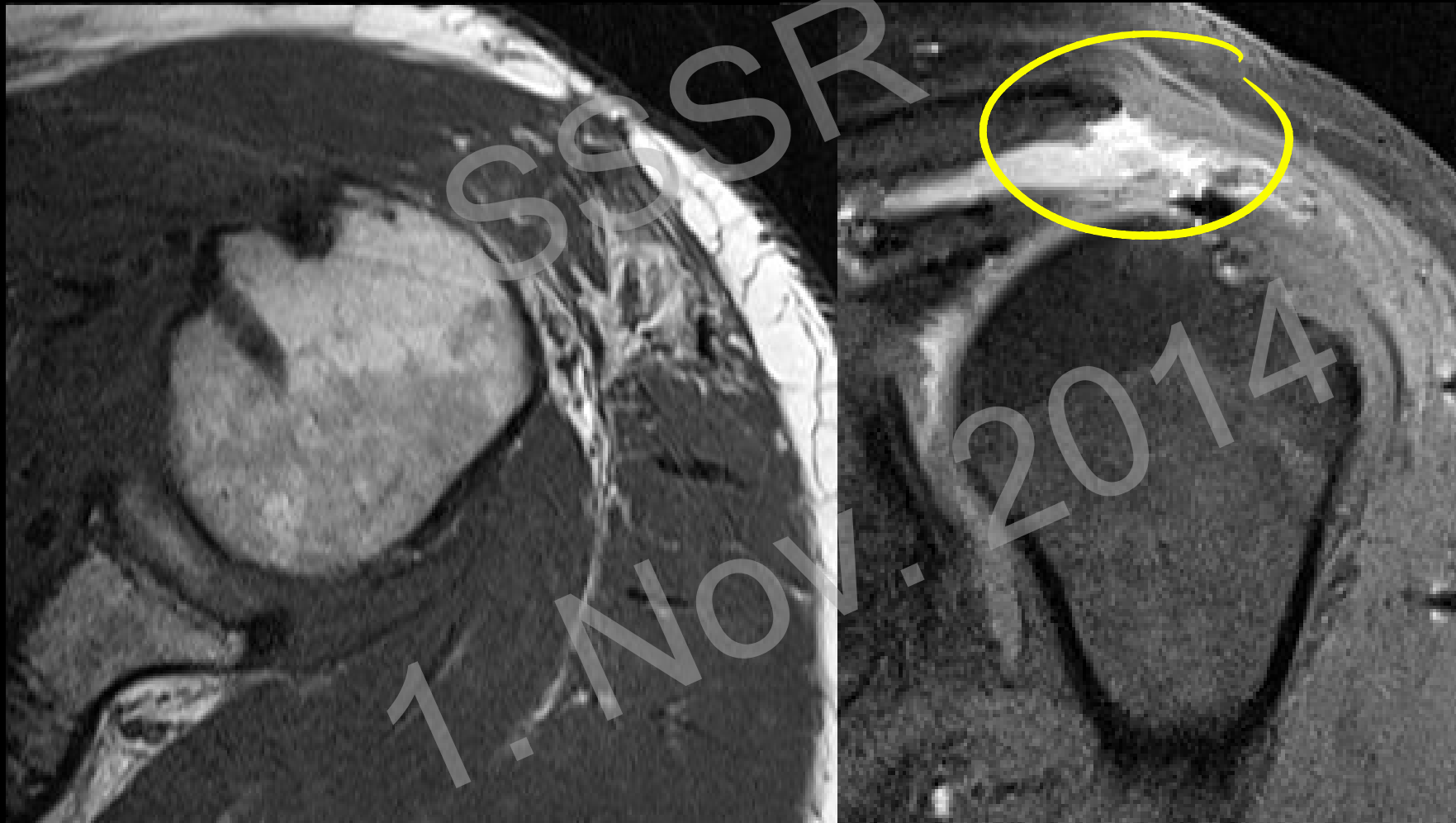Overview

Instability

Rotator cuff repair

Teaching Points

## Deltoid tears in MRI





# Teaching Points

Overview

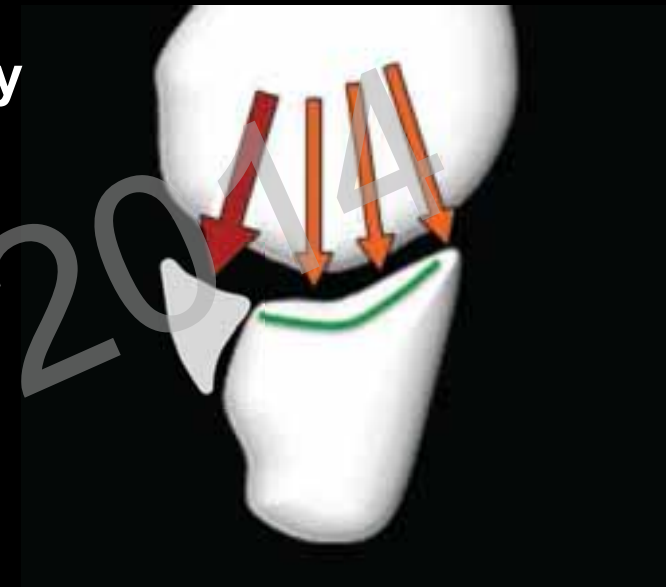
Instability

Rotator cuff repair

Teaching Points

## Instability

- Postoperative labrum - altered anatomy
- Anchor position & complications
- Glenoid bone loss & coracoid transfer



# Teaching Points

Overview

Instability

Rotator cuff repair

Teaching Points

## Rotator cuff Repair

- Tendon signal change over time after surgery
- Subacromial fluid  $\neq$  Bursitis
- Subacromial contrast  $\neq$  full-thickness re-tear
- Deltoid muscle

