

Infektsanierung und Weichteil- rekonstruktion beim diabetischen Fuss-Infekt

PD Dr Maurizio Calcagni

Div. Plastic Surgery and Hand Surgery (Prof. P. Giovanoli)

University Hospital Zürich

Introduction

- Debridement
- Reconstruction needs
- Evidences
- Reconstruction strategies
- Take home message

Symposium zum Diabetischen Fuss
27. Nov. 2015

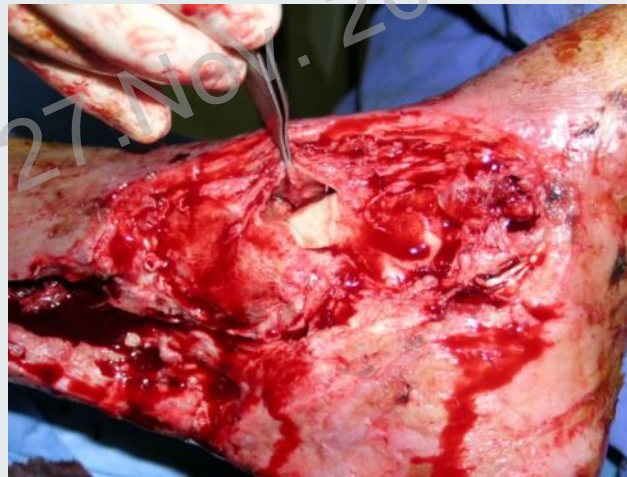
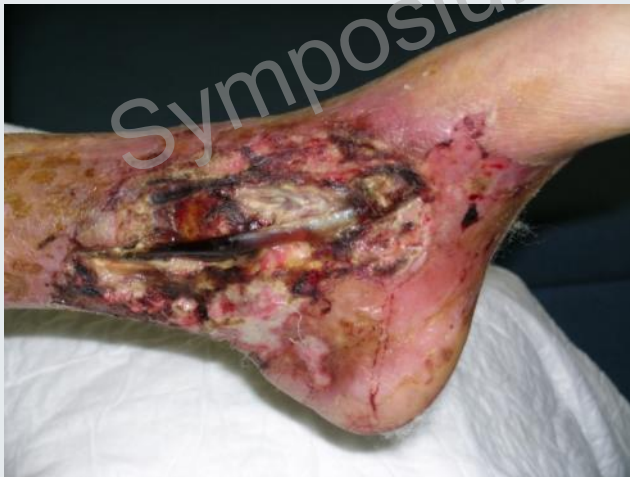
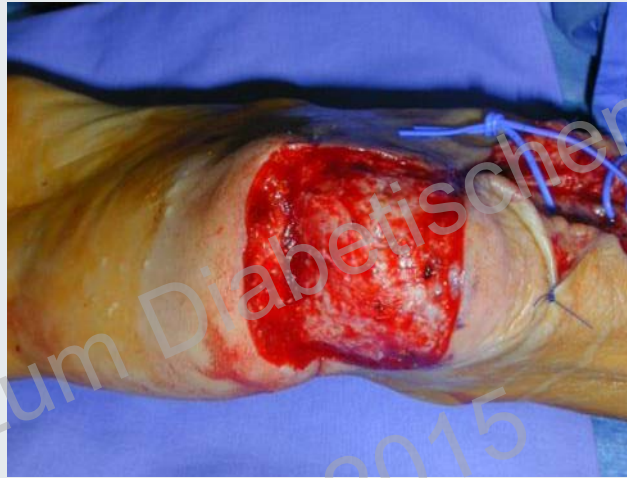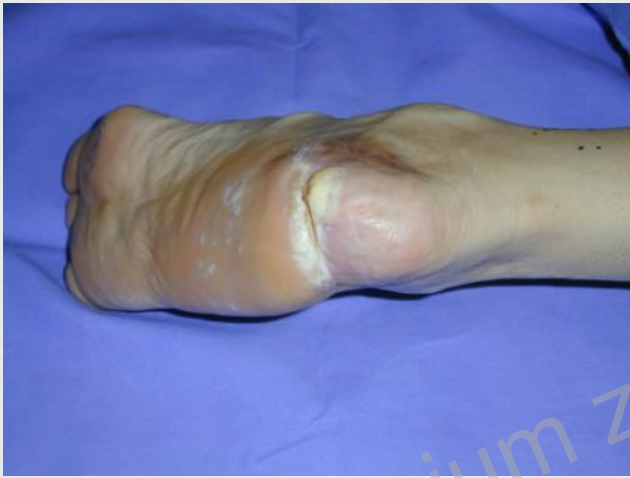Debridement

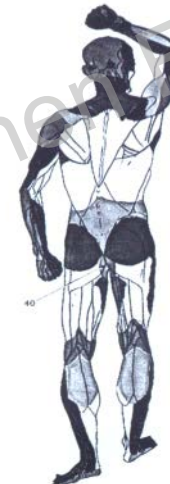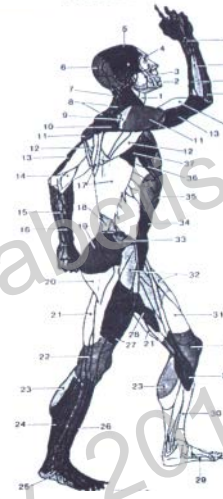
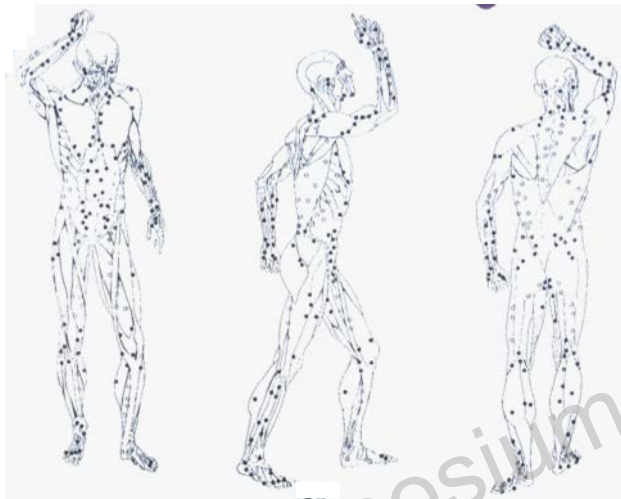
- Radical, „oncological“
- Retain vital structures, but all devitalized bones, tendons and bands have to be resected
- If necessary one or more second-look debridements and VAC dressing

Symposium zum Diabetischen Fuss
27. Nov. 2015

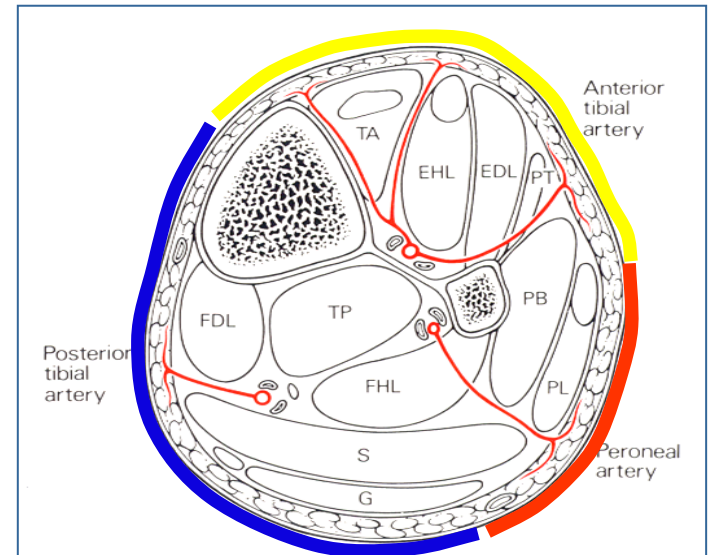
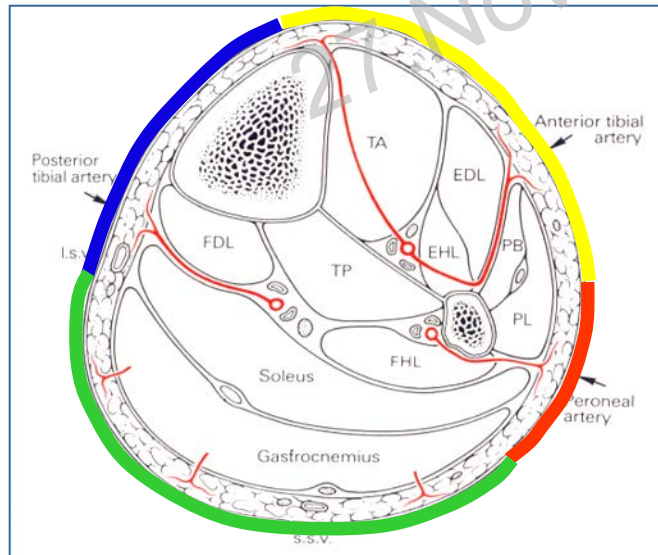
Debridement



Angiosomes concept



J. Taylor, 1978



Angiosomes

Angiosomes of the Foot and Ankle and Clinical Implications for Limb Salvage: Reconstruction, Incisions, and Revascularization

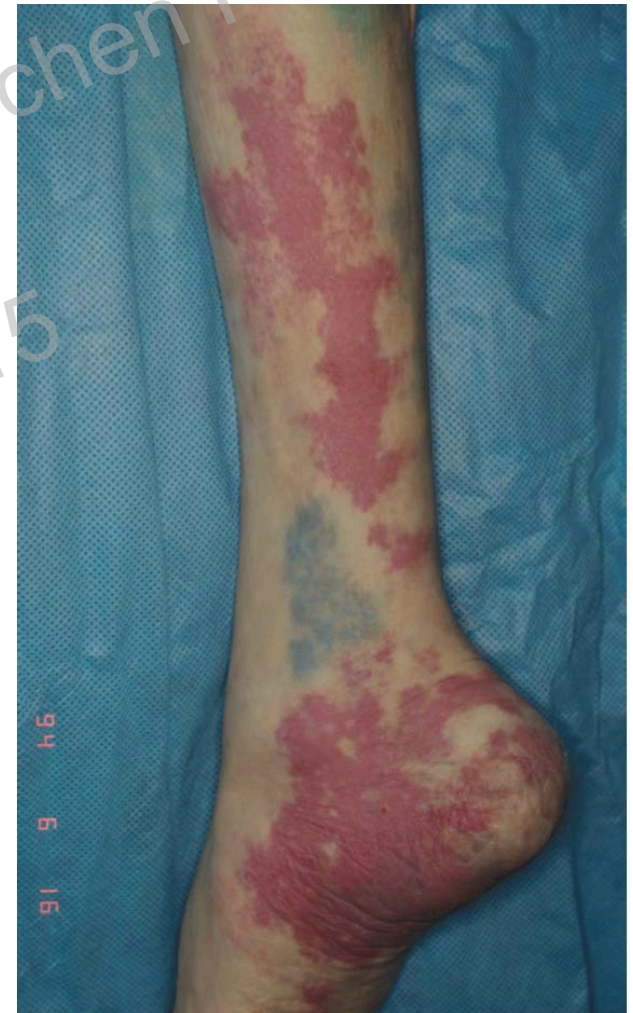Christopher E. Attinger,
M.D.

Plast Reconstr Surg, 2006

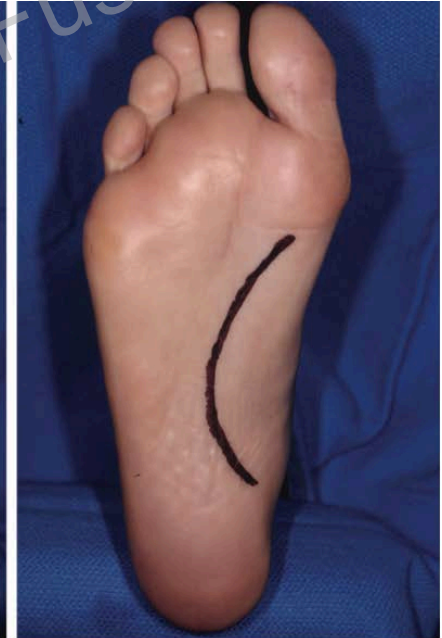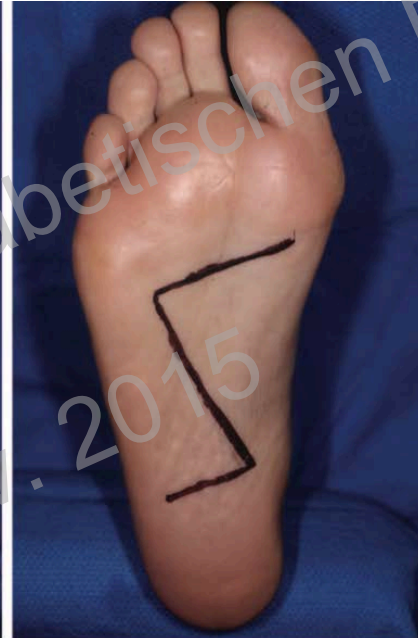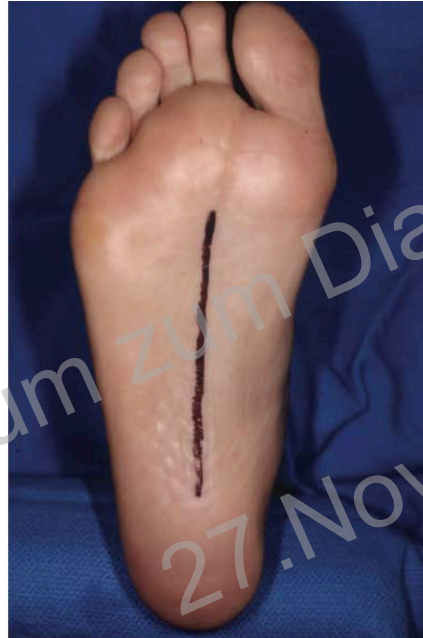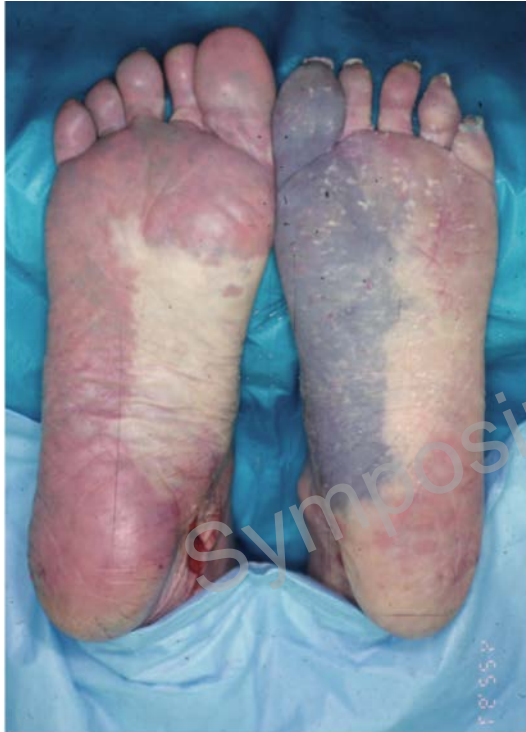Karen Kim Evans, M.D.
Erwin Bulan, M.D.
Peter Blume, D.P.M.
Paul Cooper, M.D.

*Washington, D.C.; New Haven,
Conn.; and Millburn, N.J.*

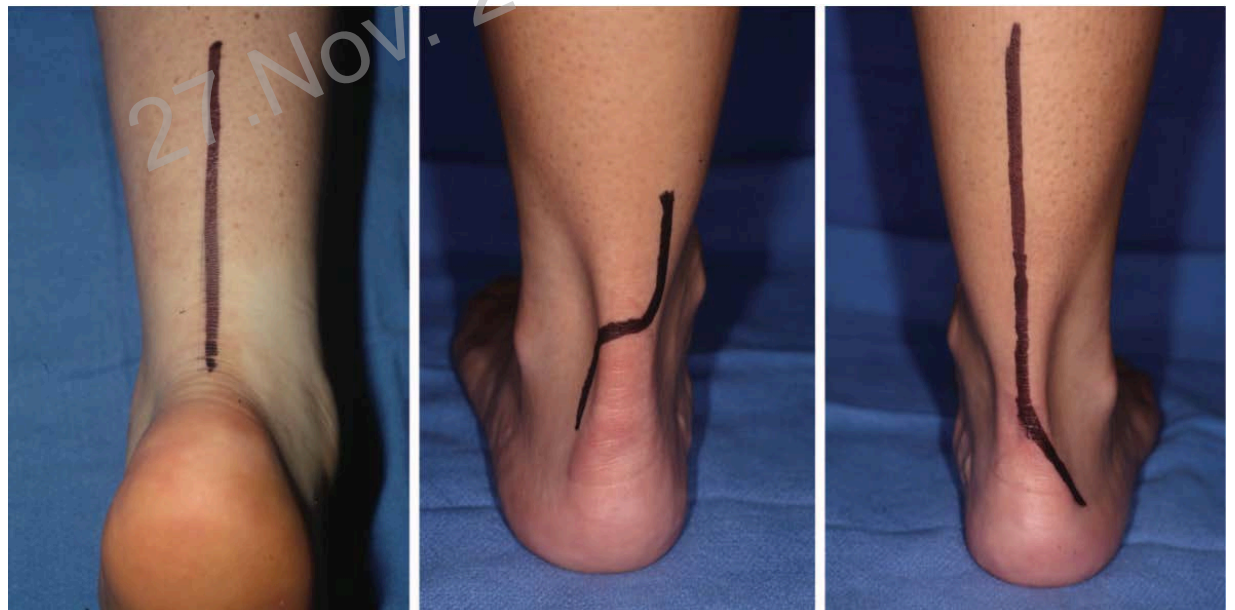
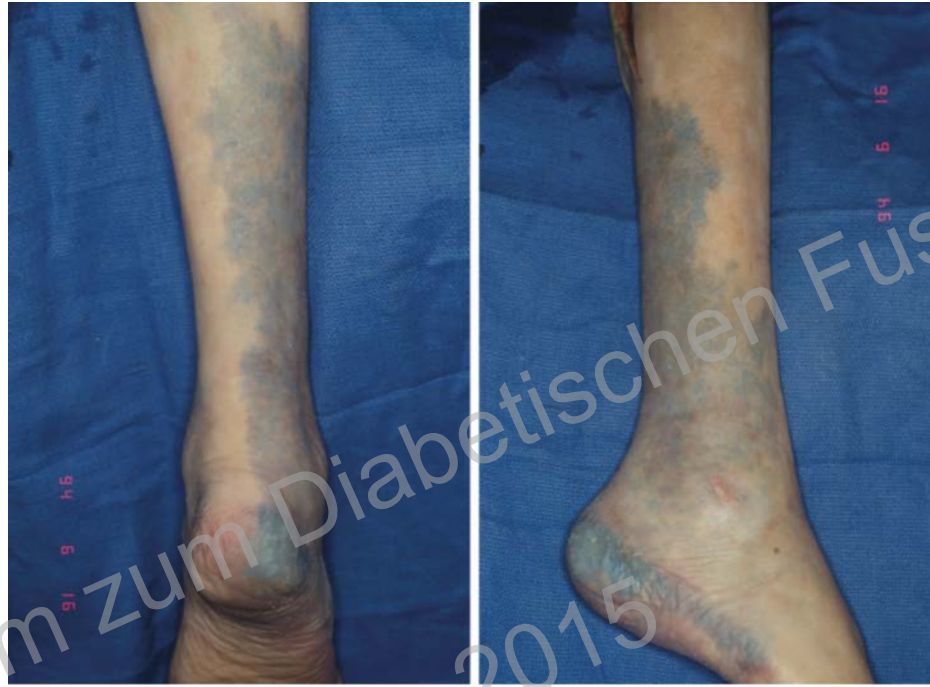Symposium zum Diabetischen Fuss
27. Nov. 2015



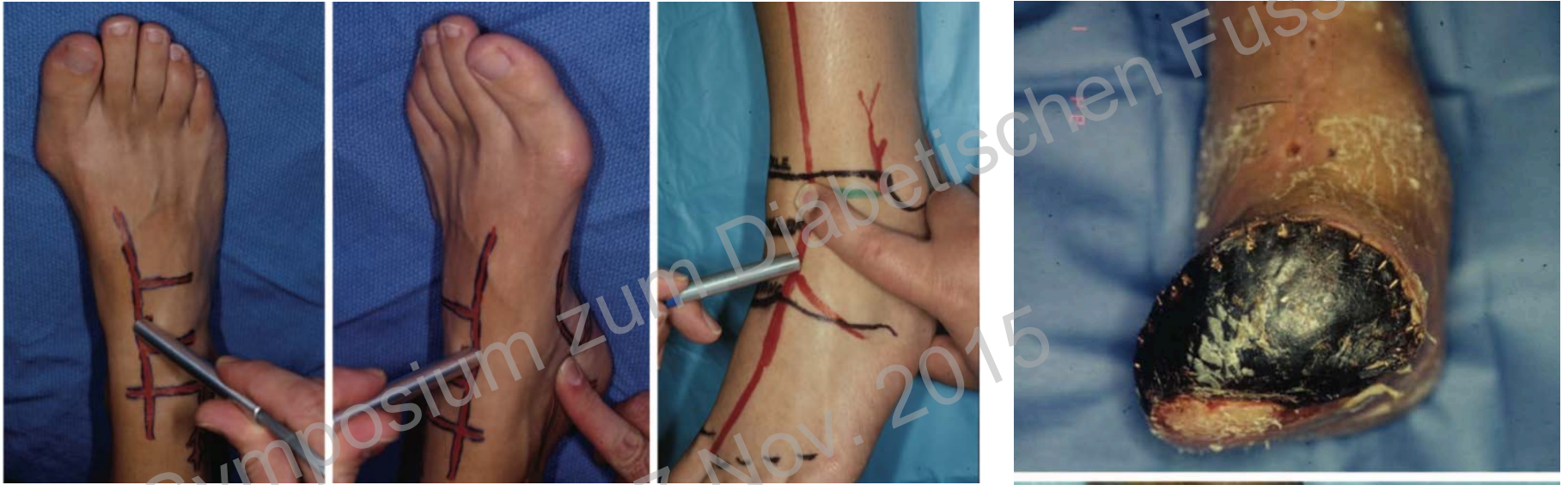Angiosomes



Angiosomes



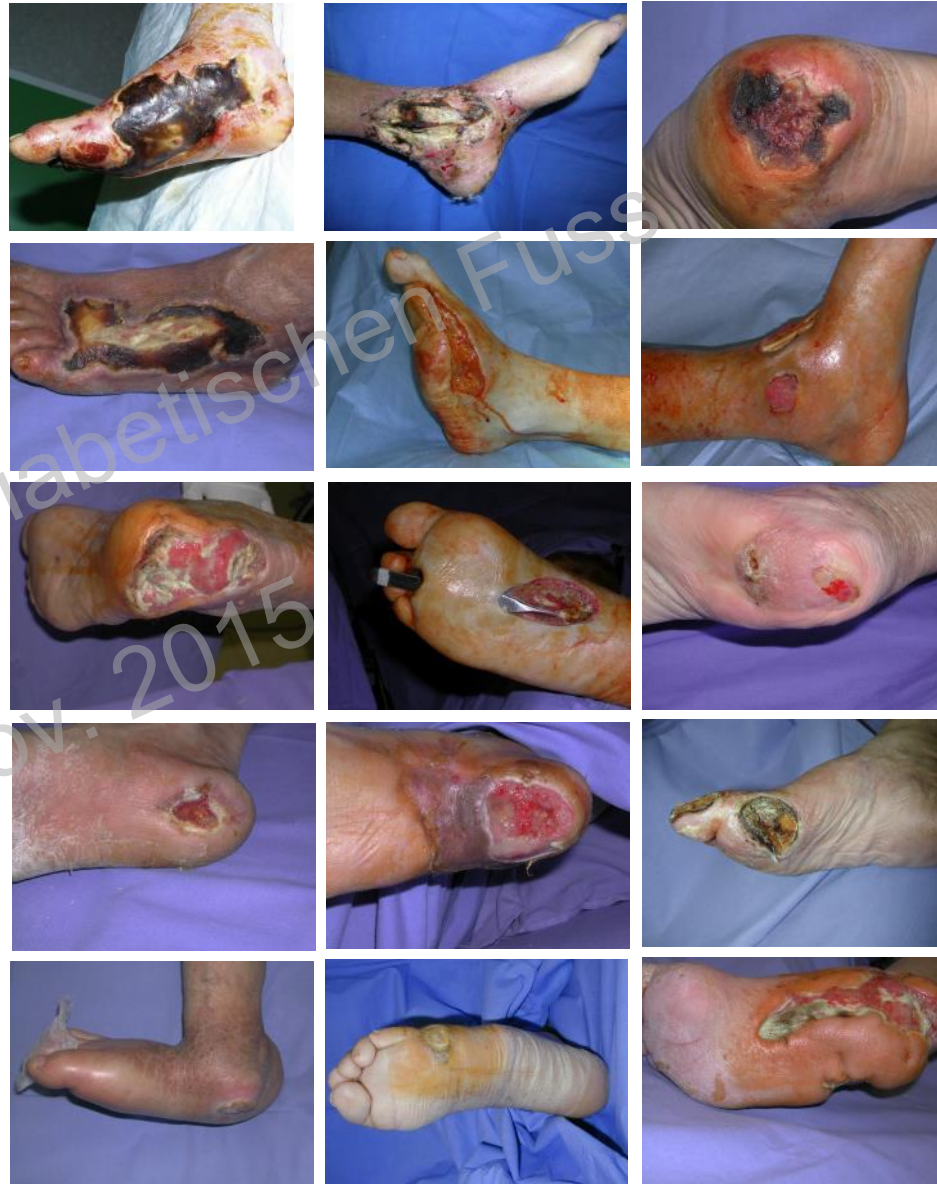Angiosomes



Symposium zum Diabetischen Fuss
27. Nov. 2015

Reconstruction needs

- Limb salvage
- Long lasting results
- Low donor area morbidity
- Low impact on the patient
- Revascularization



Evidences



The Cochrane Collaboration

Working together to provide the best evidence for health care

Published Reviews and Protocols

[Full list](#) [By Subtopic](#) [New + Updated](#) [Other Languages](#)

(stage filter not available for subtopic view)

By subtopic:

- ▷ ACUTE WOUNDS (2)
- ▷ BITES (3)
- ▷ BURNS (18)
- ▷ CHRONIC WOUNDS (1)
- ▽ DIABETIC FOOT ULCERS (30)
 - ▷ Prevention (4)
 - ▽ Treatment (26)
 - ▷ Local wound care (16)
 - ▷ Nutrition (1)
 - ▷ Organisation of care (1)
 - ▷ Physical therapies (4)
 - ▷ Pressure reduction and relief (1)
 - ▷ Skin replacements (0) ←
 - ▷ Systemic drug therapy (3)

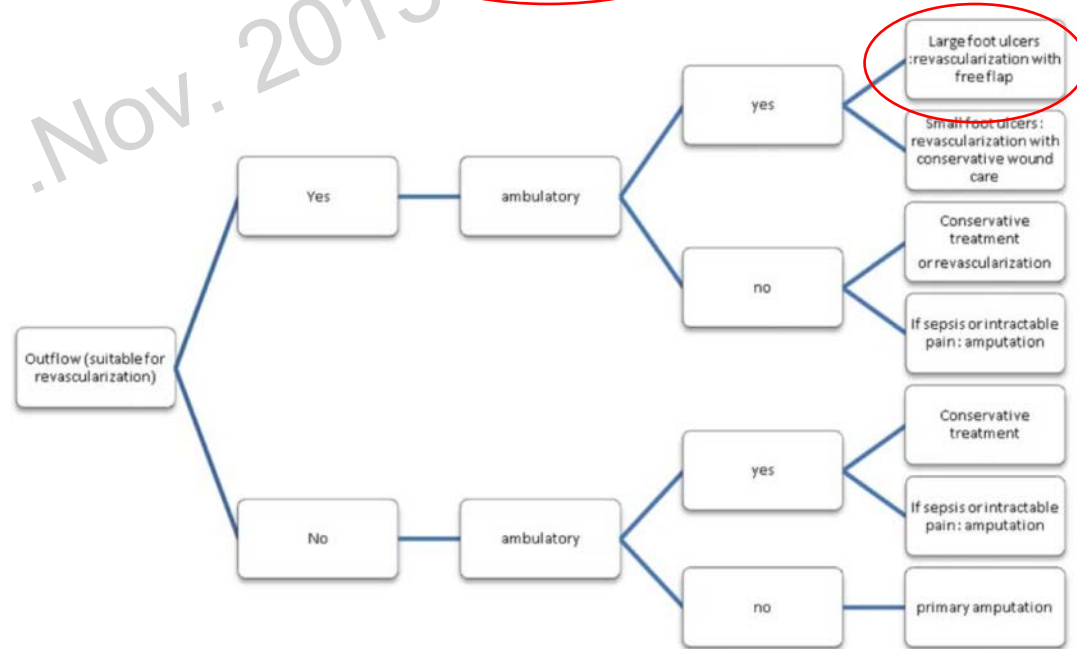
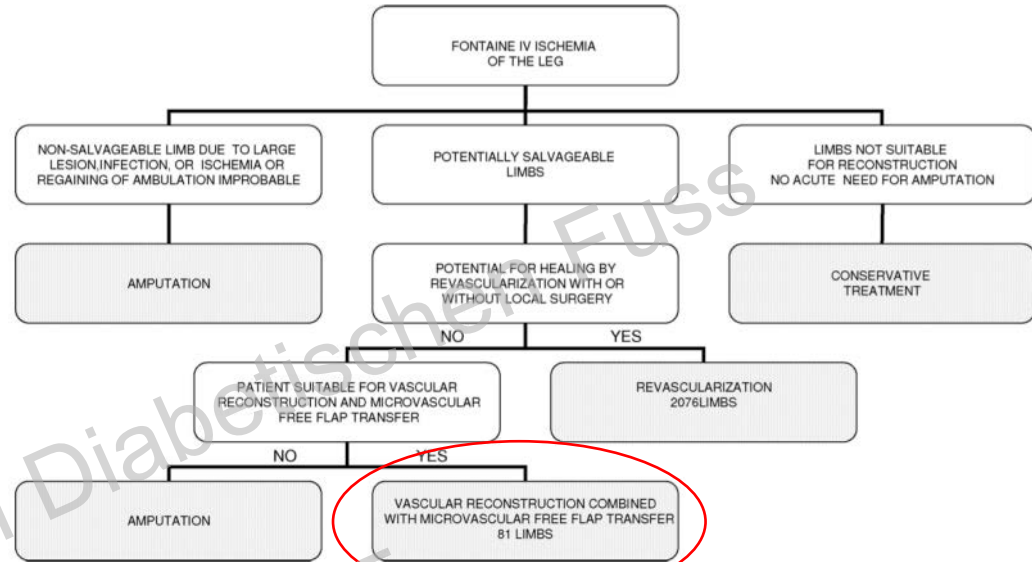
Symposium zum Diabetischen Fuss
27. Nov. 2015

Evidences

Advanced Leg Salvage of the Critically Ischemic Leg With Major Tissue Loss by Vascular and Plastic Surgeon Teamwork Long-term Outcome

Erkki Tukiainen, MD, PhD,* M. Kallio, MD,*† and M. Lepäntö, MD, PhD†

Ann Surg, 2006



World J Surg (2010) 34:177-184
DOI 10.1007/s00268-009-0250-9



Outcome of Arterial Reconstruction and Free-Flap Coverage in Diabetic Foot Ulcers: Long-Term Results

Caren Randon · Frank Vermassen · Bart Jacobs ·
Frederik De Ryck · Koenraad Van Landuyt ·
Yoeri Taes



Evidences

Chapter V: Diabetic Foot

M. Lepäntalo^{a,b,*}, J. Apelqvist^{c,d}, C. Setacci^e, J.-B. Ricco^f, G. de Donato^e, F. Becker^g, H. Robert-Ebadi^g, P. Cao^h, H.H. Ecksteinⁱ, P. De Rango^k, N. Diehm^l, J. Schmidli^m, M. Teraa^{n,o}, F.L. Mollⁿ, F. Dick^m, A.H. Davies^p

5.8. Microvascular flaps

Microvascular free flaps may be used to cover large tissue defects and ulcers overtaking tendons and bones in diabetic feet. In a recent review there were 17 case series, the largest with 79 patients, 85% of whom were diabetics and 66% of whom underwent a procedure combining revascularisation and free flap transfer.¹⁰⁹ Revascularisations of ischaemic diabetic feet combined with free flap transfer represent only a small fraction – 4% at most – of all interventions to improve diabetic foot perfusion.¹¹⁰

Recommendation

When ischaemia coincides with a large diabetic foot defect, major amputation may be prevented in an ambulatory patient by combining revascularisation with microvascular flap transfer.¹⁰⁹ **(Level 4; Grade C)**

Reconstruction strategies

- Diagnostics
- Revascularization
- Debridement
- Stabilize patient
- Wound reconstruction

Symposium zum Diabetischen Fuss
27. Nov. 2015



Reconstruction strategies

- Diagnosis
- Revascularization
- Debridement
- Stabilize patient
- **Wound reconstruction**

Symposium zum Diabetischen Fuss
27.Nov. 2015

Surgical techniques and concepts

- Skin grafts
- Dermis equivalent
- Loco-regional flaps
- Free flaps

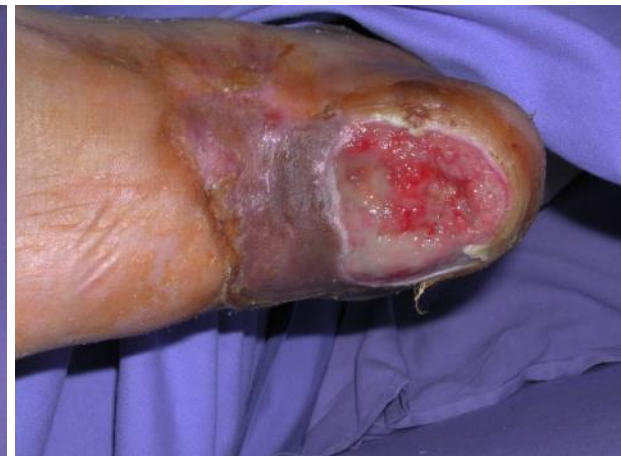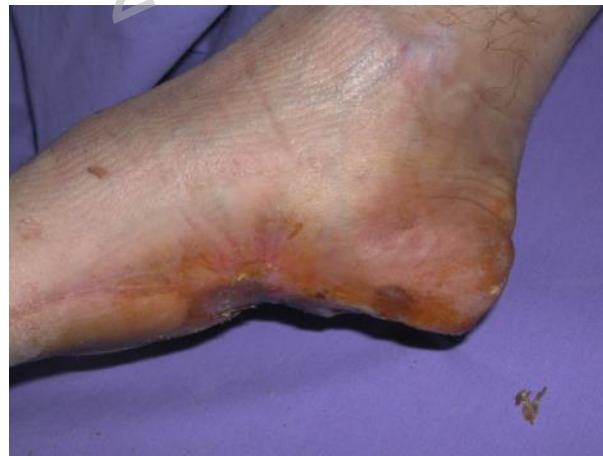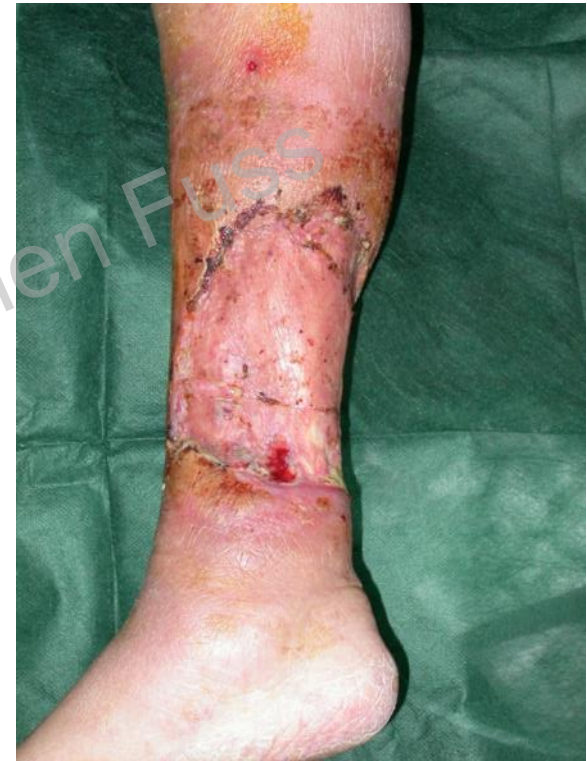Symposium zum Diabetischen Fuss
27. Nov. 2015



Skin grafts

Indications

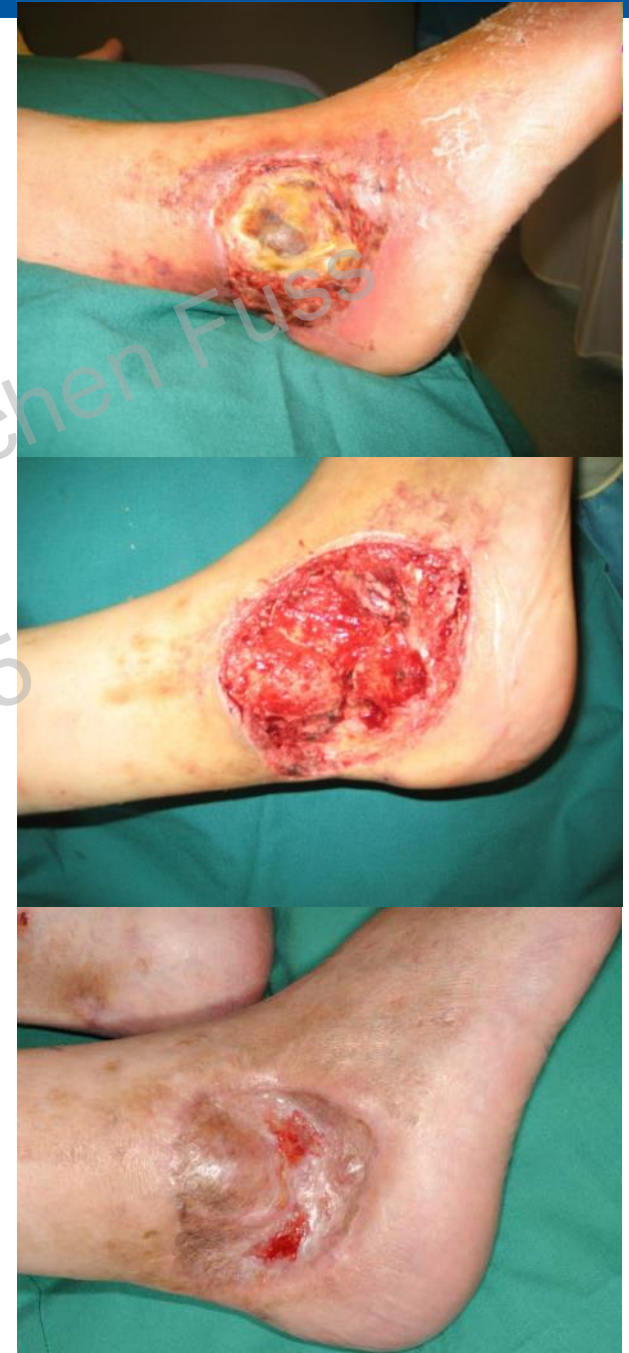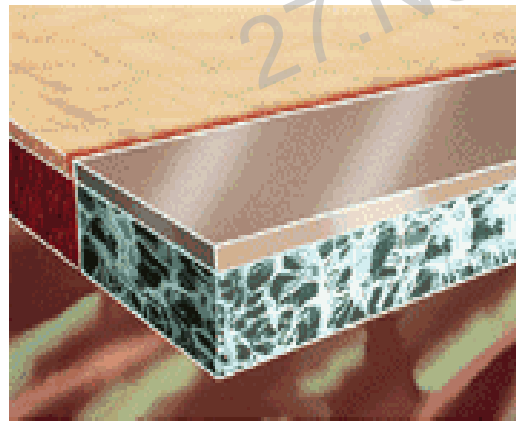
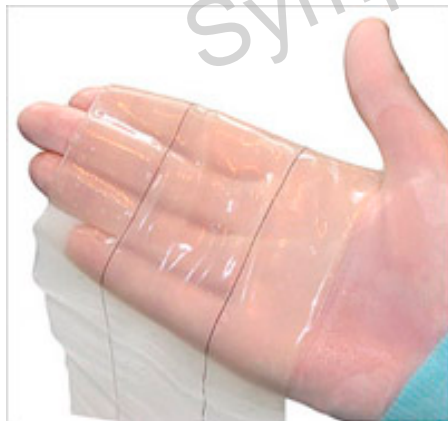- Superficial lesions
- Well vascularized wound bed (conditioning!)
- Not weight-bearing surfaces
- No shear loads
- Higher recurrence compared to flaps (Attinger, 2006)



Dermis equivalents

Indications

- Exposed bone or tendons
- Not weight bearing surfaces
- Low demand patients
- Easy, but multistage
- Expensive



Local flaps

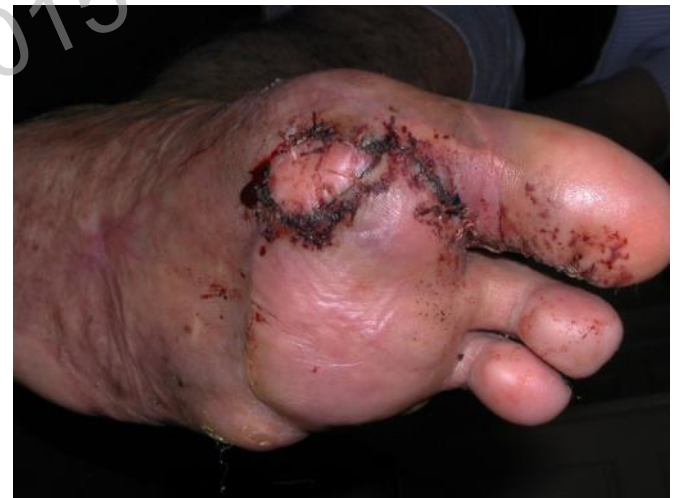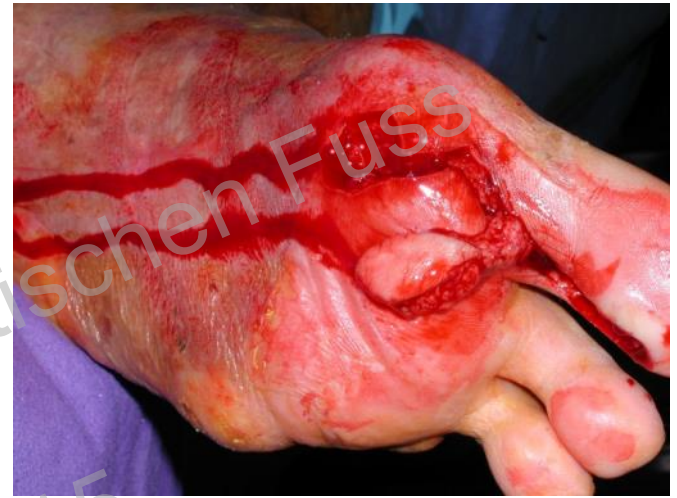Island flaps (skin w/wo fascia)

Intrinsic muscle flaps

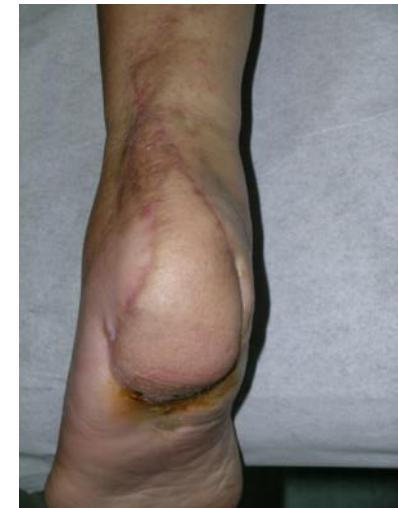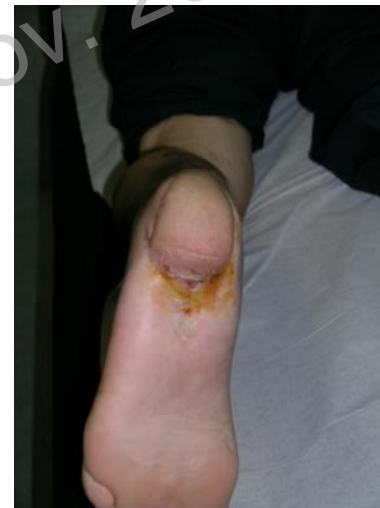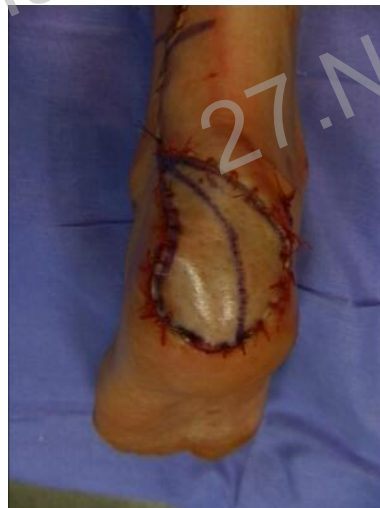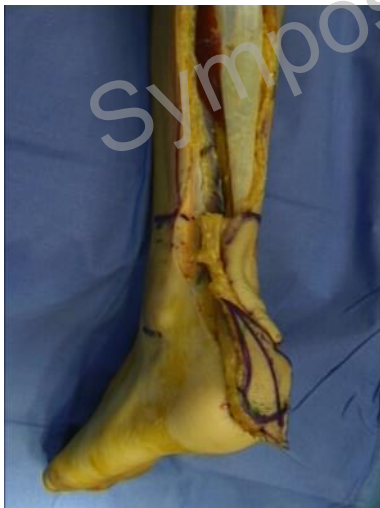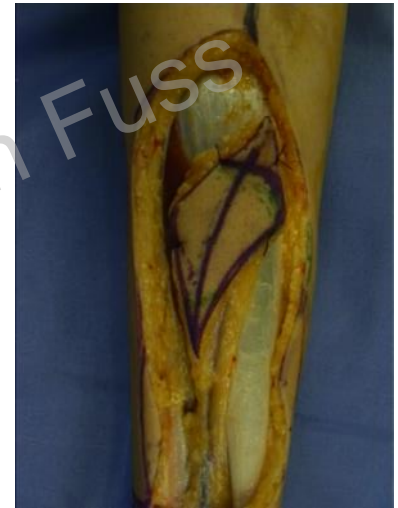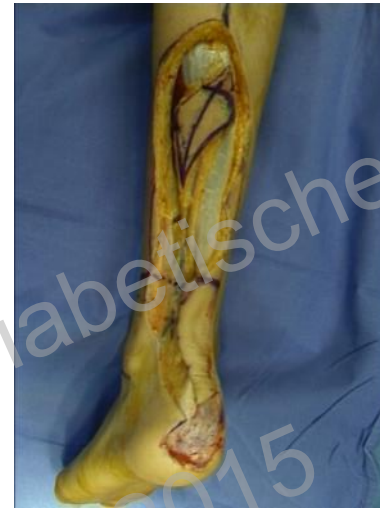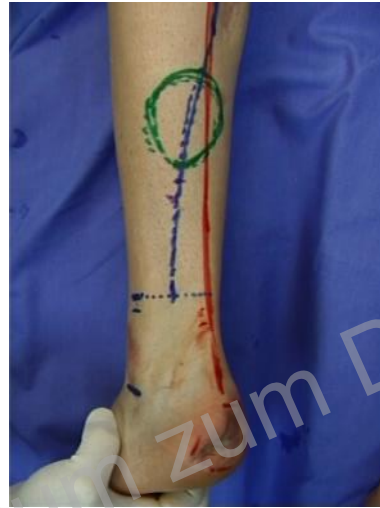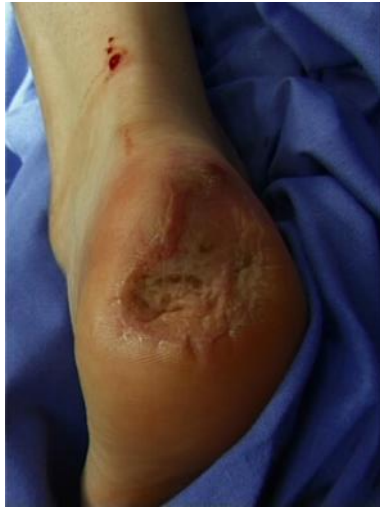Fillet flap

Indications

Small to medium defects



Local flaps: suralis flap



Free flaps

Distal or large loss of substance

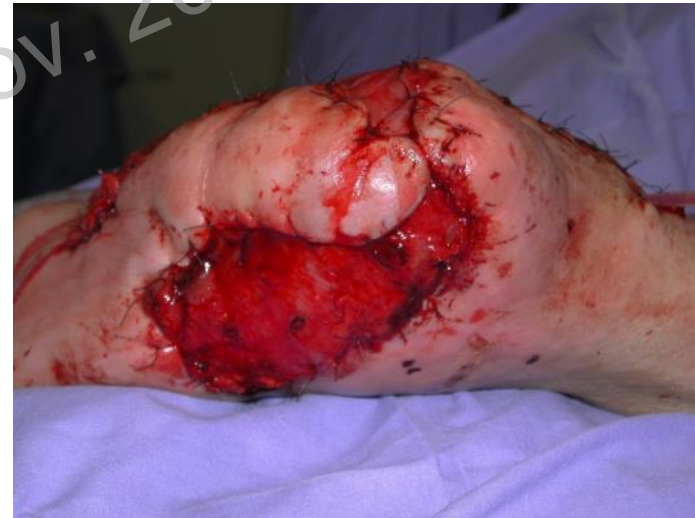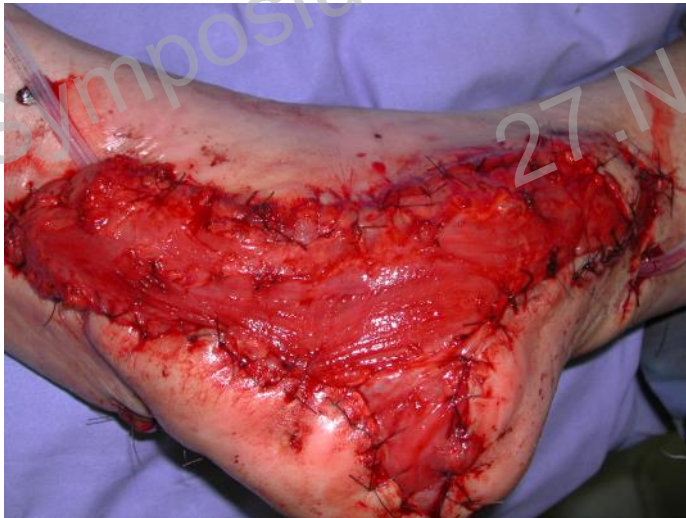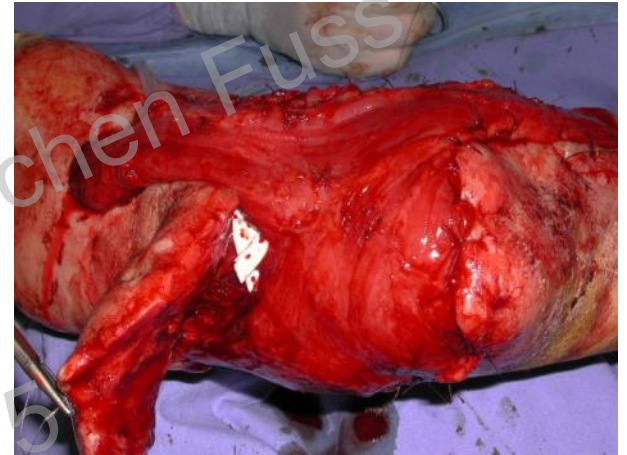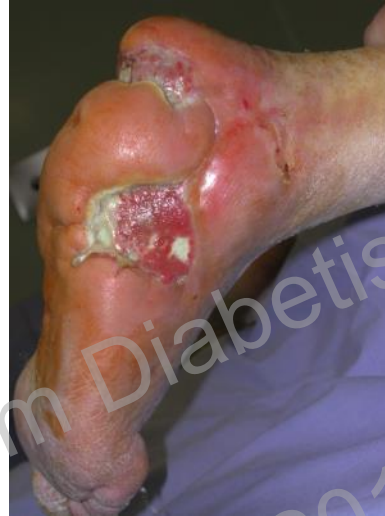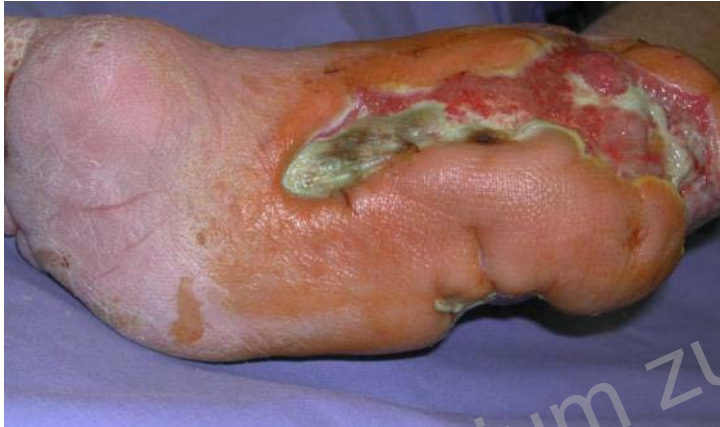Weight bearing surface of the foot

Walking patient

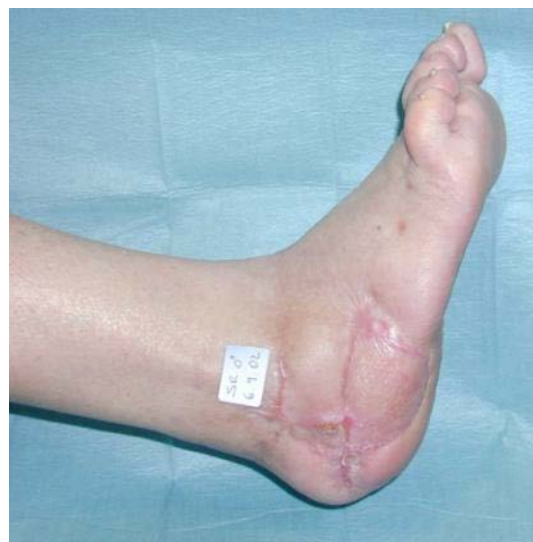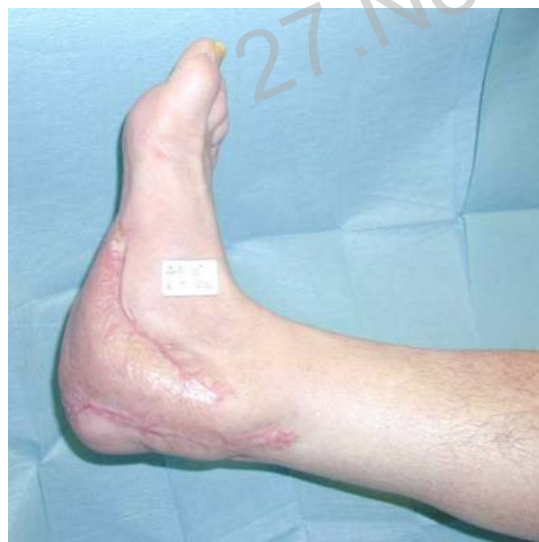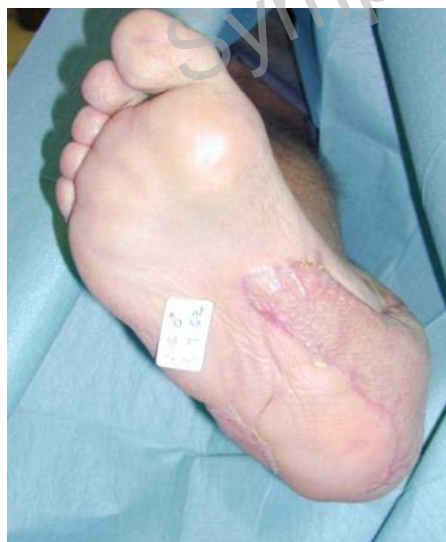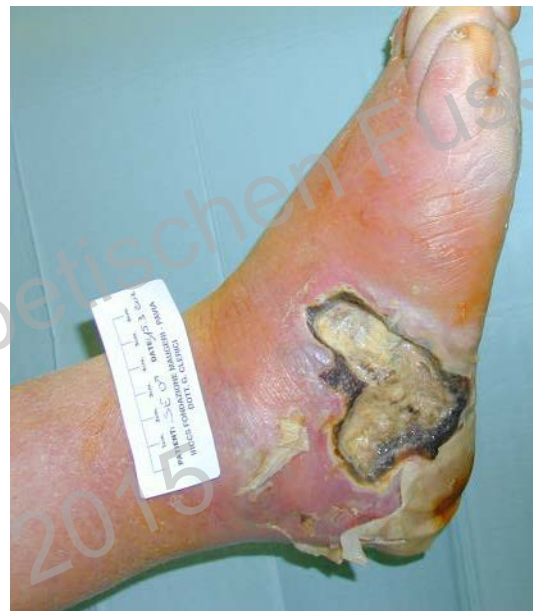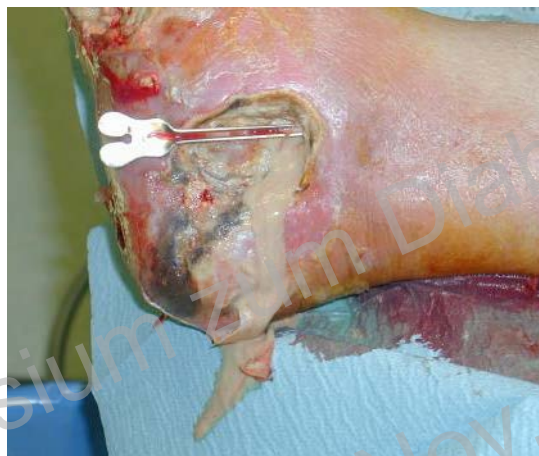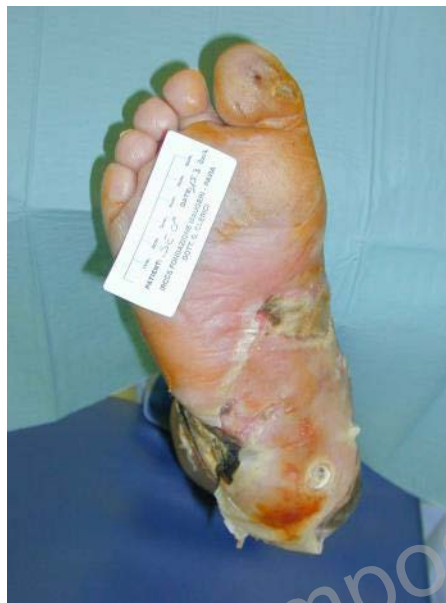Controlateral amputation

Strong drive to preserve the limb (informed consent!!!)

Free flaps: latissimus dorsi



Free flaps: latissimus dorsi



Take home message

- Debridement
- Assess infection
- Vascular treatment
- Stabilization of general conditions
- Wound treatment

Take home message: wound coverage

	Revascularize	Donor site morbidity	Size	Long term stability	Costs
Skin graft	no	low	-	low	low
Dermis equivalent	no	low	-	low	high
Local flaps	Yes/no	medium	small	good	medium
Free flaps	yes	high	large	best	high

Take home message: free flaps

Eur J Vasc Endovasc Surg (2011) 41, 391–399



REVIEW

A Systematic Review of Free Tissue Transfer in the Management of Non-traumatic Lower Extremity Wounds in Patients with Diabetes

E.J. Fitzgerald O'Connor^a, M. Vesely^b, P.J. Holt^a, K.G. Jones^a, M.M. Thompson^a, R.J. Hinchliffe^{a,*}

Table 4 Baseline pre-operative workup.

1. Adequate debridement of necrotic and infected tissue
2. Microbiological assessment and appropriate antibiotic regimen
3. Lower limb angiography CT angiography for flap donor site planning
4. Appropriate anaesthetic assessment of cardiovascular and respiratory systems

Table 5 Suggested inclusion criteria.

1. Lower limb defect which has not displayed any signs of granulation or healing despite adequate debridement of necrotic tissue and conservative treatment
2. No significant renal function impairment
3. No significant systemic illness likely to be exacerbated by multiple operations and prolonged rehabilitation
4. Previously ambulatory with the aim to restore a functional limb
5. Likely to engage with the significant physiotherapy required for a return to normal living.
6. Peak blood flow velocity of >40 cm/s in recipient artery



Symposium zum Diabetischen Fuss
27. Nov. 2015

Thank You for
Your attention

maurizio.calcagni@usz.ch

Adipose – derived Stem Cells (ASC)

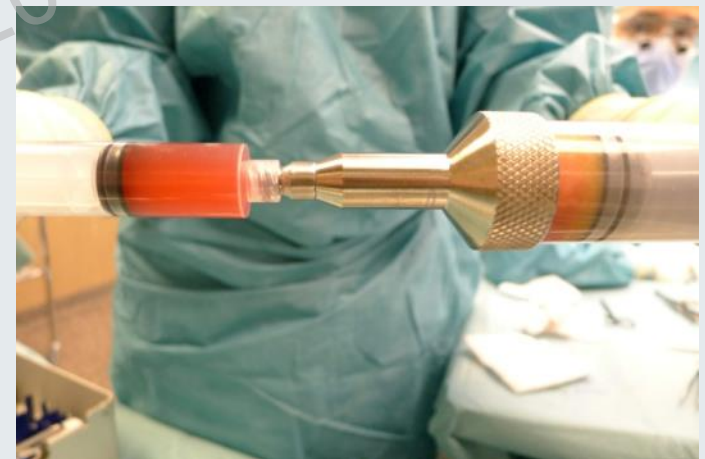
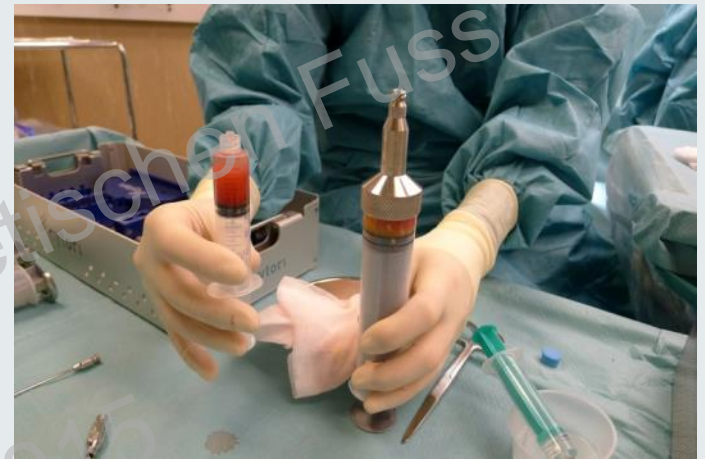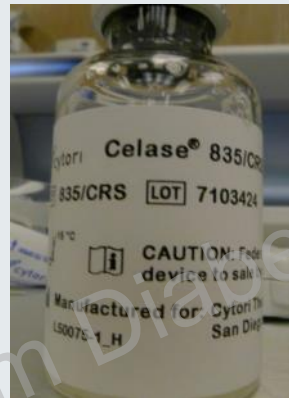
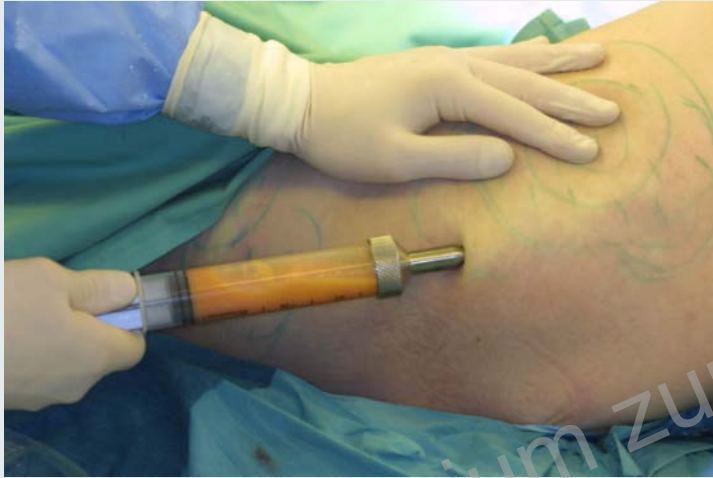- First description in 2001 (Zuk P., Tiss Eng 2001)
- 10^6 ASC can be isolate from 100cc of lipoaspirate
- Secrete angiogenetic and antiapoptotic factors
- Promote neovascularisation
- Improve skin quality (collagene induction)
- Main indications in plastic surgery
 - Contracted or adherent scars
 - Contour defects
 - Chronic wounds
- Other indications (erectile disfunctions, anal fistulas, etc.)

Celution (Cytori)

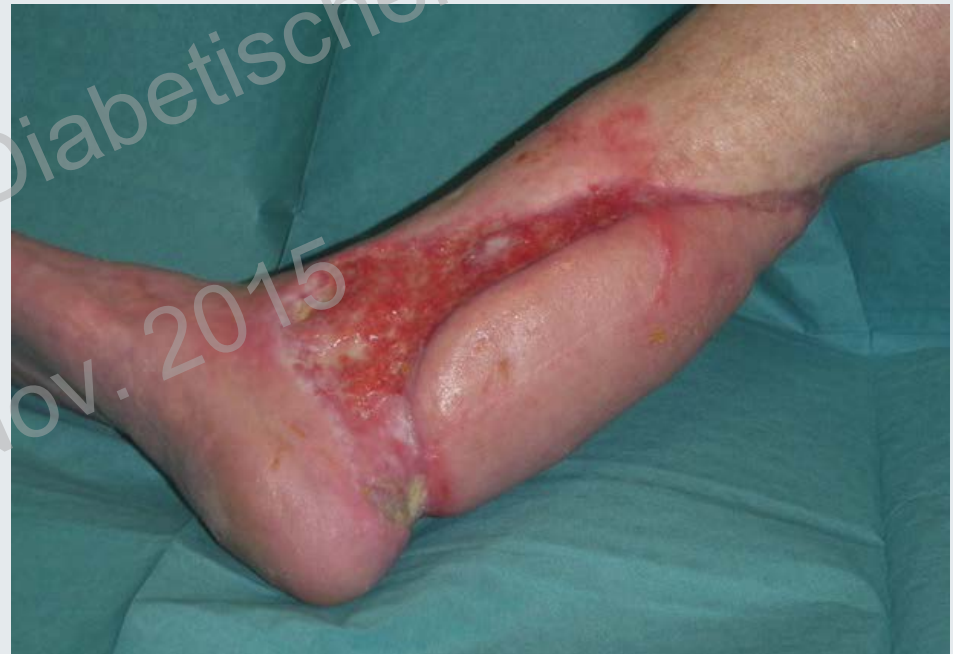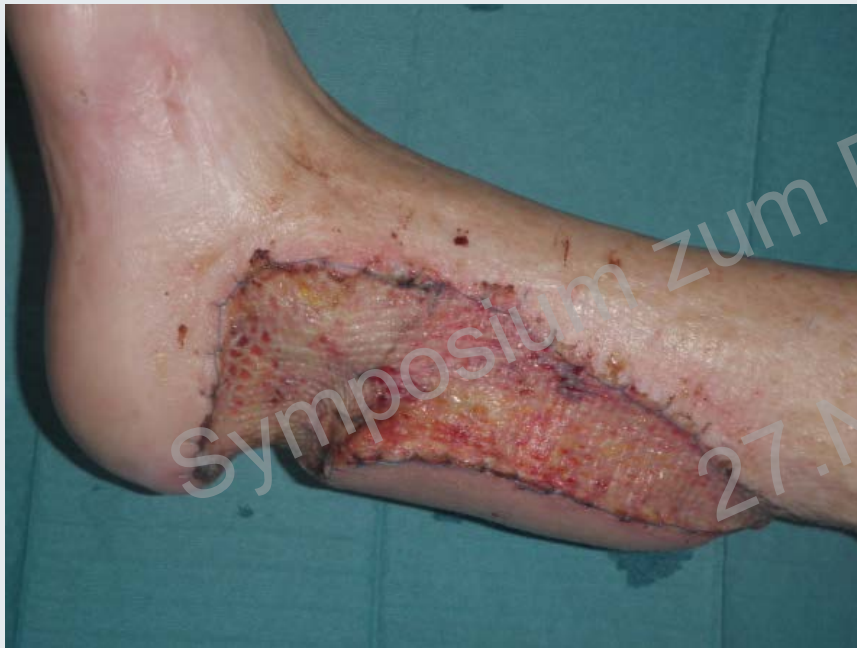- Closed system
- GMP certified
- No transplantation laws



Celution



Celution



Case from Cytori

Peripheral nerve decompression

The Role of Peripheral Nerve Surgery in Diabetic Limb Salvage

Ivica Ducic, M.D., Ph.D.
John M. Felder, III, M.D.
Matthew L. Iorio, M.D.
Washington, D.C.

Plast Reconstr Surg, 2011

- Duple crush phenomenon (systemic “crush”)
- Numbness, tingling, burning pain, muscle weakness/hypotrophy
- No vascular problem
- No open wound, infection