



Der **Balgrist**

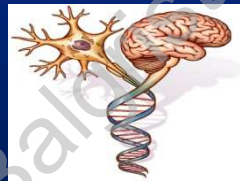


## Case Presentation: Cervical Tumor

**Michael G. Fehlings MD PhD FRCSC FACS FRSC FCAHS**

Professor of Neurosurgery  
Vice Chair Department of Surgery  
Halbert Chair in Neural Repair and Regeneration  
Co-Director Spine Program  
University of Toronto

Fellow Royal Society  
Chair AOSpine SCI Knowledge Forum



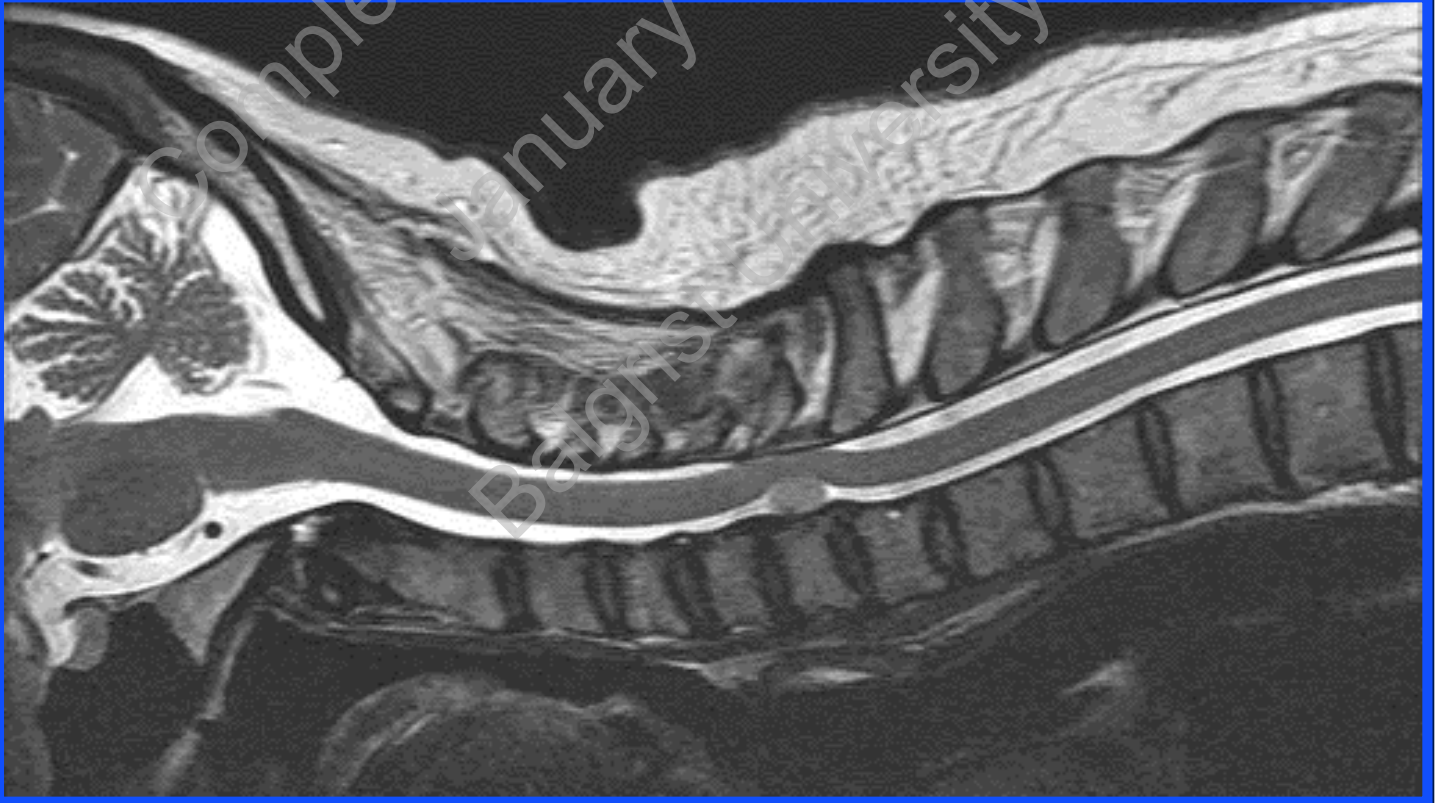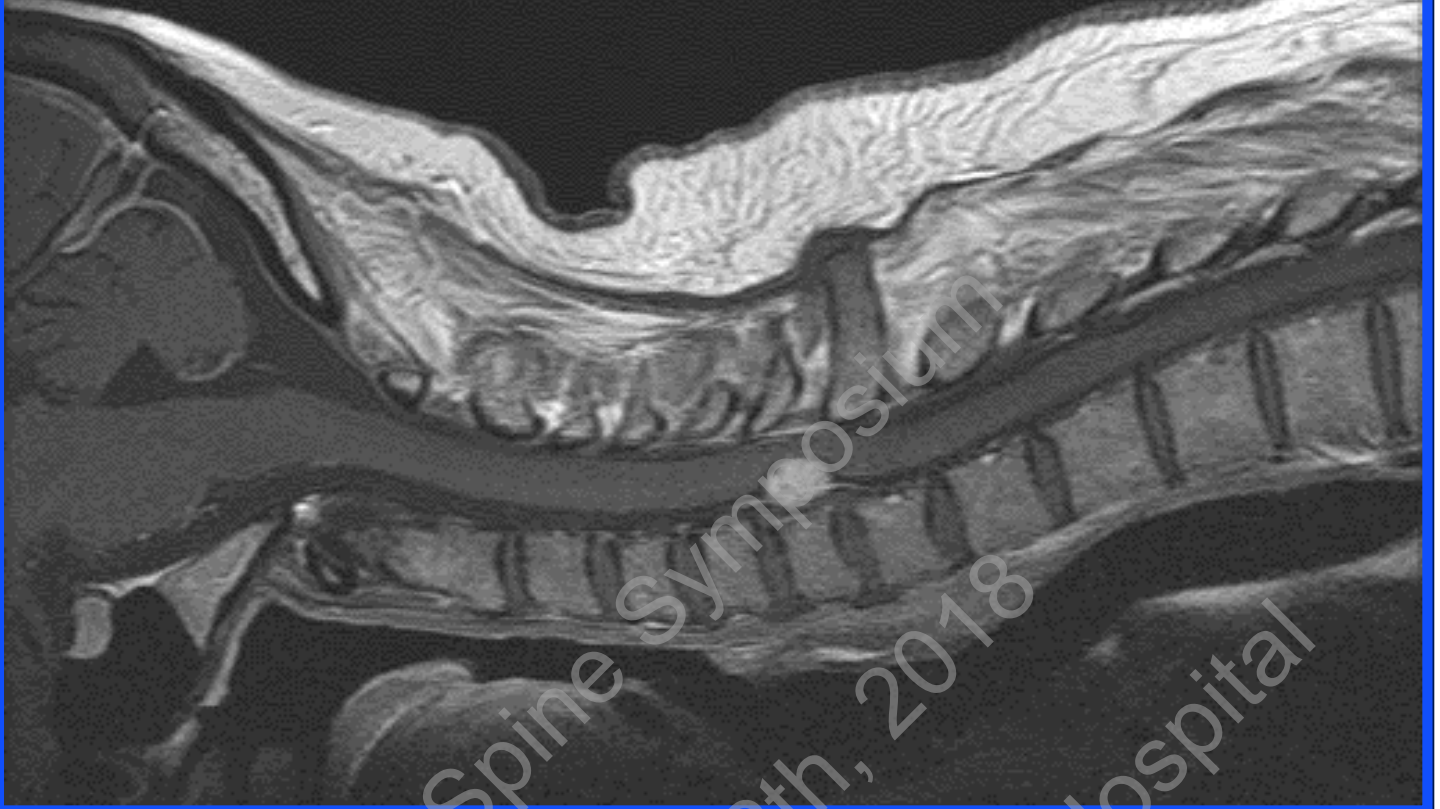Neurosurgery



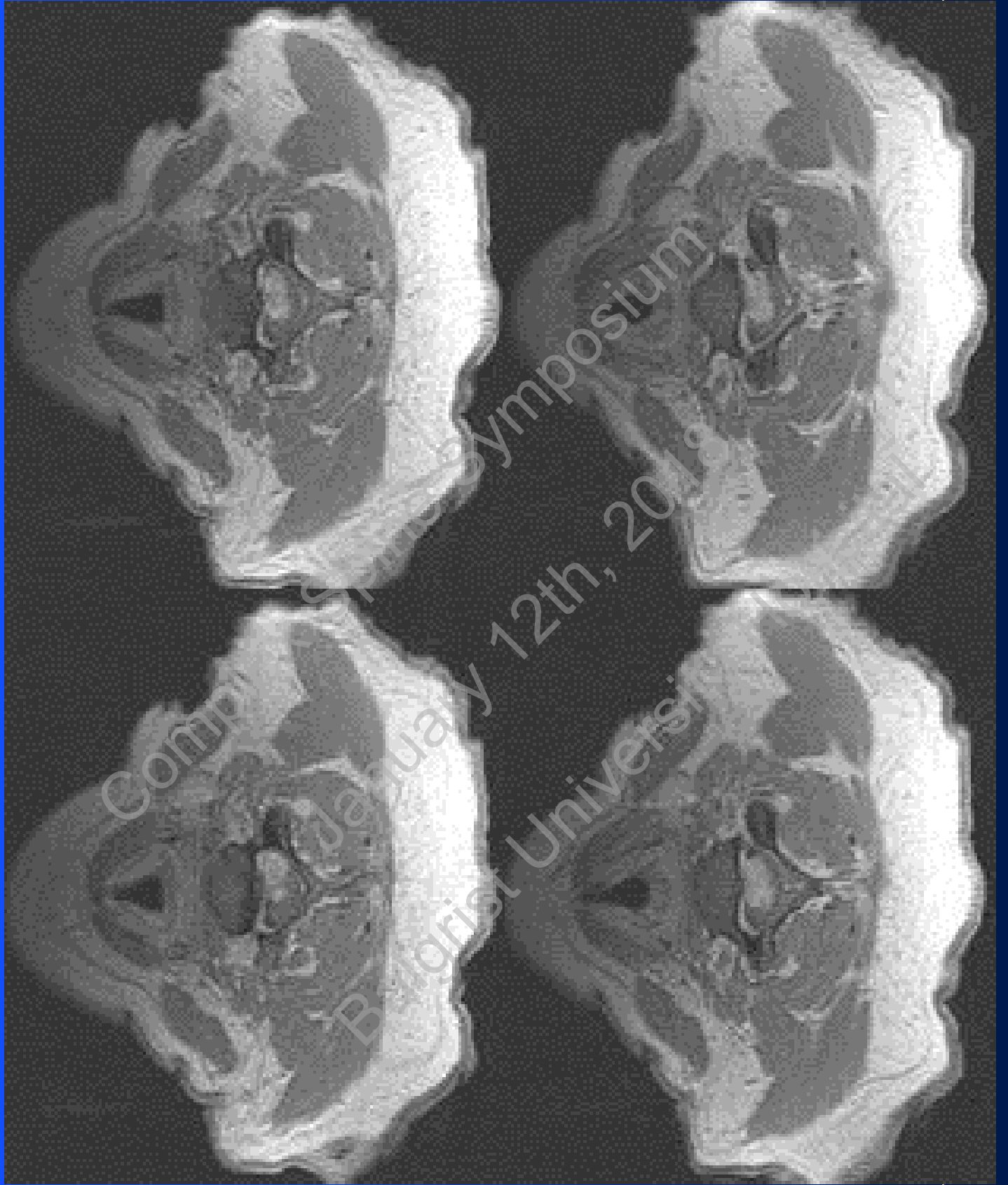
[www.uhn.on.ca/programs/spine](http://www.uhn.on.ca/programs/spine)

# Case Presentation

- 53 year-old female
- Clinical picture:
  - Incomplete tetraparesis
  - Significant right arm weakness
  - Hyperreflexia
  - Gait disturbance with upgoing toes



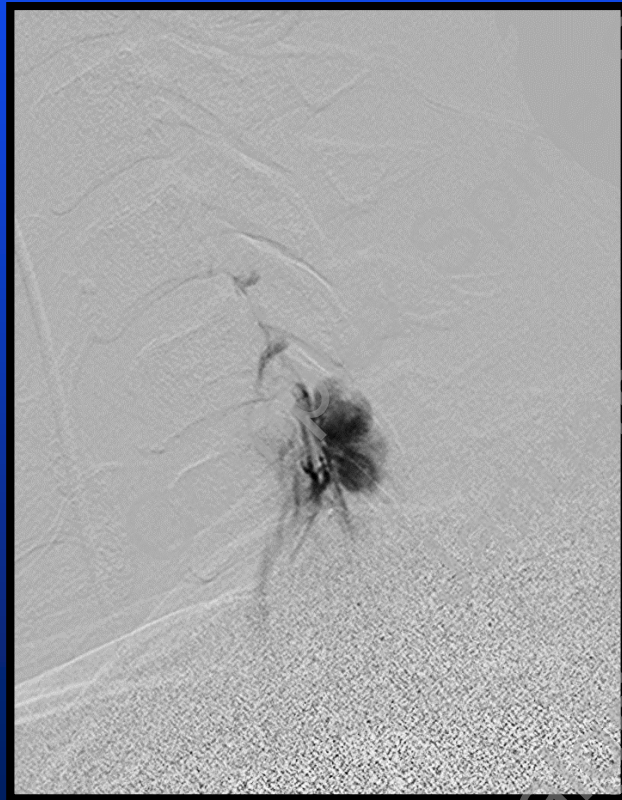
Complex Spine Symposium  
January 12th, 2018  
Baylor University Hospital



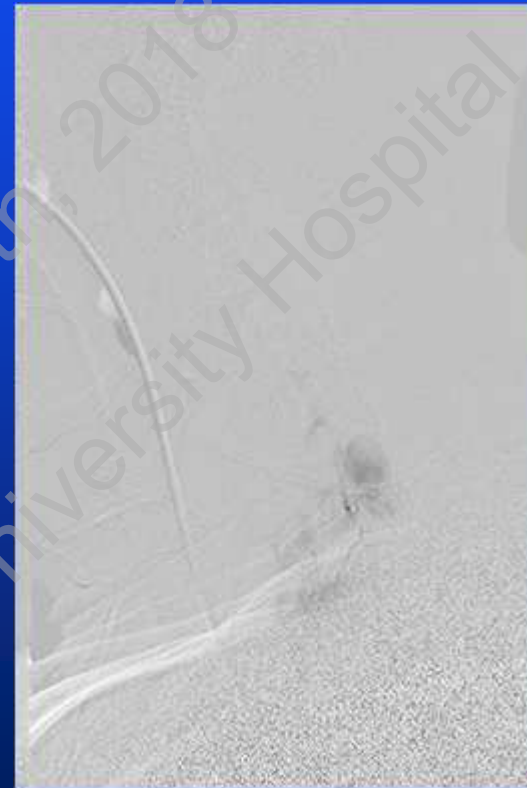
# Differential Diagnosis? Management?

Complex Spine Symposium  
January 12th, 2018  
Balgrist University Hospital

# Selective tumor embolization

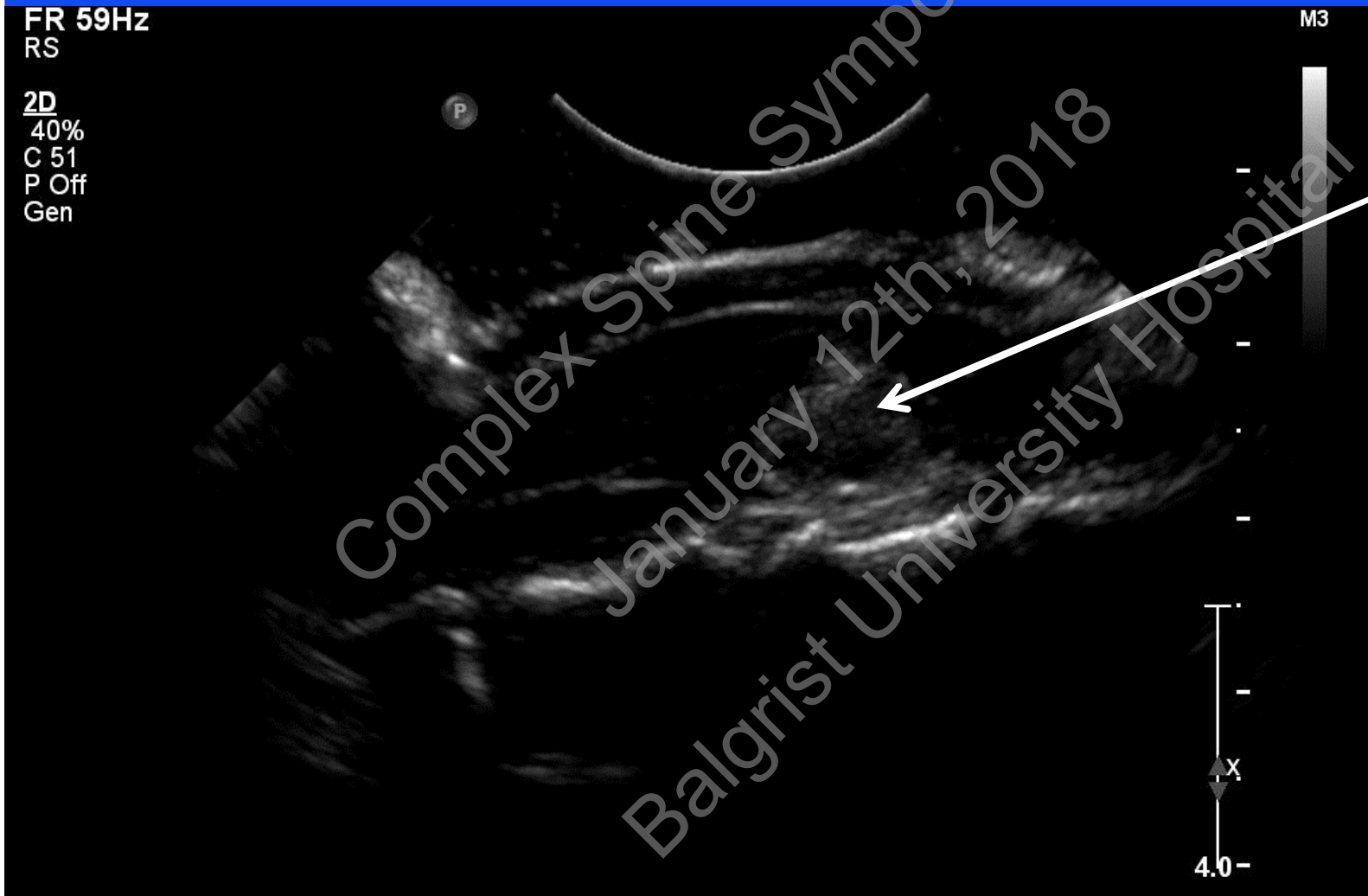

**Pre**

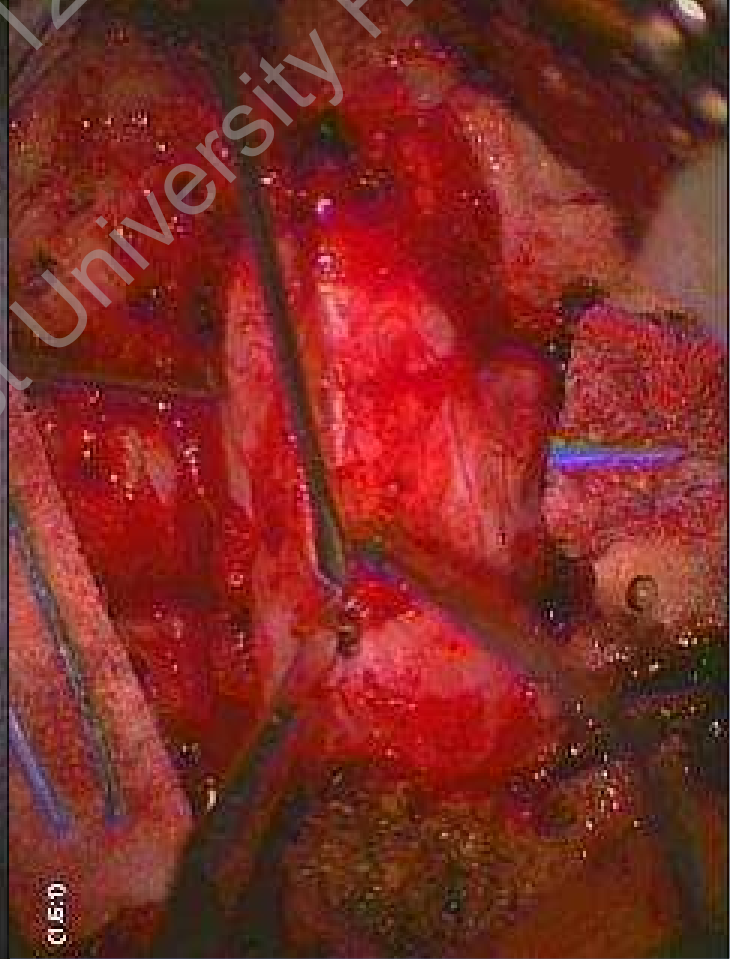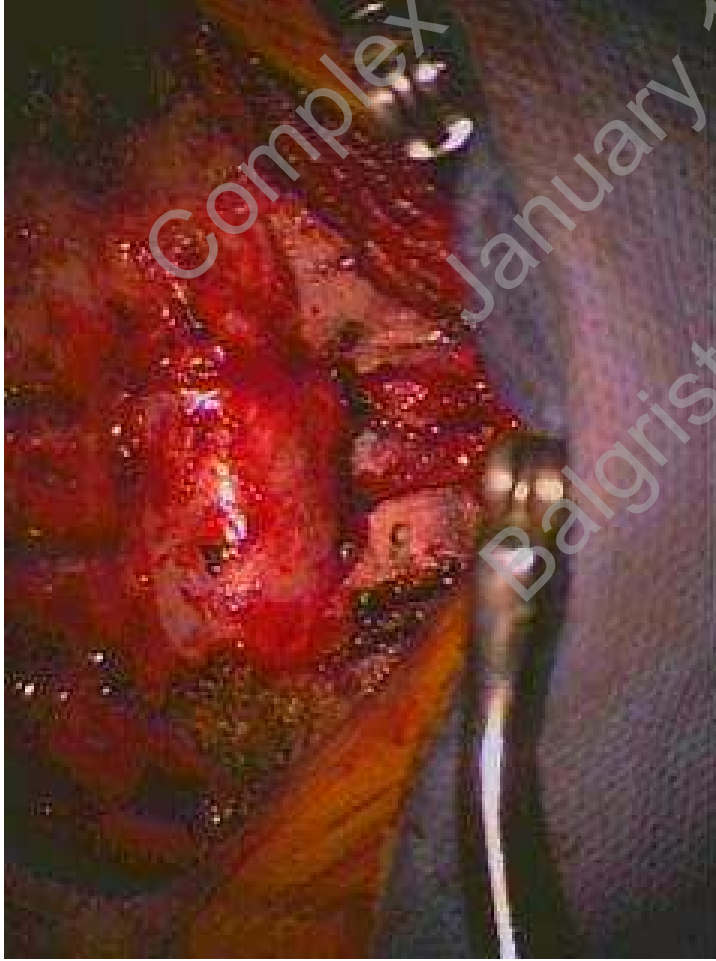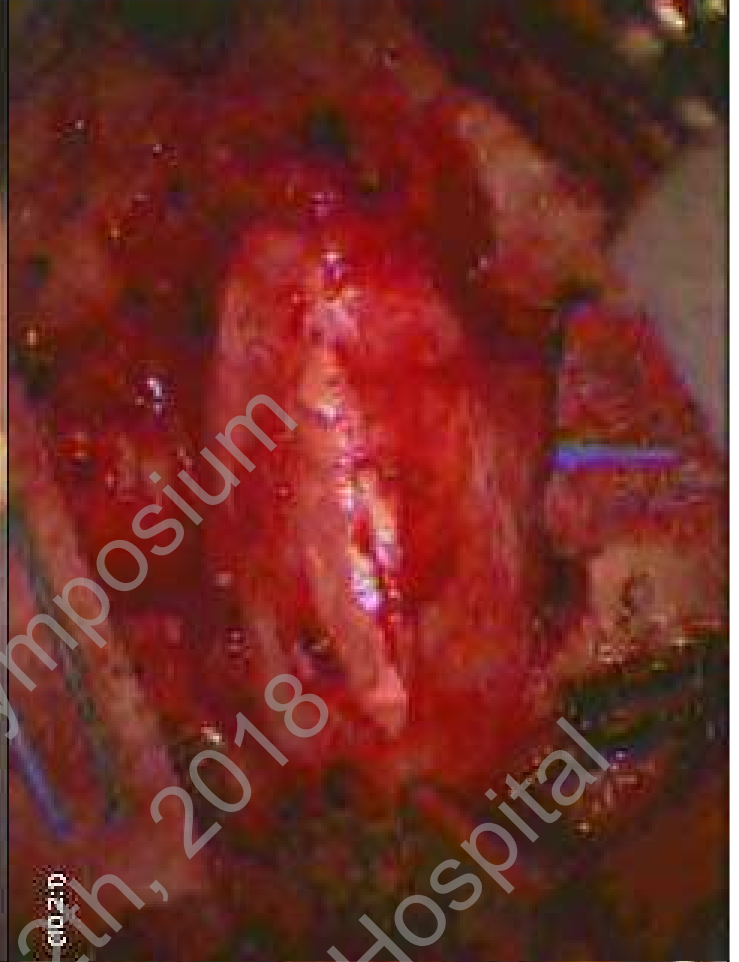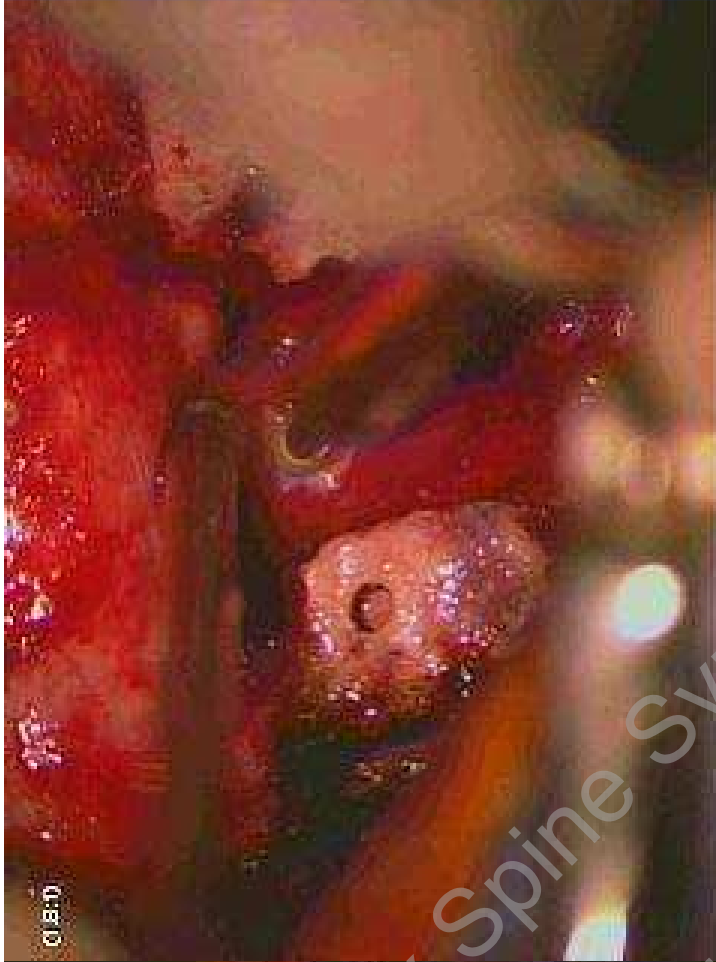


**Post**

# High resolution Ultrasound

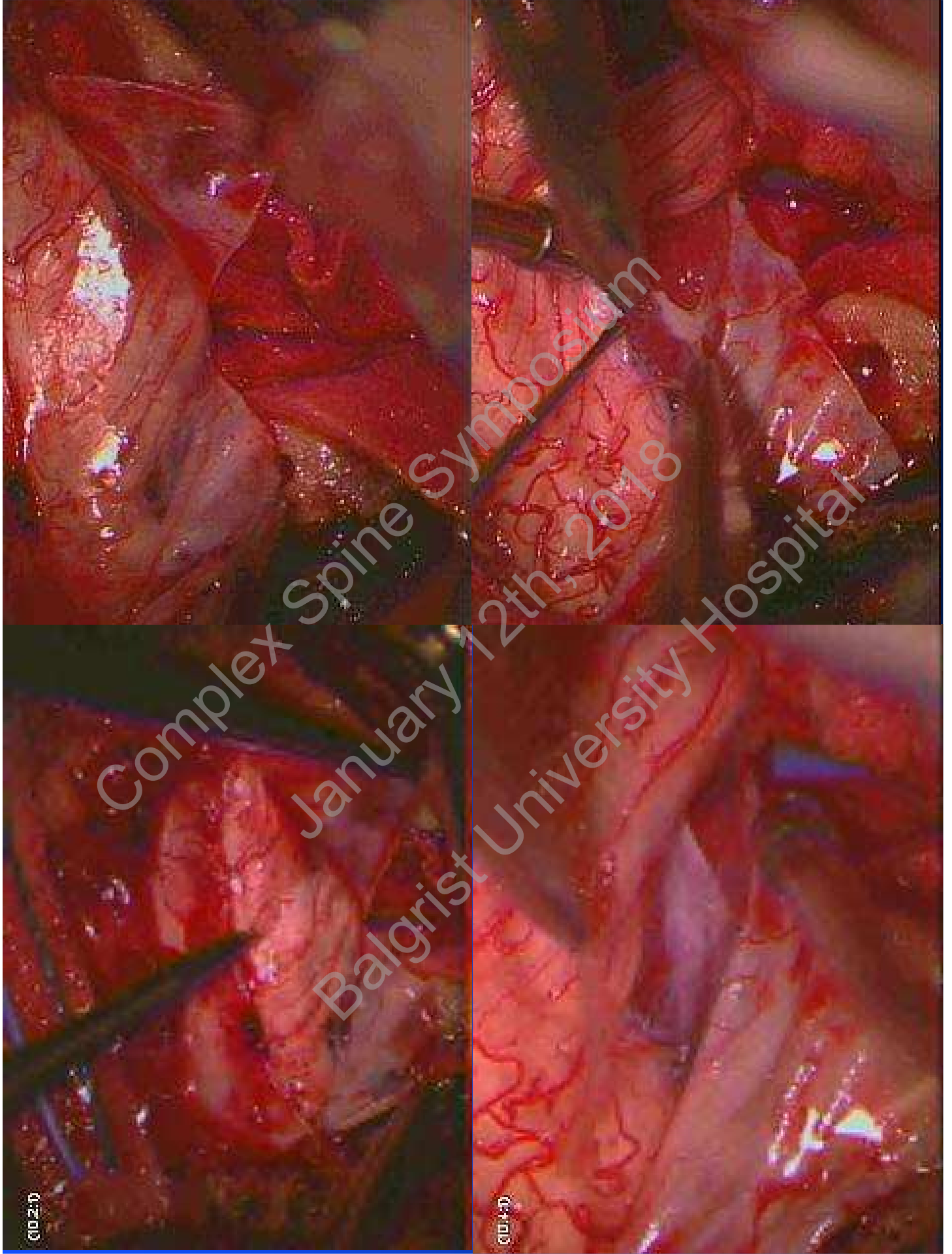


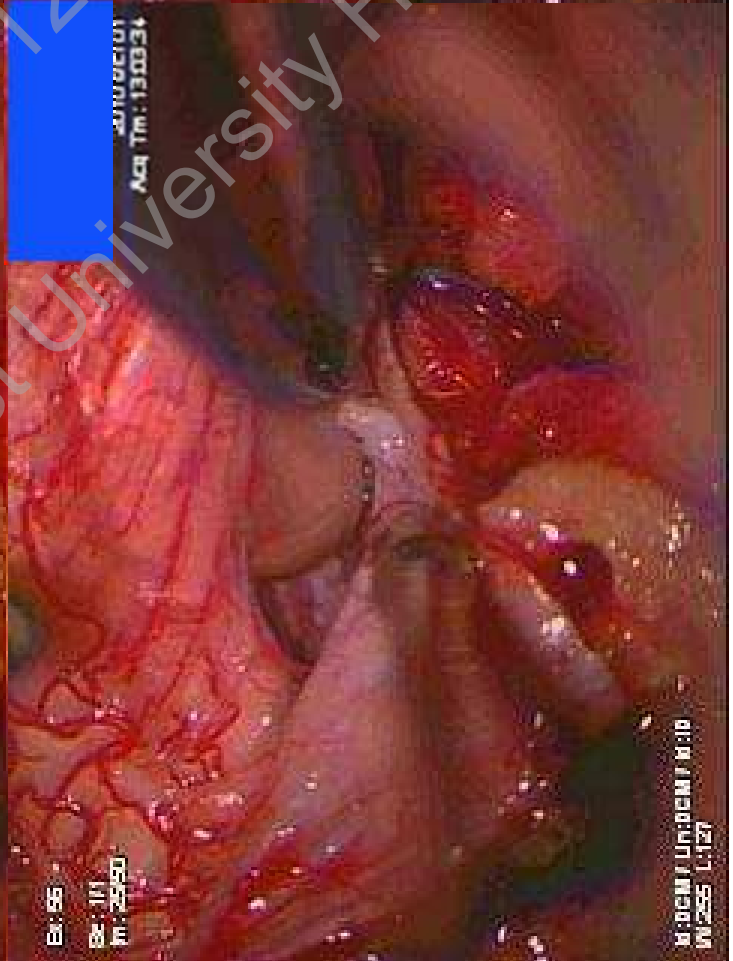
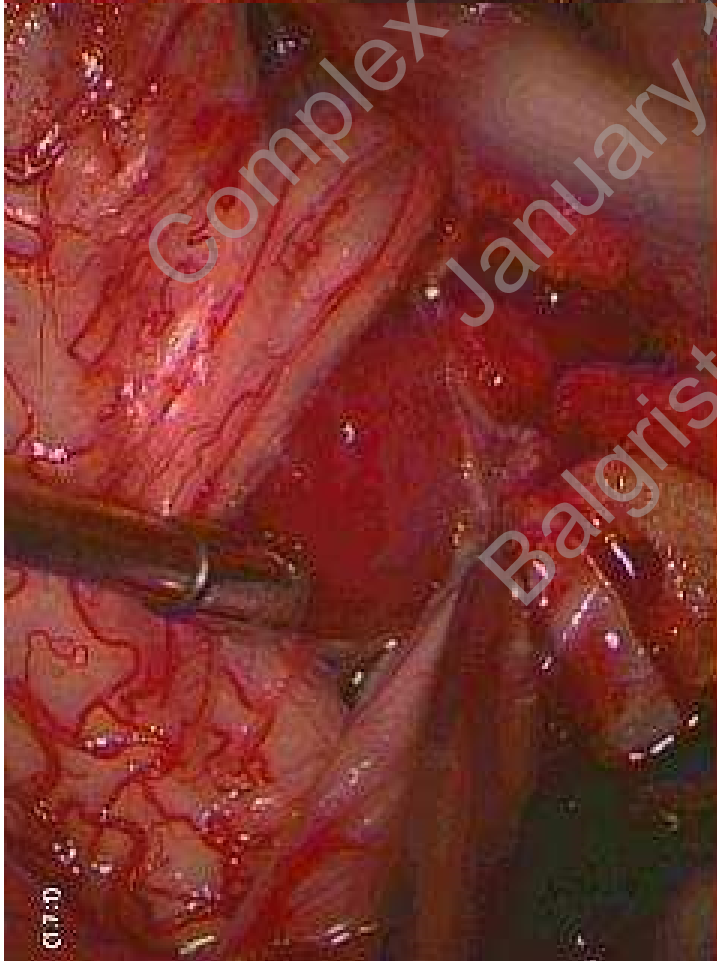
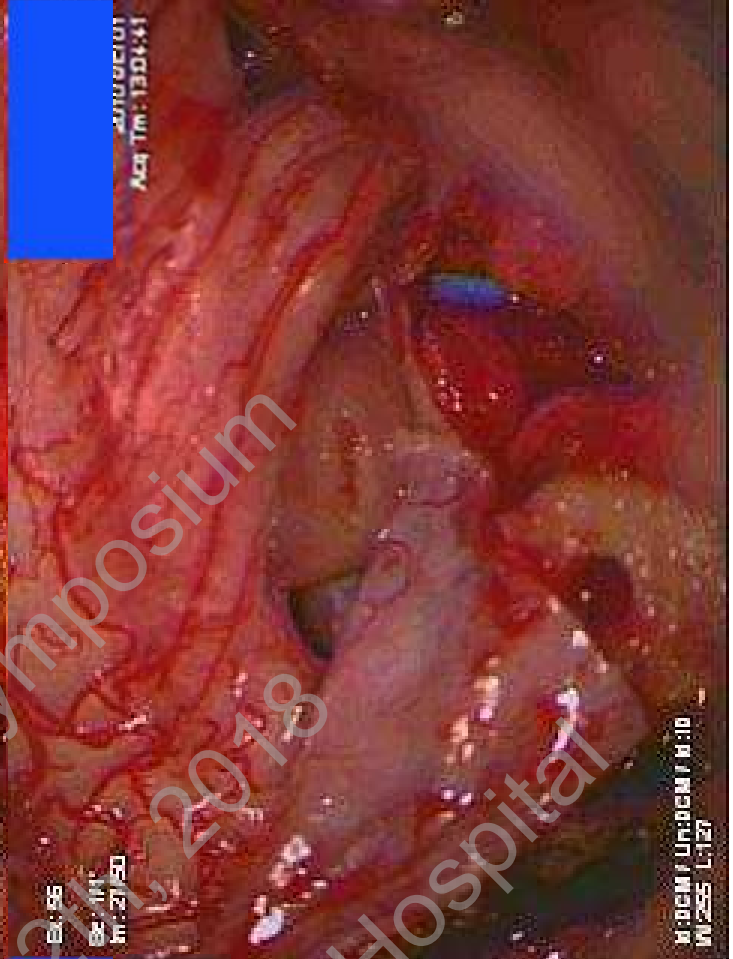
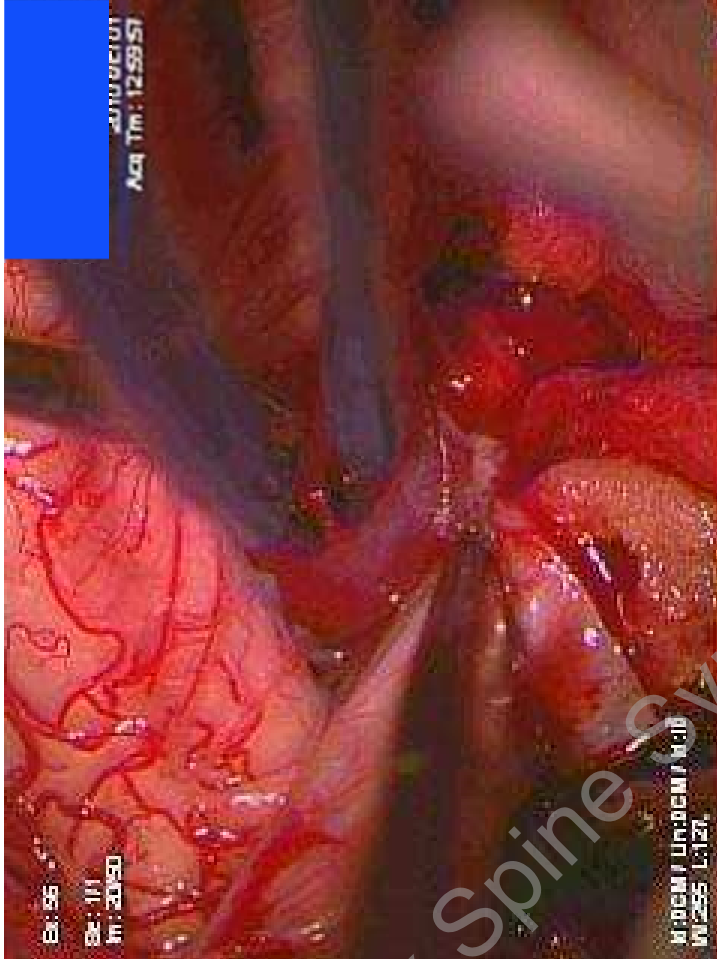
Tumor



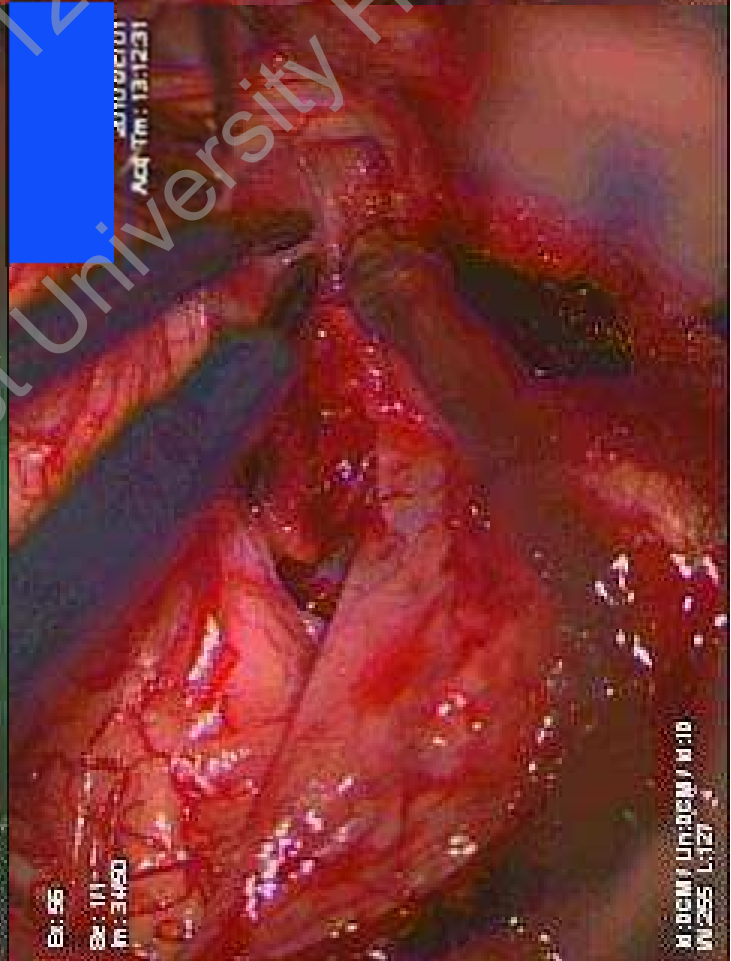
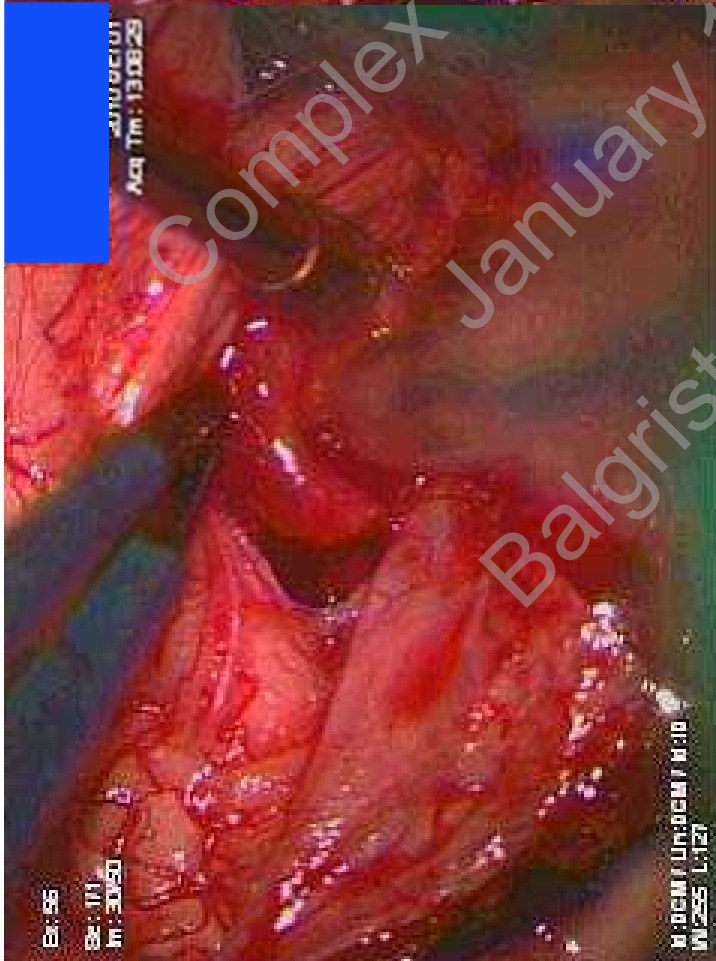
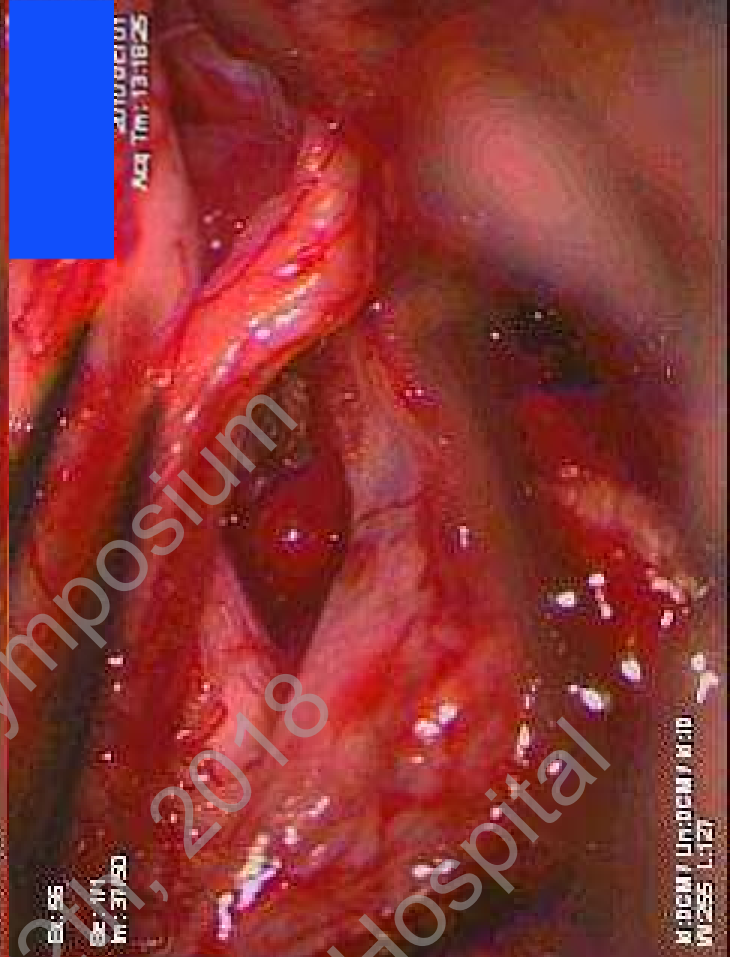
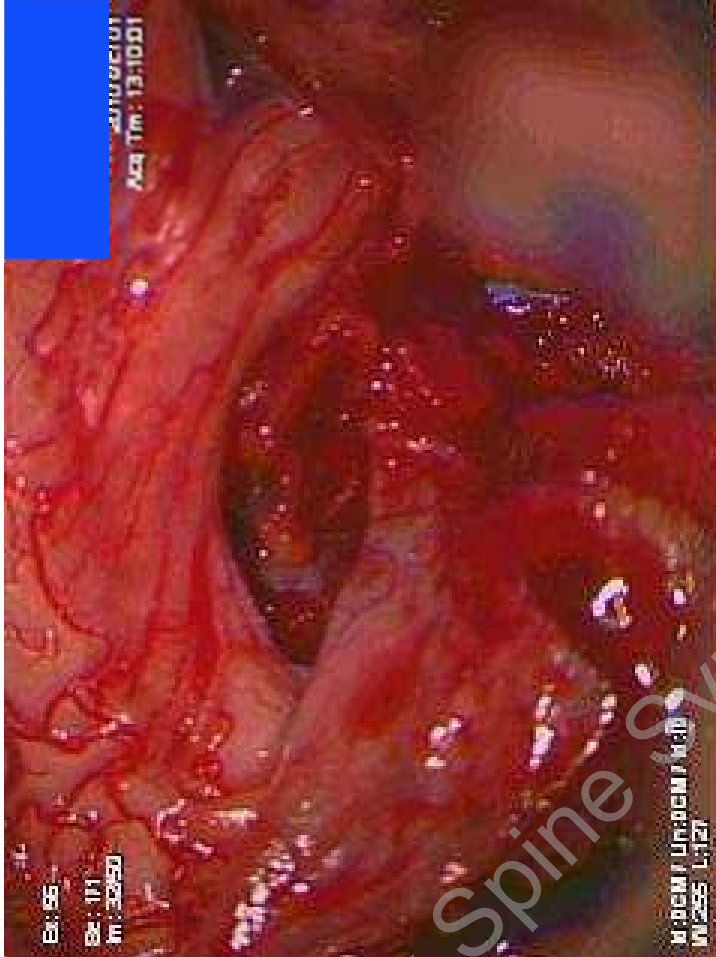
Complex Spine Symposium  
January 12th, 2018  
Balgrist University Hospital



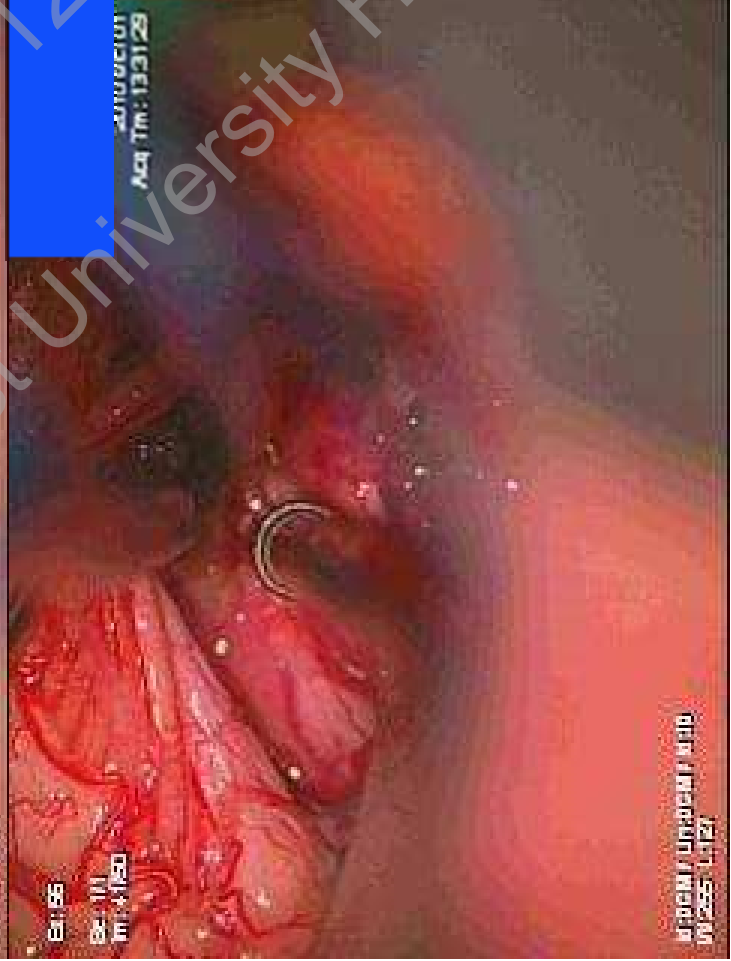
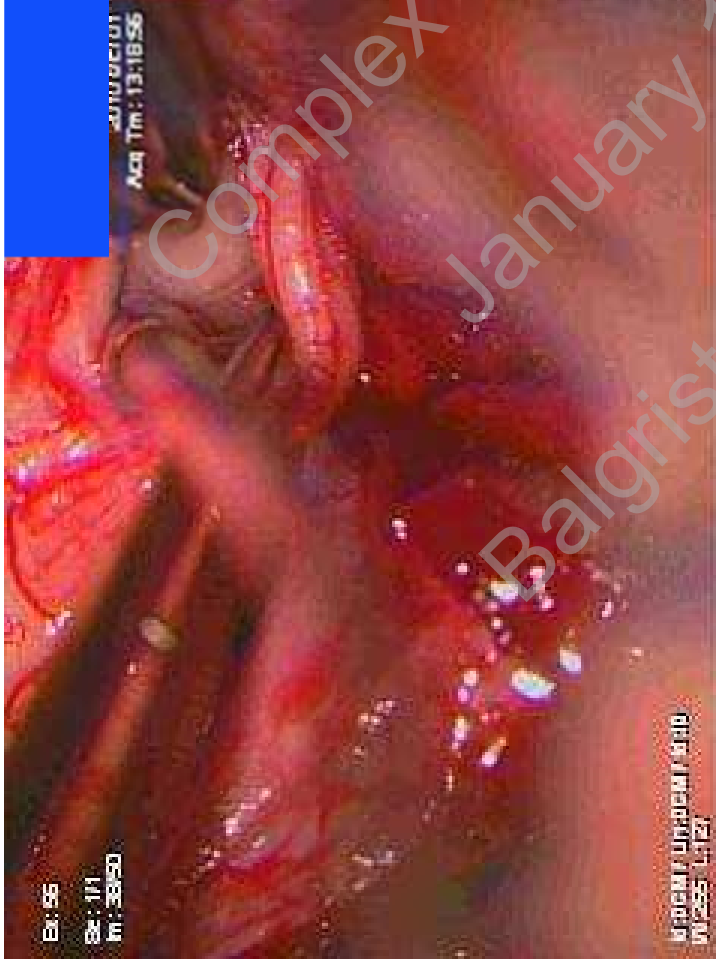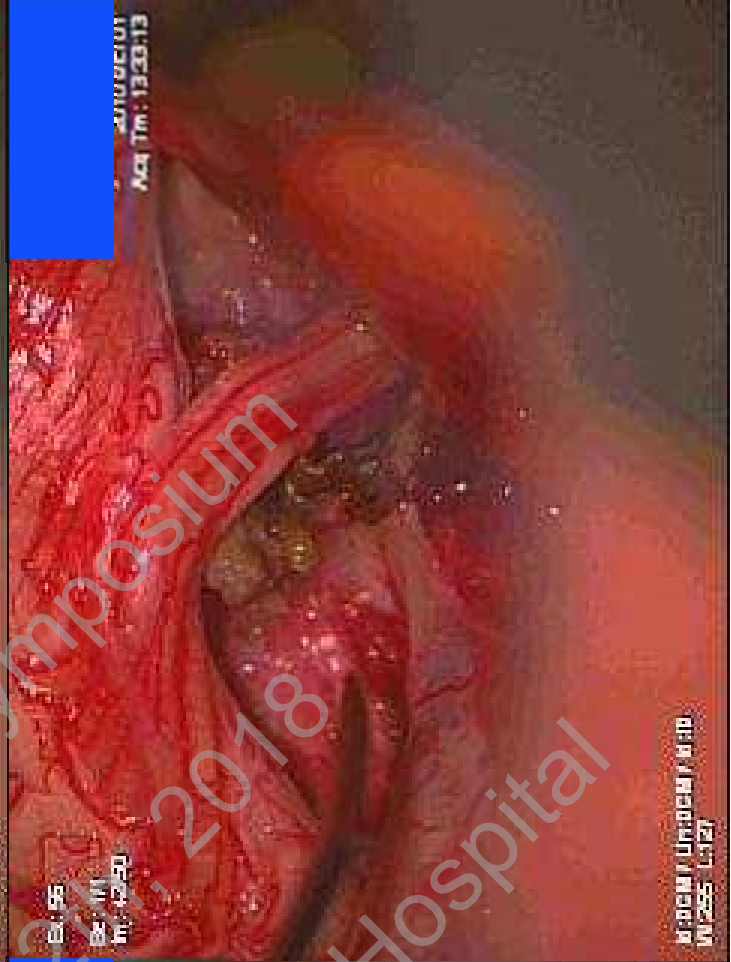
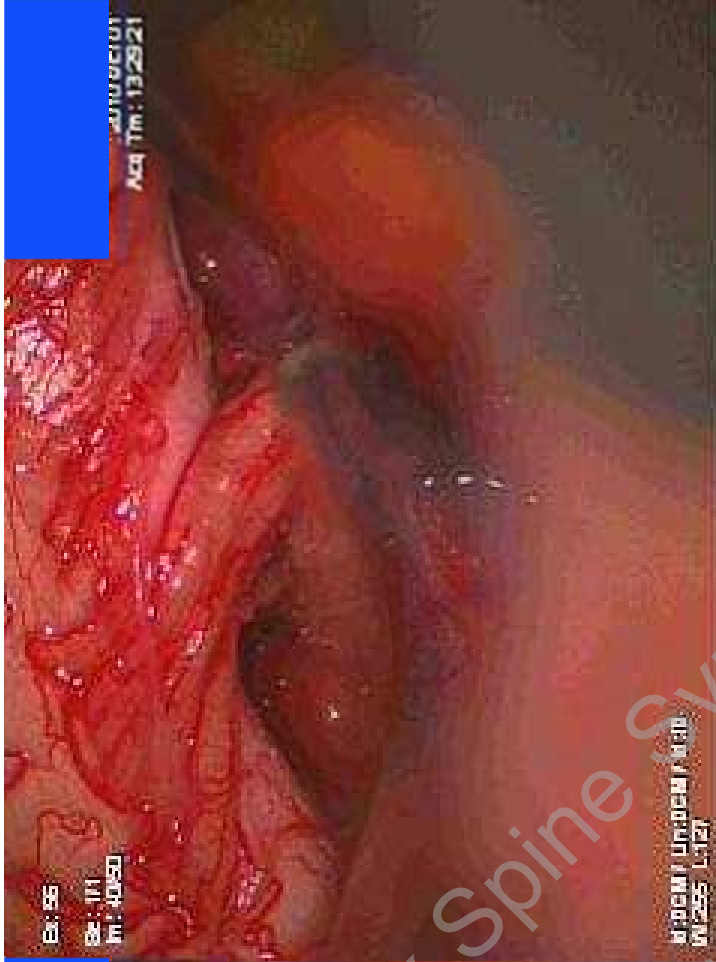




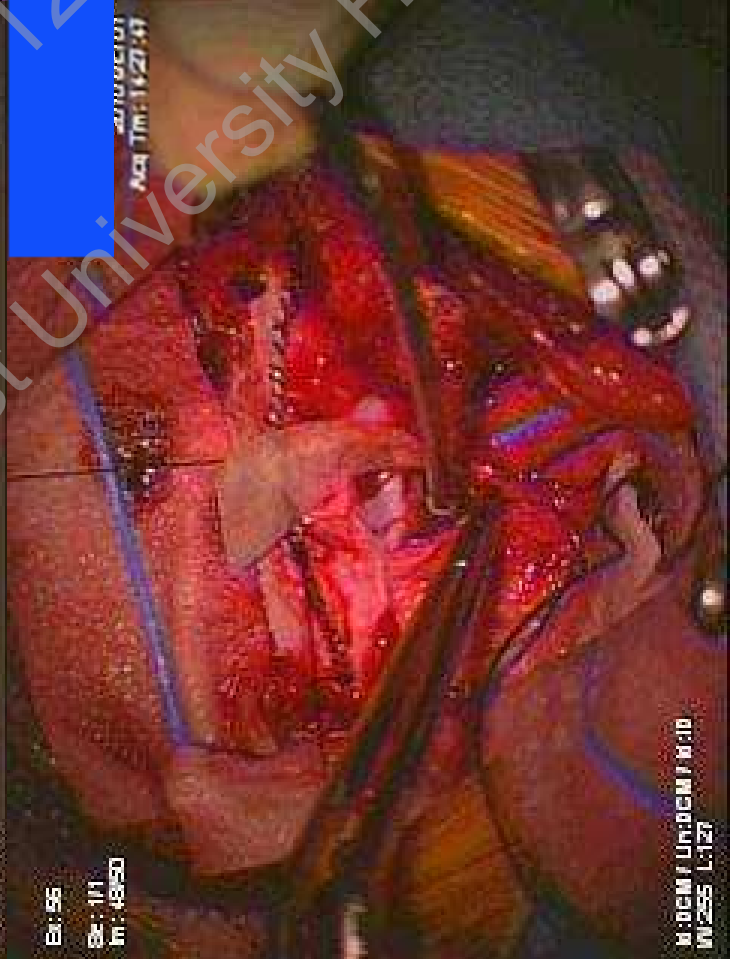
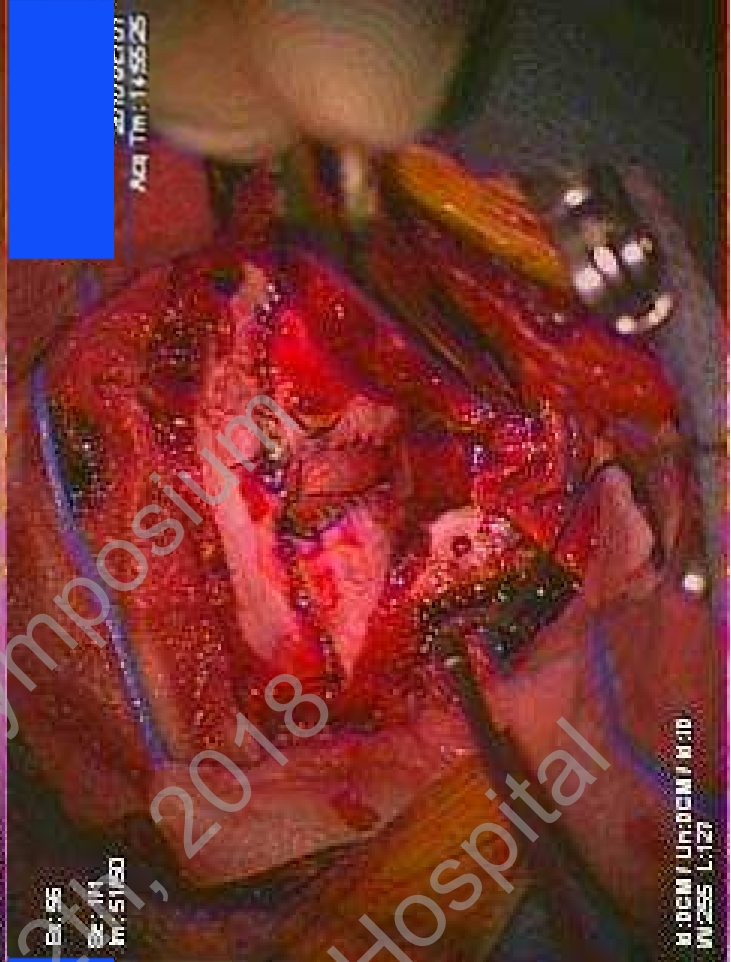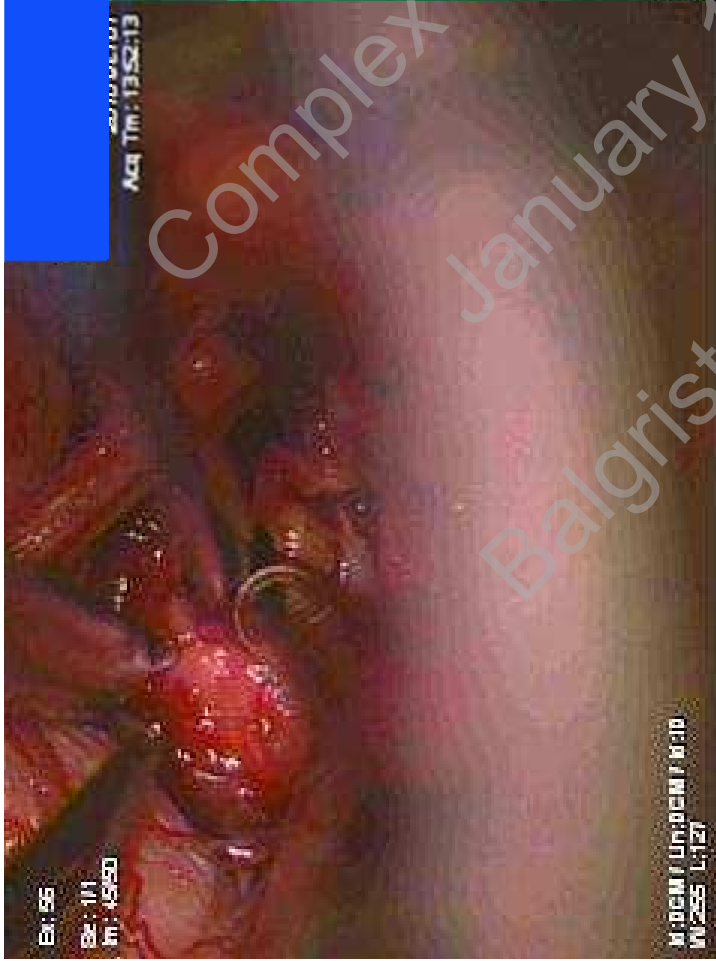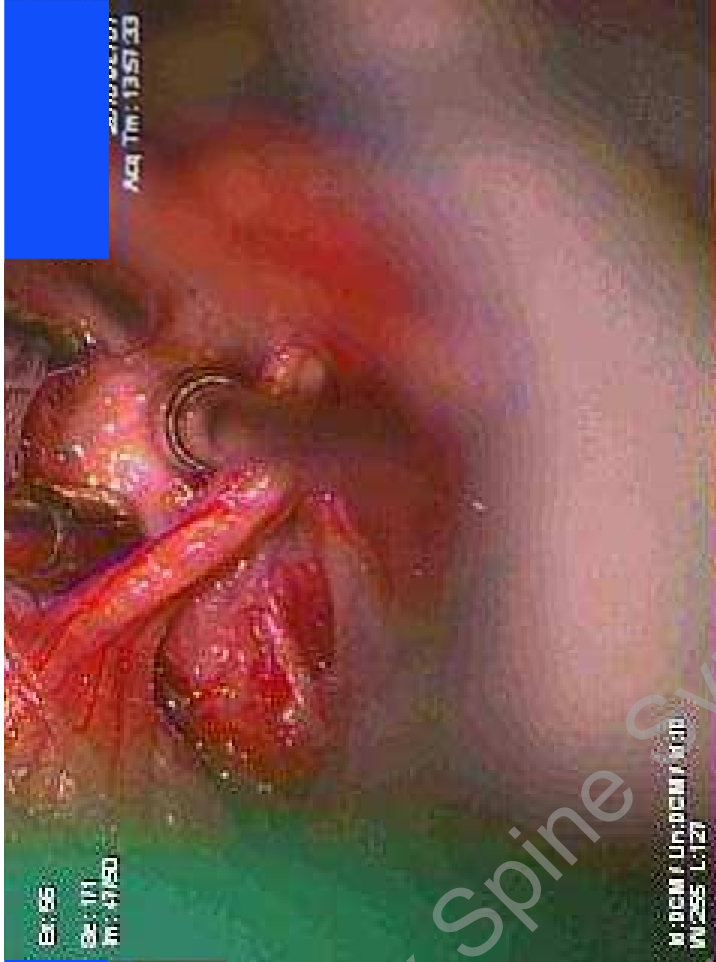
Complex Spine Symposium  
January 21, 2018  
Balgrist University Hospital



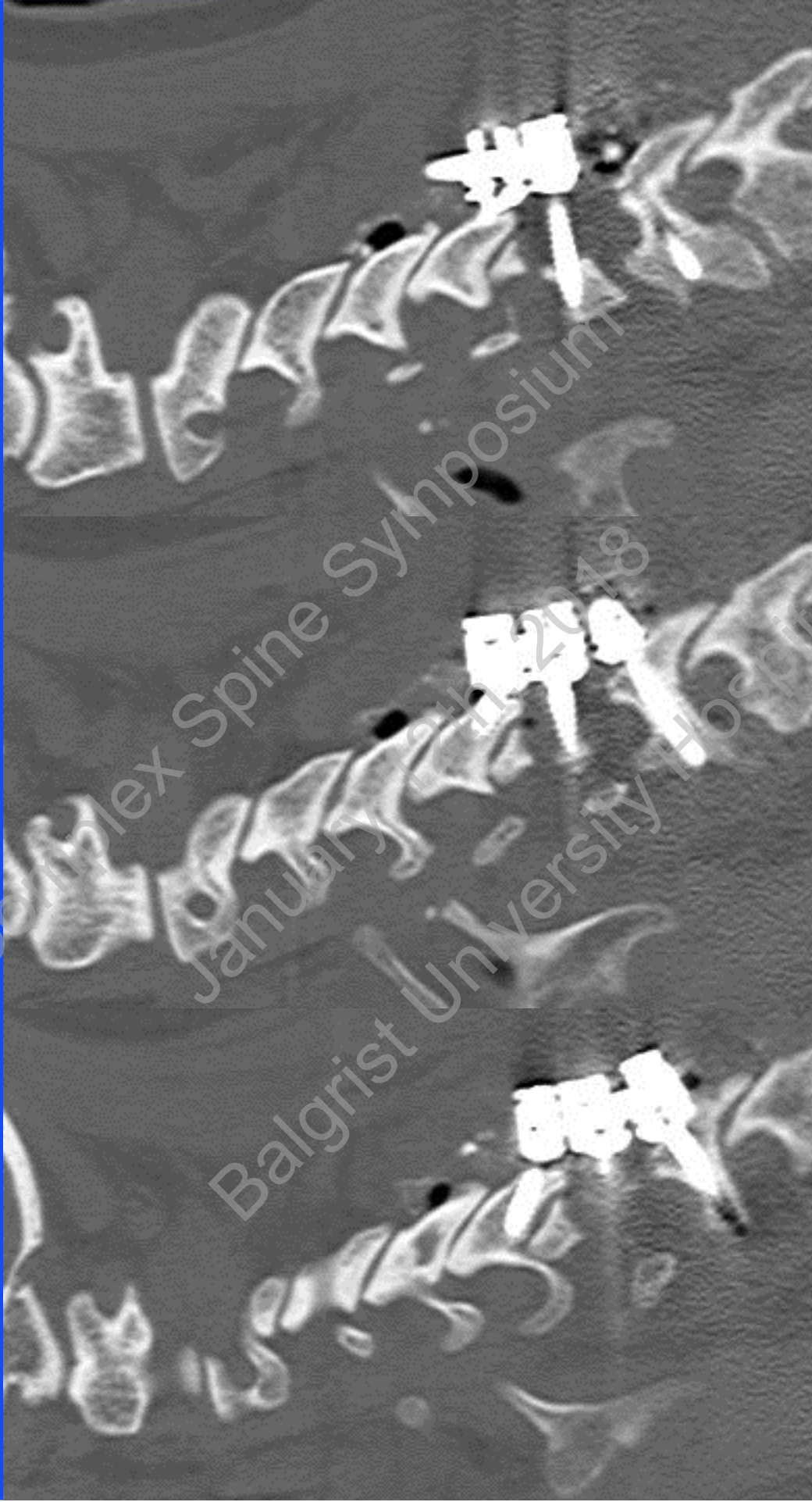Complex Spine Symposium  
January 12-14, 2018  
Balgrist University Hospital



Complex Spine Symposium  
January 12-14, 2018  
Balgrist University Hospital



Complex Spine Symposium  
January 12th, 2018  
Balgrist University Hospital



Complex Spine Symposium  
January 19th 2018  
Balgrist University Hospital