

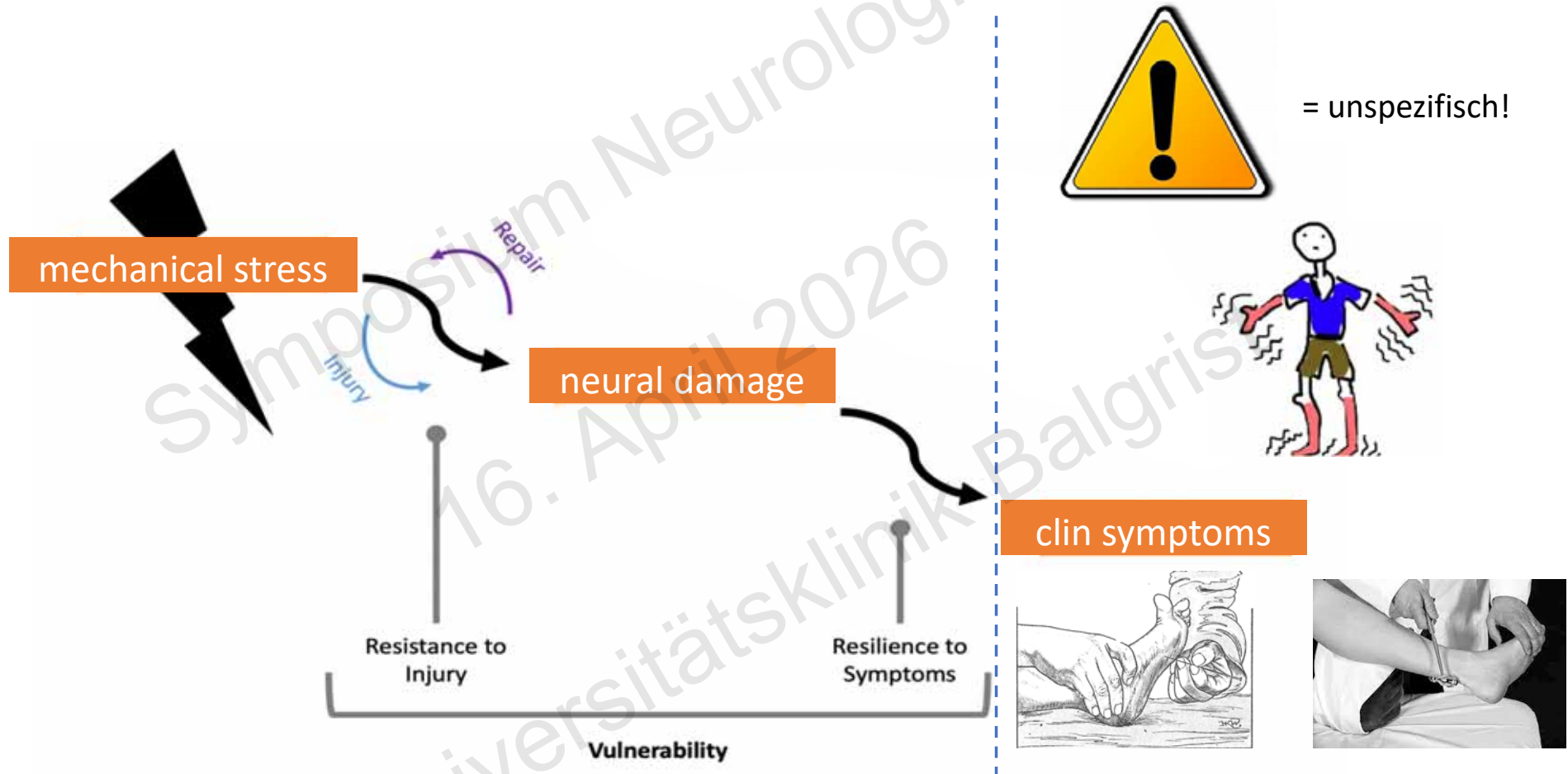
Wie erkenne ich die DCM?

Neurologische Differentialdiagnostik

PD Dr. med. Carl M. Zipser, M.A., FEBN
Zentrum für Paraplegie und
Abteilung für Neurologie/Neurophysiologie



Klinische Diagnostik



Epidemiologie, Risikofaktoren, Genetik

Häufigste nicht-traumatische Form von Rückenmarksschädigung

Inzidenz > 4-8/100'000 (eher höher...)

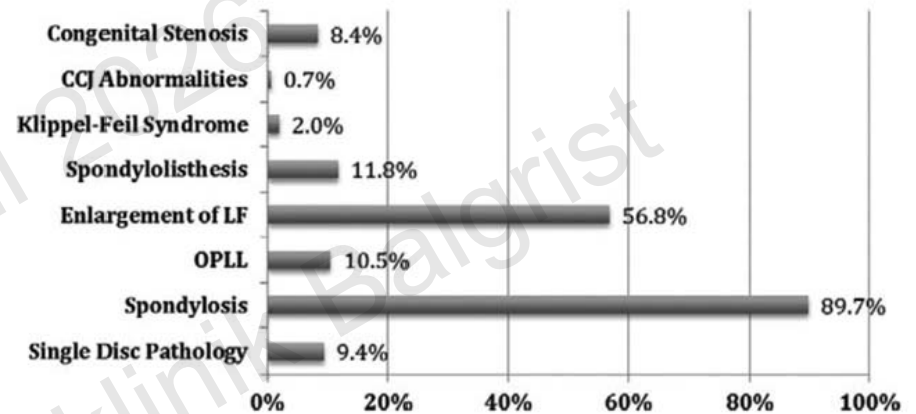
Mittleres Alter bei Erkrankung 60 Jahre (M:F, 3:2)

Am häufigsten altersbedingte Spondylose («degenerativ»)

Selten prädisponierende Erkrankungen (z.B. Klippel-Feil Syndrom)

Erhöhtes relatives Risiko für °1 Familienmitglieder (5-fach)

(A) **Prevalence and Spectrum of Pathologies in the Cervical Spine on MRI**



Leitsymptome der DCM – unspezifisch, individuell variabel



Narrative Review

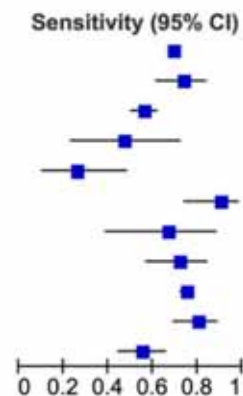
The Frequency of Symptoms in Patients With a Diagnosis of Degenerative Cervical Myelopathy: Results of a Scoping Review

Global Spine Journal
2023, Vol. 0(0) 1–27
© The Author(s) 2023
Article reuse guidelines:
sagepub.com/journals-permissions
DOI: 10.1177/21925682231210468
journals.sagepub.com/home/gsj



Hand Clumsiness.

Study	TP	FP	FN	TN	Sensitivity (95% CI)
*Weighted Average	942	0	422	0	0.69 [0.67, 0.72]
Chatley 2009	47	0	17	0	0.73 [0.61, 0.84]
Chibbaro 2009	150	0	118	0	0.56 [0.50, 0.62]
Choi and Kim 2018	8	0	9	0	0.47 [0.23, 0.72]
Cui 2015	6	0	17	0	0.26 [0.10, 0.48]
Hossam 2013	27	0	3	0	0.90 [0.73, 0.98]
Hou 2020	10	0	5	0	0.67 [0.38, 0.88]
Lo 2007	33	0	13	0	0.72 [0.57, 0.84]
Tetreault 2015	556	0	186	0	0.75 [0.72, 0.78]
Thakar 2009	56	0	14	0	0.80 [0.69, 0.89]
Wei 2019	49	0	40	0	0.55 [0.44, 0.66]



DCM- Symptome: Was ist häufig, was kommt zuerst, seltene Symptome?

Internet- Survey bei DCM-
Patienten (N= 171)



Symptome häufig *kombiniert*
auch bei Erstmanifestation
(55%)

Sehr frühes Symptom:
Nackenschmerz



Sehr häufiges Symptom:
Gangstörung (84%)

«Seltene Symptome» (40%!):
Kopfschmerz, Respiratorische
Dysfunktion,...

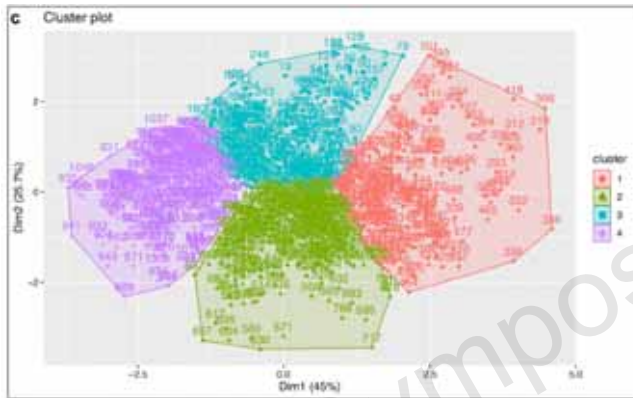
RESEARCH ARTICLE





Targeting earlier diagnosis: What symptoms come first in Degenerative Cervical Myelopathy?

Colin F. Munro¹, Ratko Yurac^{2,3}, Zipser Carl Moritz⁴, Michael G. Fehlings^{5,6,7},
Ricardo Rodrigues-Pinto^{8,9}, James Milligan¹⁰, Konstantinos Margetis^{11,12}, Mark R.
N. Kotter^{1,13}, Benjamin M. Davies^{1,13,14}*



Phänotypisierung – Subtypen DCM?



-  Phenotype 1: Severe multimodal Impairment
-  Phenotype 2: Minimal Impairment
-  Phenotype 3: Motor - Dominant
-  Phenotype 4: Pain - Dominant

Machine learning-based cluster analysis identifies four unique phenotypes of patients with degenerative cervical myelopathy with distinct clinical profiles and long-term functional and neurological outcomes

Karlo M. Pedro,^{a,b} Mohammed Ali Akil,^{a,b} Nader Hejrati,^c Ayesha I. Qudusi,^{a,b} Anoushka Singh,^{d,e} and Michael G. Fehlings^{a,b,d,e*}

^aDivision of Neurosurgery & Spine Program, Department of Surgery, University of Toronto, Toronto, ON, Canada

^bInstitute of Medical Science, University of Toronto, Toronto, ON, Canada

^cDepartment of Neurosurgery & Spine Center of Eastern Switzerland, Kantonsspital St. Gallen & Medical School of St. Gallen, Rorschacherstrasse 95, 9007 St. Gallen, Switzerland

^dDivision of Genetics & Development, Krembil Brain Institute, University Health Network, Toronto, ON, Canada

^eDivision of Neurosurgery, Krembil Neuroscience Centre, Toronto Western Hospital, University Health Network, Toronto, ON, Canada

Summary

Background Degenerative cervical myelopathy (DCM), the predominant cause of spinal cord dysfunction among



eBioMedicine
2024;106: 105226

mJOA - diagnostischer Standard mit Limitationen



UPPER LIMB MOTOR	LOWER LIMB MOTOR	UPPER LIMB SENSORY	SPHINCTER
I am unable to move my hands at all 0	I am paralysed and unable to move or feel my legs 0	I am unable to feel my hands 0	I cannot control when I pass urine 0
I can move my hands a little, but I am unable to feed myself 1	I can feel my legs but I am unable to move them at all 1	I have pain or severe loss of feeling (including numbness, tingling) in my hands 1	I have marked difficulty passing urine 1
I can feed myself, but I am unable to button my shirt 2	I can move my legs but I cannot walk 2	I have mild loss of feeling (including numbness, tingling) in my hands 2	I have mild difficulty passing urine 2
I can button up my shirt, but I find it very difficult and it takes a long time 3	I can walk but I require a walking aid 3	I have no loss of feeling in my hands 3	I have no difficulty passing urine 3
I can button my shirt with only slight difficulty 4	I can walk up and down stairs, but I have to hold the handrail 4		
My hands work normally 5	I am a little unsteady on my feet, but I can walk up and down stairs without holding the handrail 5		
	I am a little unsteady, but I can walk unaided 6		
	My legs are unaffected 7		

0-18 Punkte gesamt

Mild: 15-17

Moderat: 12-14

Schwer: <12

- Symptomhierarchie?**
- Symptomgewichtung?**
- Unpräzise Schmerz?**
- Sensitivität milde DCM?**

Konsens: Messinstrumente DCM

- mJOA
- The SF-36 Life Impact Scale (Version 2)
- The Neck Disability Index (NDI)
- The Spinal Adverse Events Severity System

GUIDELINES AND GUIDANCE

A minimum data set—Core outcome set, core data elements, and core measurement set—For degenerative cervical myelopathy research (AO Spine RECODE DCM): A consensus study

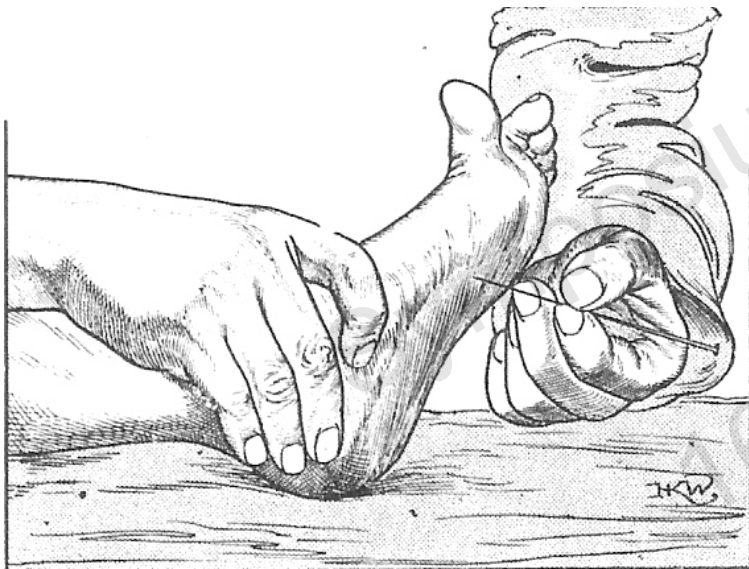
Benjamin M. Davies^{1,2*}, Xiaoyu Yang¹, Danyal Z. Khan^{3,4}, Oliver D. Mowforth^{1,2}, Alvaro Y. Touzet⁵, Aria Nouri^{1,6}, James S. Harrop⁷, Bizhan Aarabi⁸, Vafa Rahimi-Movaghar⁹, Shekar N. Kurpad¹⁰, James D. Guest¹¹, Lindsay Tetreault¹², Brian K. Kwon¹³, Timothy F. Boerger¹⁰, Ricardo Rodrigues-Pinto^{14,15}, Julio C. Furlan¹⁶, Robert Chen¹⁷, Carl M. Zipser¹⁸, Armin Curt¹⁸, James Milligan¹⁹, Sukhivinder Kalsi-Rayn²⁰, Ellen Sarewitz², Iwan Sadler², Tammy Blizzard², Caroline Treanor², David Anderson²¹, Nader Fallah²², Olesja Hazenbiller²³, Carla Salzman², Zachary Zimmerman², Anne M. Wandycz², Shirley Widdop², Margaret Reeves², Rye Raine², Sukvinder K. Ryan¹⁶, Ailish Malone²⁴, Ali Gharooni¹, Jefferson R. Wilson²⁵, Allan R. Martin²⁶, Michael G. Fehlings²⁵, Angus G. K. McNair²⁷, Mark R. N. Kotter^{1,2}, on behalf of the AO SPINE RECODE-DCM Steering Committee and AO Spine RECODE DCM Community



Klinische Zeichen der DCM – geringe Sensitivität für milde DCM


The value of Clinical signs in the diagnosis of Degenerative Cervical Myelopathy - A Systematic review and Meta-analysis

Global Spine Journal
2023, Vol. 0(0) 1–26
© The Author(s) 2023
Article reuse guidelines:
sagepub.com/journals-permissions
DOI: 10.1177/21925682231209869
journals.sagepub.com/home/gsj
Sage



Babinski's Sign

Study	TP	FP	FN	TN	Sensitivity (95% CI)	Specificity (95% CI)
*Weighted Average	30	2	151	237	0.17 [0.11, 0.23]	0.99 [0.97, 1.00]
Chaiyanmongkol 2017	13	0	23	14	0.36 [0.21, 0.54]	1.00 [0.77, 1.00]
Cook 2009	6	2	12	25	0.33 [0.13, 0.59]	0.93 [0.76, 0.99]
Cook 2010	6	0	82	161	0.07 [0.03, 0.14]	1.00 [0.98, 1.00]
Rhee 2009	5	0	34	37	0.13 [0.04, 0.27]	1.00 [0.91, 1.00]



Balgrist Kohorte – PRO-CSM

- N= 138 Patienten mit DCM
- (Nur) 35% mit T2w Läsionen im MRI
- *Symptome*
 - Sensible Defizite 65%
 - Feinmotorikstörung 35%
 - Gangstörung 35%
- mJOA > 14 70%

ORIGINAL ARTICLE

European Journal
of Neurology

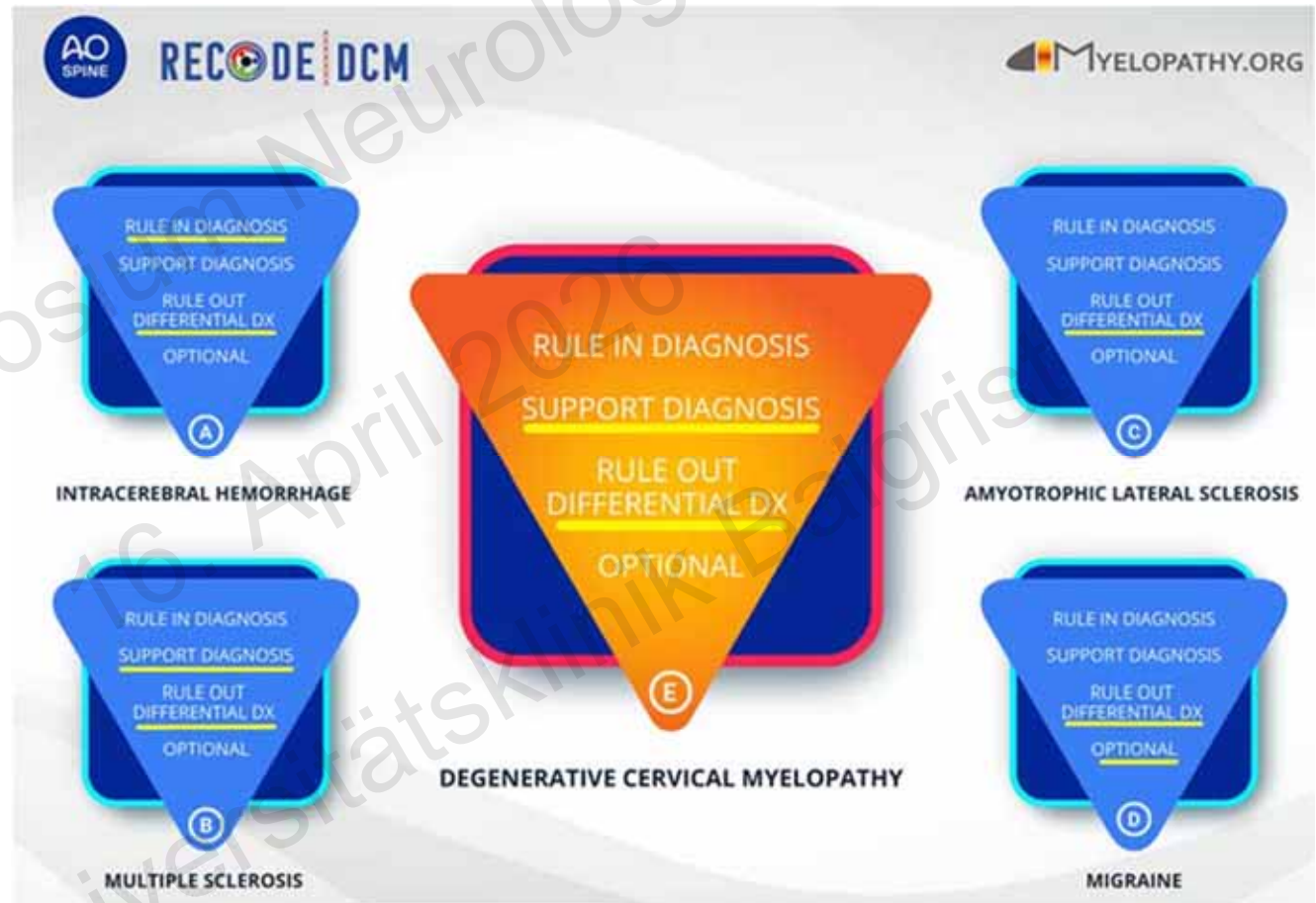Contact heat evoked potentials reveal distinct patterns of spinal cord impairment in degenerative cervical myelopathy beyond MRI lesions

Paulina Simone Scheuren^{1,2,3,4} | Markus Hupp¹ | Nikolai Pfender¹ |
Maryam Seif^{1,5} | Carl Moritz Zipser¹ | Florian Wanivenhaus⁶ | José Miguel Spirig⁶ |
Michael Betz⁶ | Patrick Freund¹ | Martin Schubert¹ | Mazda Farshad⁶ |
Armin Curt^{1,6} | Michèle Hubli¹ | Jan Rosner^{1,2,7}

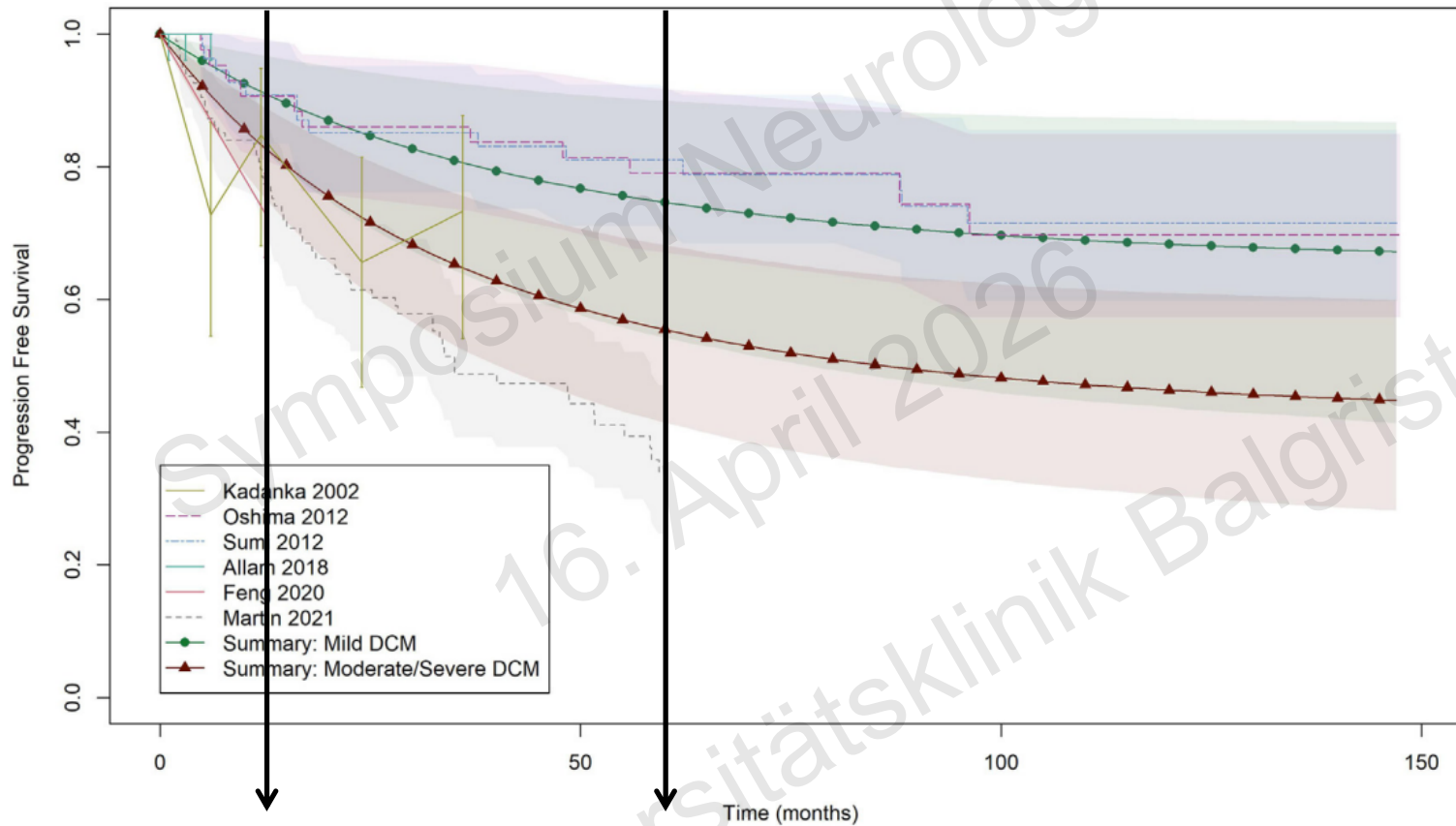


Rolle Bildgebung in der Diagnosestellung der DCM

- Diagnose der DCM ist *keine* «Bildgebungsdiagnose»
- T2w Läsionen fakultativ
- *Rolle des MRI*
 - Bildgebendes Korrelat DCM
 - Ausschluss von DD



Natürlicher Langzeit- Verlauf DCM – eine Meta-Analyse

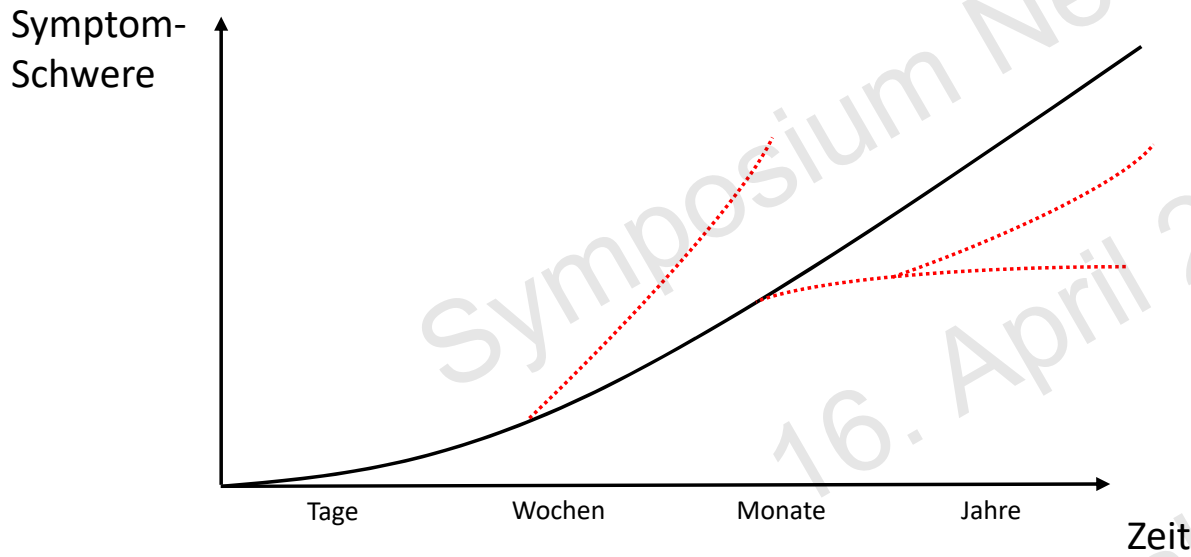


1. Jahr: >10% aller
Patienten Befundprogress

3. Jahr: >20% aller
Patienten Befundprogress

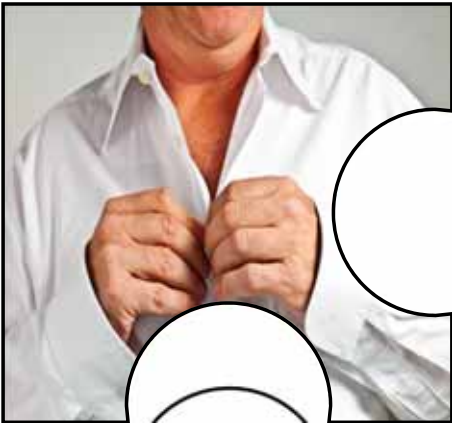


Individueller klinischer Verlauf – Active Surveillance!



Variable Verläufe
i.d.R. schleichend progredient
Subakuter Verschlechterung
Plateau-Progression Wechsel

Neurologische Differentialdiagnosen



CTS?

**Radikulopathie?
Nicht-myelopathische
Spinalkanalstenose?**



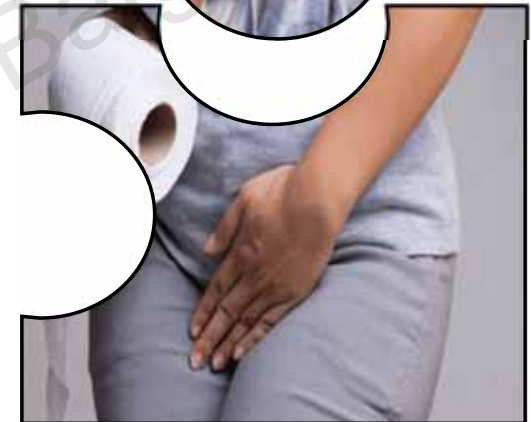ALS?

**Multiple Sklerose?
Spinale Tumore?
Spinale Ischämie?
Mikroangiopathie?**



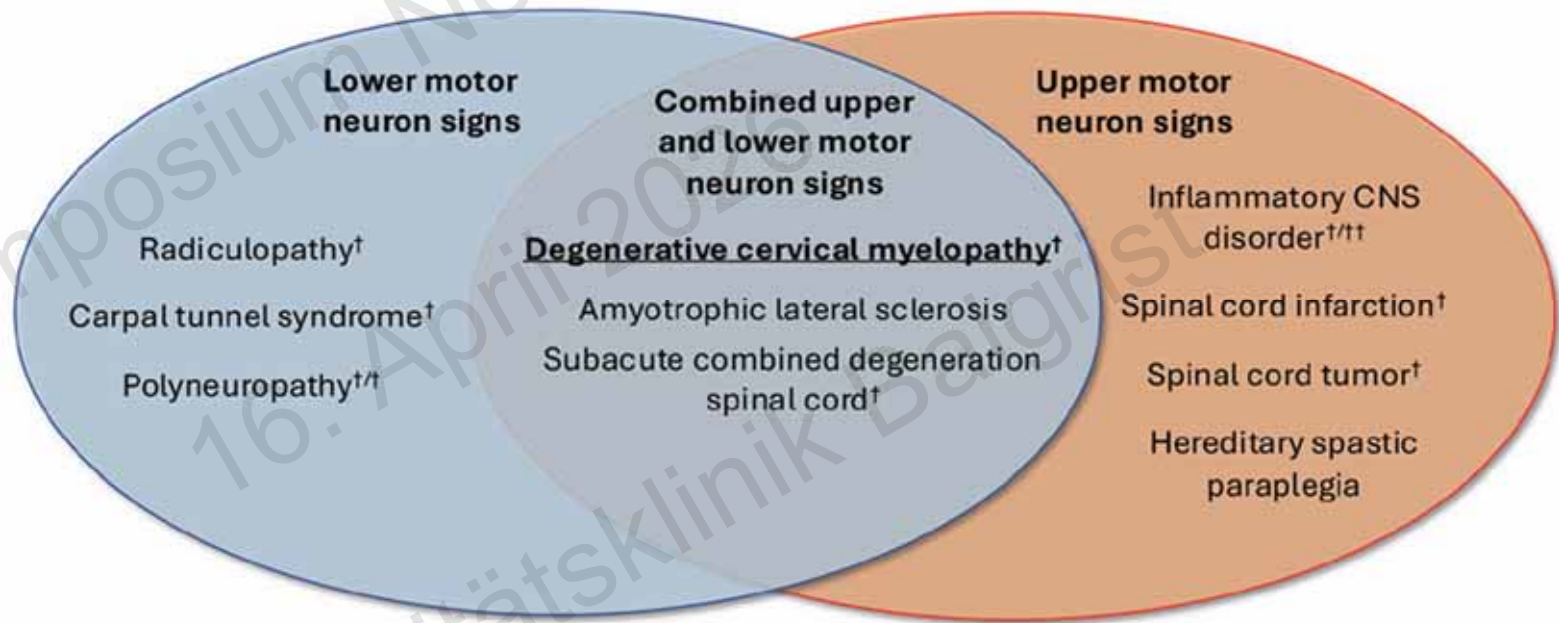
PNP?

Vitamin B12- Mangel?



Systematische DD der DCM

- *UMN-Zeichen*: unterhalb der Kompressionshöhe
- *LMN-Zeichen*: auf Höhe der Kompression



Symposium Neurologie
16. April 2026

Fall 1

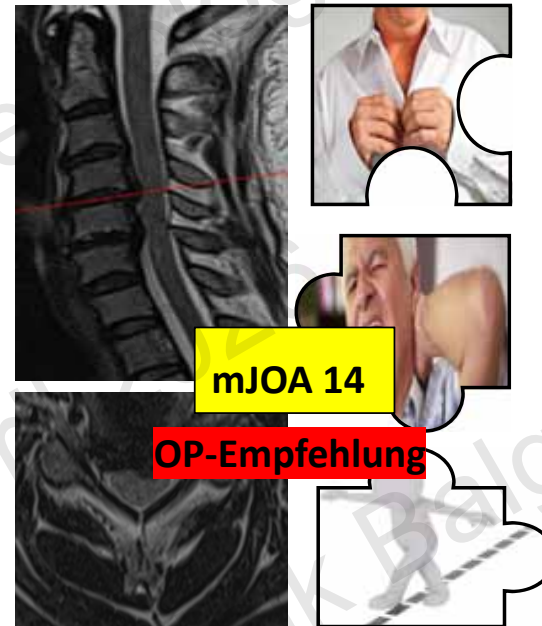
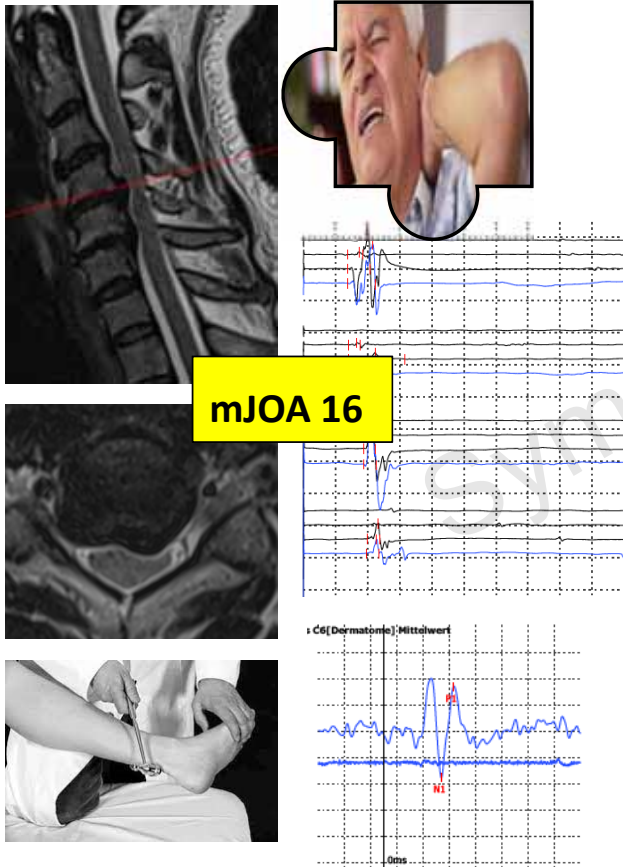
Universitätsklinik Balgrist



Universität
Zürich ^{UZH}

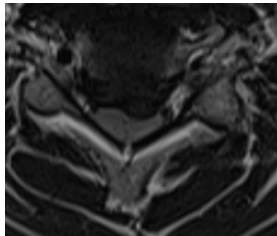
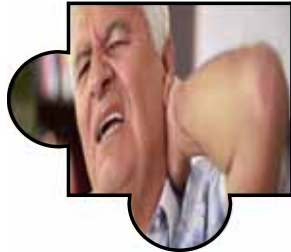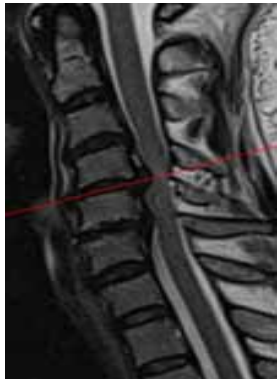Balgrist
Universitätsklinik
Universitätsklinik

Patientenvignette 1: Erstvorstellung und 3-Monats-Verlauf



BL	ZML <i>F-Wellen</i>	rechts: 14.6 ms;	links: 16.4 ms	(< 15,4 ms)
	ZML <i>lumb. Stim.</i>	rechts: 14.6 ms;	links: 17.1 ms	(< 18,4 ms)
FU	ZML <i>F-Wellen</i>	rechts: 16.8 ms;	links: 16.9 ms	(< 15,4 ms)
	ZML <i>lumb. Stim.</i>	rechts: 20.8 ms;	links: 20.0 ms	(< 18,4 ms)

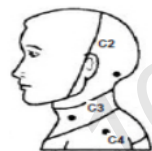
Patientenvignette 1: Wiedervorstellung und post-OP Kontrolle



mJOA 12

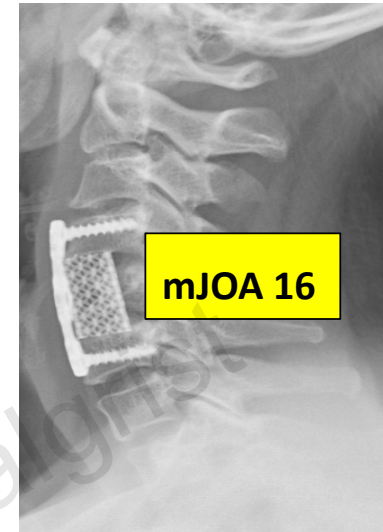
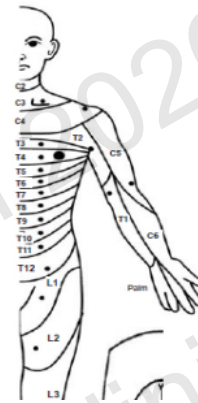
MOTOR Key Muscles

	R	L	
C5	4	4	Elbow flexors
C6	4	4	Wrist extensors
C7	4	4	Elbow extensors
C8	4	4	Finger flexors
T1	5	4	Finger abductors



SENSORY Key Sensory Points

	light touch		Pin Prick	
	R	L	R	L
C2	2	2	2	2
C3	2	2	2	2
C4	2	2	2	2
C5	2	2	2	2
C6	2	1	2	1
C7	2	1	2	1
C8	2	1	2	1
T1	2	2	2	2
T2	2	2	2	2
T3	2	2	2	2
T4	2	2	2	2
T5	2	2	2	2
T6	2	2	2	2
T7				
T8				

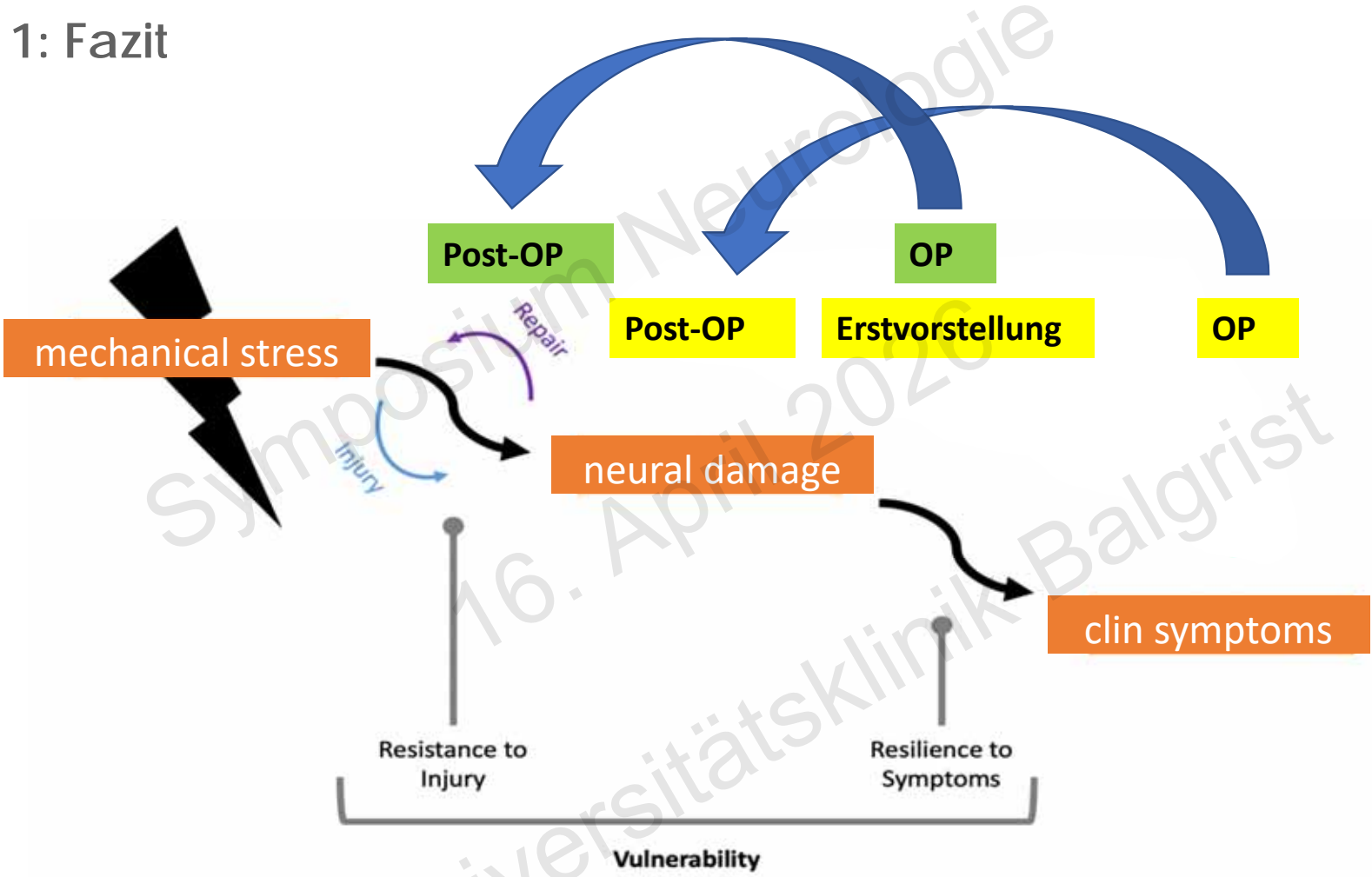


mJOA 16

Ventrale Korpektomie C5, WK Ersatz mit Cage, Ventrale Verplattung C4-6 (fecit PD Dr. Spirig)



Fall 1: Fazit



Symposium Neurologie
16. April 2026

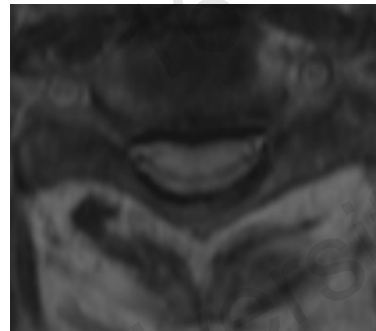
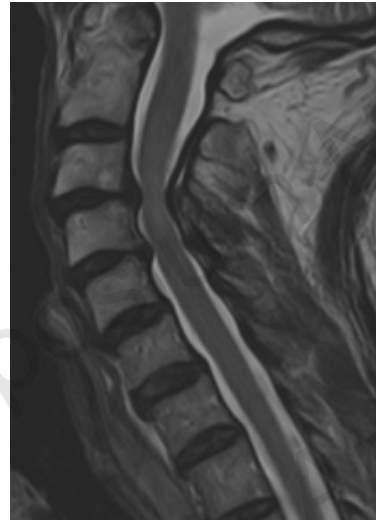
Fall 2

Universitätsklinik Balgrist

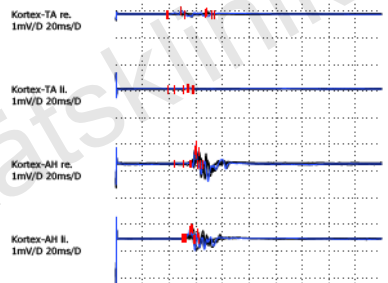
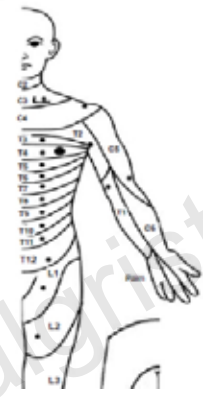
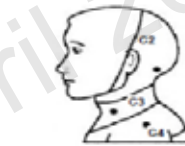

Patientenvignette 2: DCM und sekundär traumatische Tetraspastik

F, 67
 Seit 6 Monaten Symptome,
 Seit Sturz Verschlechterung



MOTOR Key Muscles		SENSORY Key Sensory Points			
		light touch		Pin Prick	
R	L	R	L	R	L
C5	5	5	5	5	5
C6	4	4	4	4	4
C7	4	4	4	0	0
C8	3	3	3	1	1
T1	4	4	4	1	1
T2	1	1	1	1	1
T3	2	2	2	2	2
T4	2	2	2	2	2
T5	2	2	2	2	2
T6	2	2	2	2	2
T7	2	2	2	2	2
TR	2	2	2	2	2



DCM + Trauma
Path. Neurophysiologie
mJOA 10
Notfall-OP

Patientenvignette 2: Postoperative Verlaufskontrolle

Laminektomie C3/4 (fecit PD Dr. Betz)

BL	ZML <i>F-Wellen</i>	rechts: 23.0 ms;	links: 23.6 ms	(< 15,4 ms)
	ZML <i>lumb. Stim.</i>	rechts: 29.0 ms;	links: - ms	(< 18,4 ms)
FU	ZML <i>lumb. Stim.</i>	rechts: 26.6 ms;	links: 25.4 ms	(< 18,4 ms)

~~You can't~~ make a difference.

TIME IS SPINE

mJOA 18

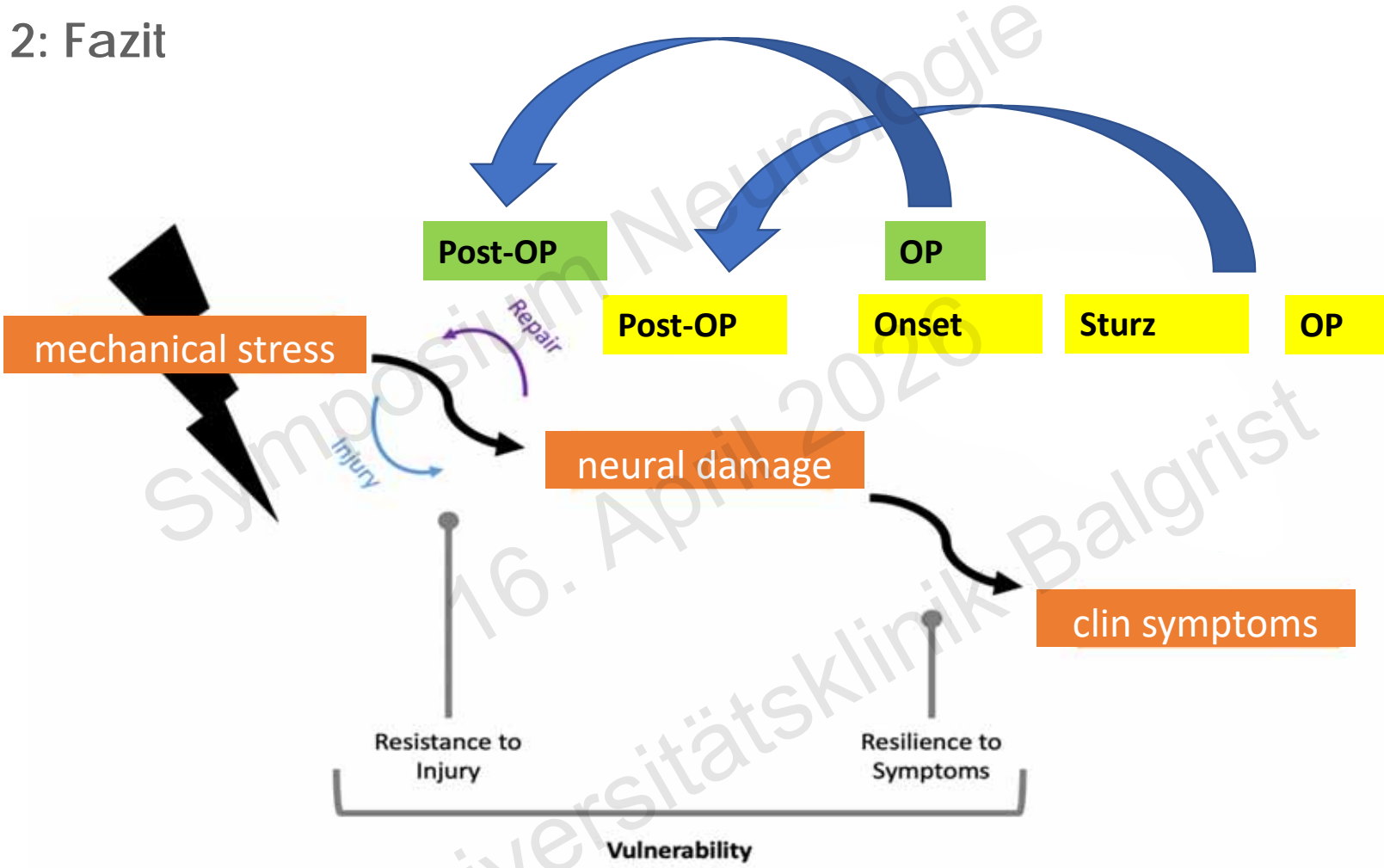
Residuell Spastik,

Nicht störend

MEP gebessert



Fall 2: Fazit



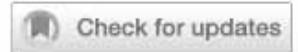Natürlicher Verlauf DCM: Being ahead of DCM

www.nature.com/sc






PERSPECTIVE

OPEN



Increasing awareness of degenerative cervical myelopathy: a preventative cause of non-traumatic spinal cord injury

Carl M. Zipser¹  , Konstantinos Margetis², Karlo M. Pedro³, Armin Curt¹, Michael Fehlings⁴ , Iwan Sadler⁵, Lindsay Tetreault⁶, Benjamin M. Davies⁷, On behalf of the AO Spine RECODE DCM Steering Committee* and Members of the Diagnostic Criteria Working Group*

© The Author(s) 2021



Universität
Zürich^{UZH}

Balgrist
Universitätsklinik

Ausblick: Entwicklung Diagnosekriterien



Original Research

We Choose to Call it 'Degenerative Cervical Myelopathy': Findings of AO Spine RECODE-DCM, an International and Multi-Stakeholder Partnership to Agree a Standard Unifying Term and Definition for a Disease

Global Spine Journal
2022, Vol. 0(0) 1–10
© The Author(s) 2022
Article reuse guidelines:
sagepub.com/journals-permissions
DOI: 10.1177/21925682221111780
journals.sagepub.com/home/gsj
SAGE



Benjamin M. Davies, MRCS, BSc, MPhil^{1,2}, Danyal Z Khan, MRCS^{3,4}, Kara Barzangi, BA¹, Ahmad Ali, MRCS⁵, Oliver D. Mowforth, BA, MBBChir, MRCS^{1,2}, Aria Nouri, MD, MSc⁶, James S. Harrop, MD, MSHQS, FACS⁷, Bizhan Aarabi, MD⁸, Vafa Rahimi-Movaghar, MD⁹, Shekar N Kurpad, MD, PhD¹⁰, James D. Guest, MD, PhD, FACS¹¹, Lindsay Tetreault, MD, PhD¹², Brian K. Kwon, MD, PhD, FRCSC¹³, Timothy F Boerger, PhD, ATC¹⁰, Ricardo Rodrigues-Pinto, MD, PhD, FEBOT^{14,15}, Julio C. Furlan, MD, LLB, MBA, PhD, MSc, FRCPC¹⁶, Robert Chen, MA, MBBChir¹⁷, Carl Moritz Zipser, MD, FEBN¹⁸, Armin Curt, MD¹⁸, James Milligan, MD¹⁹, Sukhivinder Kalsi-Rayn, BSc PT, MSc, PhD²⁰, Ellen Sarewitz, MA², Iwan Sadler, MD², Shirley Widdop, BSc², Michael G. Fehlings, MD, PhD, FRCSC, FACS²¹, and Mark R.N. Kotter, MD, MPhil, PhD^{1,2}

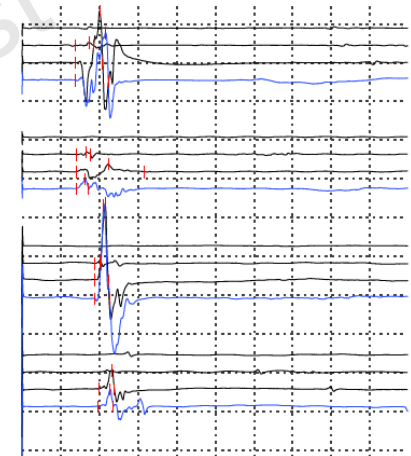
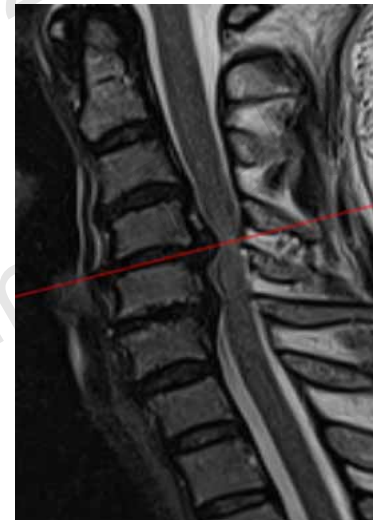International + Interprofessional Survey ✓

Shortlist ✓

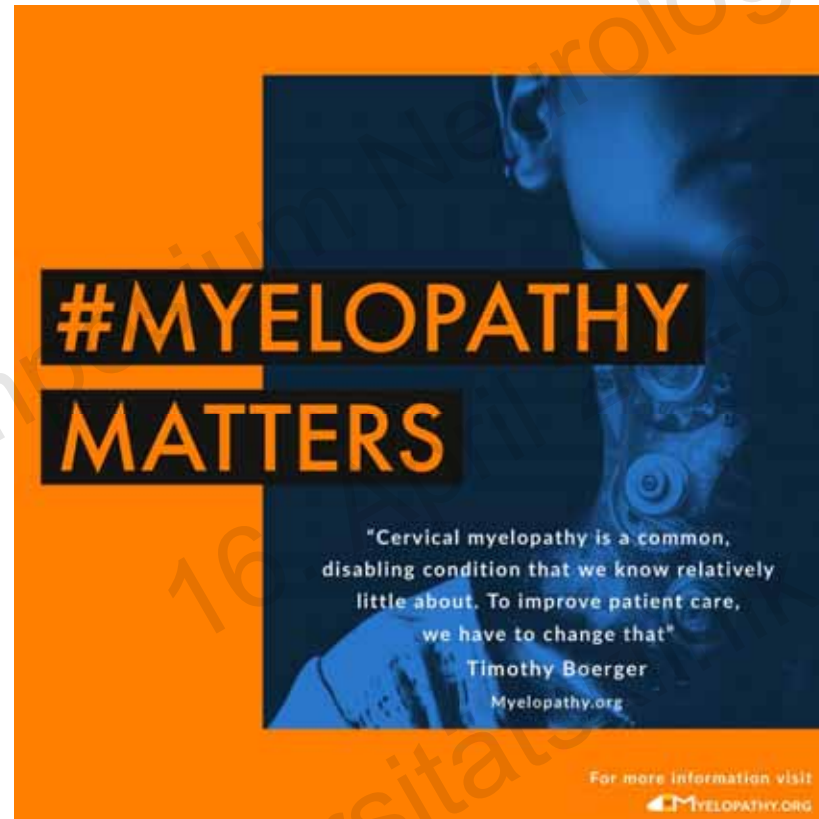
Next step: diagnostic criteria! Ende 2026

Zusammenfassung

- Die DCM ist eine häufige Erkrankung
- Die klinischen Symptome sind unspezifisch, immer an DCM denken
- Zusatzdiagnostik erforderlich zur frühen Diagnosestellung und Neurologischen Differentialdiagnose (Ruling-in und Ruling-out!)
- «Being ahead of DCM», «Time is Spine», «Myelopathy matters»



Vielen Dank für die Aufmerksamkeit! Fragen- Diskussion.



Frage ans Publikum

Welchen Begriff benutzen sie für die chronisch zervikale Spinalkanalstenose mit Rückenmarkschaden?

- a) Cervikale Spondylotische Myelopathie (CSM)
- b) Degenerative Cervikale Myelopathie (DCM)

